

Case Report

SUCCESSFUL MANAGEMENT OF COMPOUND FRACTURE IN A BUFFALO USING FABRICATED POLY VINYL CHLORIDE SPLINT IN FIELD SETTINGS

***A.Velavan**

Veterinary University Peripheral Hospital, Madhavaram Milk Colony, Chennai-51

**Author for Correspondence*

ABSTRACT

A six year old female Murrah buffalo was brought with the complaint of hind limb fracture. Clinical examination revealed compound fracture of metatarsal bone with open wound on the medial aspect. The fracture was stabilized using fabricated PVC splint external coaptation. The daily dressing of wound was carried out using 5% povidone iodine through the window provided in the PVC splint. Inj. Streptopenicillin 5 gm was given i/m daily for 10 days. Animal started partial weight bearing on the fractured limb on day 40. On day 90, animal was bearing complete weight on the fractured limb. There was no complication reported thereafter.

Keywords: *Compound Fracture, Metatarsal Bone, Buffalo, Fabricated, PVC Splint*

INTRODUCTION

In farm animals, limb fractures are common and occur subsequent to trauma during handling or dystocia (Anderson and Jean, 2008). Limb fractures are classified depending on the anatomical location, presence of external wound, extend of bone damage and direction of fracture line. Among these types compound fracture is a challenging type to treat. In buffaloes repair of fractured long bones is not commonly reported due to their heavy body weight (Turner, 1984; Ayaz, 2000). Prognosis in adults is guarded and mainly limited by the weight of the animal and degree of the contamination of the wound (Mulon, 2010). So, this type of fracture management is not much explored. In this paper a modified method of utilizing PVC (Poly vinyl chloride) splint for the successful management of a compound fracture of metatarsal bone in a buffalo is described.

CASES

History and Clinical Signs

A six year old female buffalo weighing 450 kilograms was reported to Teaching Veterinary Clinical complex, Veterinary College and Research Institute, Orathanadu with the complaint of broken hind limb happened while jumping across feed manger. The animal was already treated by a local vet using Plaster of Paris for a week. Clinical examination of the animal revealed that it was a compound fracture of right metatarsal bone (Figure 1). The open wound was located on the medial aspect of metatarsal bone (Figure 2). Fractured bone fragment was visible through the wound site. Pus discharge was noticed at the fractured site.



Figure 1: Buffalo lying down with fractured hind limb before treatment

Case Report



Figure 2: Fractured hind limb (white arrow) indicates wound at the medial side of fractured area

RESULTS AND DISCUSSION

The wound at the medial site was dressed using 5% povidone iodine and Ringers lactate solution and bandaged. Cotton padding was provided from stifle to fetlock joint except at the wound area. The fracture was stabilized using fabricated PVC splint. Fabrication of PVC splint was done as per the following procedure. A 10 mm thickness, 4" diameter PVC pipe was cut at 75 cm length. Then PVC pipe was divided into two halves and 5 cm rectangular piece was removed from the medial side of the splint. This window provision was done for the daily dressing of the wound. Then the splint was heated at fire and fabricated according to the shape of the hind limb from stifle to hoof. The fabricated PVC splint is shown in figure (3). Over the cotton padding the fabricated PVC splint was applied. Fractured fragments were aligned anatomically and adhesive tape was applied over the fabricated PVC splint and bandaged. The bandage was covered with parceling tape to keep the bandage dry despite urine spillage. Daily wound dressing was carried out using 5% povidone iodine and bandaged for 40 days. Inj. Streptopenicillin 5 gm i/m was given for 10 days. Supplements like Inj. Vitamin AD₃E 10 ml i/m and Inj. phosphorus 10 ml i/m were administered weekly once for 4 weeks. Oral calcium 60 ml was advised for 40 days. Animal was kept under complete rest. On day 40, the wound healed completely (Fig 4). The animal started mild weight bearing from day 20. Partial weight bearing was observed on day 40. Complete weight bearing of the fractured limb was noticed on day 90. The fabricated PVC splint removed on day 90.

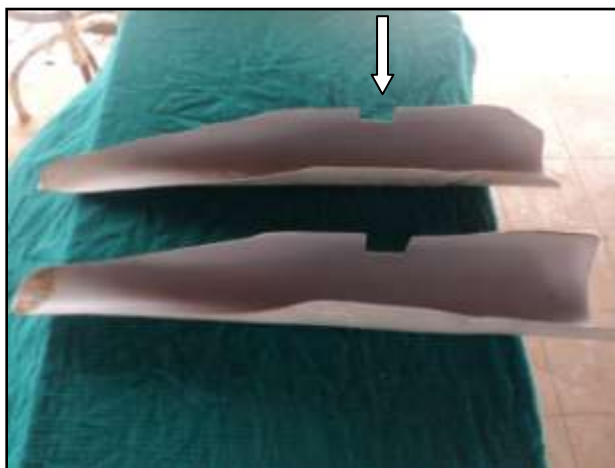


Figure 3: Fabricated PVC splint (white arrow indicates window provision for daily wound dressing)

Case Report

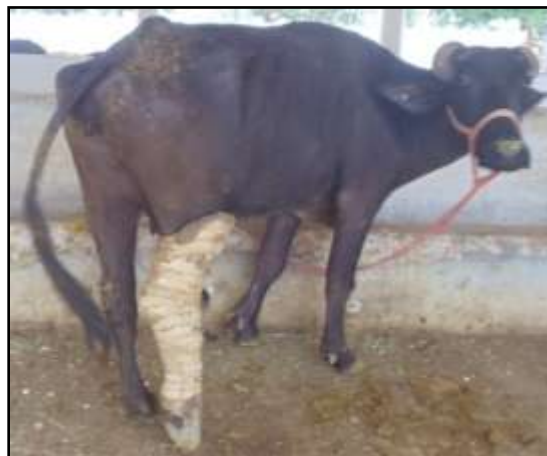

Figure 4: Status of the animal after 40 days of treatment with partial weight bearing

Compound fracture is one type of fracture wherein there is communication between the fracture site and outer skin wound. Due to limited amount of soft tissues covering over the metatarsal and metacarpal bones, these fractures are frequently converted into compound fractures resulting from the penetration of the bone within (Ayaz, 2000). Due to the lack of satisfactory immobilizing devices with open dressing facilities, the compound fractures usually do not respond to the treatment and develop such complications that amputation will only save the animal (Nayak and Samantara, 2010). Since, compound fracture needs daily dressing of the wound, external skeletal fixation is the right choice. Economic considerations and non-availability of orthopaedic implants for large animal at field level makes the compound fractures non-treatable. Dealing with the compound fracture will always remain a challenge to the clinician (Mulon, 2011). More over radiological assessment is almost impracticable at field level with no x-ray infrastructure facility.

Considering all these factors, we have fabricated the PVC splint with window provision for daily dressing of wound. Common antibiotics used in orthopaedic infection are penicillin, cephalosporin, fluoroquinolone and trimethoprim-sulpha as it has been established they reach tissue concentration above MIC in bones. The control of the infection is the main target to reach the ultimate goal of fracture healing (Mulon, 2010). In this present case *Streptococcus* organisms were identified in the wound and Inj. Streptopenicillin was used. Administration of antioxidant vitamins A, E and C could accelerate bone healing after long bone fixative surgery (Sandukji *et al.*, 2011). In this present case apart from calcium and phosphorus supplementation, administration of vitamins AD₃E would helped in the earlier bone healing. So, compound fracture in buffaloes could be successful if treated using the above protocols.

REFERENCES

- Anderson DE and St Jean G (2008).** Management of fractures in field settings. *Veterinary Clinics of North America Food Animal Practice* **24** 567-582.
- Ayaz MM (2000).** Successful repair of metacarpal fracture in a buffalo using a novel gadget. *Pakistan Veterinary Journal* **20** 49-50.
- Mulon PY (2011).** Management of open fractures in cattle. Available: [www.acvs.org/symposium/proceedings 2011/ data/papers/222/pdf](http://www.acvs.org/symposium/proceedings%202011/data/papers/222/pdf) 672-673.
- Nayak S and Samantara S (2010).** Management of open fracture and dislocation in bovines without amputation. Available: www.vetscan.co.in **5** 68.
- Sandukji A, Al-Sawaf H, Mohamadin A, Alrashidi Y and Sheweita SA (2011).** Oxidative stress and bone markers in plasma of patients with long-bone fixative surgery: role of antioxidants. *Human Experimental Toxicology* **30** 435-442.
- Turner AS (1984).** Large animal orthopaedics. In: *The Practice of Large Animal Surgery* edited by Jennings Jr. PB II (W.B. Saunders Co, Philadelphia) 816-821.