

Research Article

COMPARATIVE STUDY OF SERUM CAROTENOIDS FOLLOWING EXPERIMENTAL EIMERIAL CHALLENGE IN BROILERS

***S.S.R. Shojaei¹ and A. Anooshepur²**

¹Department of Pathobiology, Faculty of Veterinary Medicine, Islamic Azad University, Karaj Branch, Karaj-Iran

²Department of Veterinary Medicine, Faculty of Veterinary Medicine, Islamic Azad University, Karaj Branch, Karaj-Iran

**Author for Correspondence*

ABSTRACT

In present study 16 Arbor-acres and 16 Ross 308 one-day broiler cockerels were examined. On day 12, cockerels of group Arbor-Acres challenge (Ach) and Ross 308 challenge (Rch) were crop inoculated by 100 micro liter of a mixture sporulated oocysts of *Eimeria acervulina*, *Eimeria maxima*, *Eimeria necatrix* and *Eimeria tenella*. Blood samples of each group were collected on day 4, 5 and 6 post challenges. Serum carotenoids were measured by *n*-hexane method. T-test was performed and $p \leq 0.05$ was considered significant. There is no significant difference between Ach and Rch serum carotenoid levels at day 4. Ach serum carotenoid levels were significantly higher than Rch in day 5 and 6 post challenge. It seems that under similar conditions, intestinal mucosal damages of Arbor-Acres breed is less in experimental coccidiosis and its intestinal carotenoid absorption capacity remain much higher than Ross 308.

Keywords: Serum Carotenoid, Broiler, Eimerial Challenge, Experimental

INTRODUCTION

Coccidiosis is a disease of universal importance in poultry production that is caused by protozoan parasite, *Eimeria* (McDougald and Fitz-Coy, 2008). The parasite produces enteritis, malabsorption of sugars, amino acids, vitamins, fats, nutritional pigments and etc. due to disruption of integrity of the intestinal mucosa (Greif, 2000).

Carotenoids are the most numerous and wide spread group of pigments which are known as precursors of vitamin A. Animals are not able to synthesis these pigments, so they should absorb it from dietary ingredients. Carotenoid absorption can be divided into four stages: digestion on the food matrix, formation of lipid mix micelles, uptake of carotenoid into the intestinal mucosal cells and delivery to plasma via lymph system (Williams, 1998). Since the lymphatic system of the bird is not developed, carotenoids are probably delivered directly to the tissues by protomicrons (Surai, 2001). Carotenoid absorption is a very delicate and sensitive process and it is likely that an impairment of any of these stages will decrease carotenoid assimilation from the diet (Surai, 2001).

Since the coccidiosis damage intestinal mucosa, carotenoid absorption decreased. Increased mucosal thickness, decrease height of villus, increase crypts depth, increase mucosal cells metabolism, tissue edema, and increase intestinal passage led to decrease intestinal carotenoid absorption capacity.

Based on different studies, serum carotenoid measurement is used to evaluate coccidia positive poultry flocks. Since Arbor-acres and Ross 308 are two major broiler breeds in Iran, the main goal of this study is to compare serum carotenoid absorption of these breeds based on experimental coccidiosis.

MATERIALS AND METHODS

Rearing of the Birds

16 Arbor-acres and 16 Ross 308 one-day broiler cockerels were divided into 4 equal groups (each breed contains 2 groups of 8 birds). Each group placed in one cage and given *ad libitum* access to water and unmedicated feed based on NRC (1994) requirements. All chicks were reared in a controlled environment.

Research Article

The experiment was approved by the Committee on Animal Experimentation at Islamic Azad University, Karaj Branch, Karaj, Iran.

Parasite Preparation

Oocysts of local isolates of *Eimeria acervulina*, *Eimeria maxima*, *Eimeria necatrix* and *Eimeria tenella* maintained in the Parasitology Laboratory, Faculty of Veterinary Medicine, Islamic Azad University, Karaj Branch was used. Oocysts were processed for sporulation in 2.5% potassium dichromate solution (Riley, 1976). Sporulated oocysts were given two washes with phosphate buffered saline (PBS; PH7.2), and stored in PBS at 4 degree of centigrade for further use (Mansoori, 2009).

On day 12, cockerels of group Ach (Arbor-Acers challenge) and Rch (Ross 308 challenge) were crop inoculated by 100 micro liter of a mixture of 1×10^4 *Eimeria acervulina*, 2×10^4 *Eimeria maxima*, 1.25×10^4 *Eimeria tenella*, 0.75×10^4 *Eimeria necatrix* sporulated oocysts.

Sampling

Blood samples of each group were collected on day 4, 5 and 6 post challenges. After clotting of samples, they were centrifuged for 15 min at 3000 RPM for serum separation. Serum samples were frozen in -20 degree of centigrade in dark package till further examinations.

1 ml of serum placed in a centrifuge tube and 1 ml of absolute ethanol was added for deproteinization. After vortexing for 0.5 min, 3 ml of *n*-hexane was added and the mixture was vortexed for 1 min. The samples were centrifuged for 10 min at 2000 RPM to aid separation of phases. The upper hexane layer was quantitatively transferred for spectrophotometry (Tzouganaki, 2002).

Optical density of each sample was measured by spectrophotometer, set at 453nm. Serum carotenoid concentration ($\mu\text{g/dl}$) was calculated based on formula 1.

Formula 1: Calculation of serum carotenoid concentration (Shojaei, 2004)

$$\text{Serum carotenoid concentration } (\mu\text{g/dl}) = \frac{\text{Optical density at 453 nm}}{0.00258}$$

Statistical Analysis

Data was analyzed using the statistics software package SPSS version 16.0 (Statistical Package for the Social Science, SPSS Inc., Chicago, 2008). The t-test was performed to compare serum carotenoid levels of challenge groups with control groups and serum caroteind levels of each breed with another; $p \leq 0.05$ was considered significant.

RESULTS

Ross 308 and Arbor-Acres challenged groups (Ach and Rch) had significantly lower serum carotenoid concentrations than control groups (Ac and Rc) respectively. There is no significant deference between Ach and Rch serum carotenoid levels at day 4. Ach serum carotenoid levels were significantly higher than Rch in day 5 and 6 post challenge.

Table 1: Mean serum carotenoid concentration ($\mu\text{g/dl}$) after oocystal challenge [Arbor-Acers challenge (Ach), Arbor-Acres control (Ac), Ross 308 challenge (Rch) and Ross 308 control (Rc)]

Group	Day 4 post challenge		Day 5 post challenge		Day 6 post challenge	
	Mean c.	Std. Deviation	Mean c.	Std. Deviation	Mean c.	Std. Deviation
Ach	47	4.0825	39	1.8257	40	1.8257
Ac	62	1.8257	63	2.4495	65	1.8257
Rch	43	3.266	27	2.582	26	2.4495
Rc	66	1.8257	68	1.8257	71	1.8257

Research Article

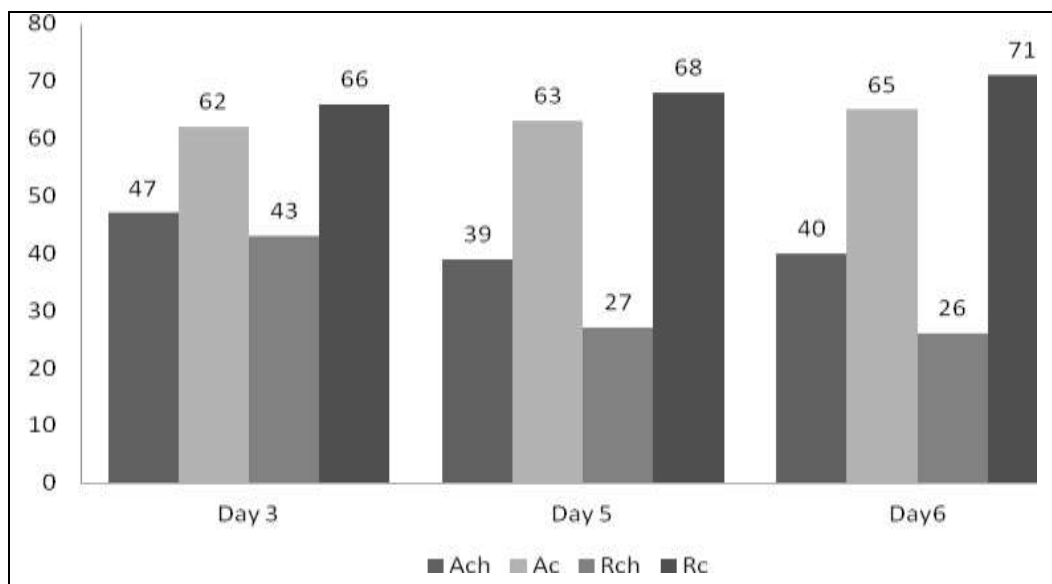


Figure 1: Mean serum carotenoid concentration on days post challenge [Arbor-Acers challenge (Ach), Arbor-Acers control (Ac), Ross 308 challenge (Rch) and Ross 308 control (Rc)]

DISCUSSION

Poultry coccidiosis is considered as one the important causative agents of malabsorption syndrome that directly decrease different serum biochemical indexes such as albumin, total protein and carotenoids. The impact of reduction of serum carotenoid concentration depends on breed, sex, feeding quality, *Eimeria* species, intensity and severity of infection and immune status of chickens (Allen, 1986, Matthews, 2000, Allen, 1987). A reduction in absorption capacity of intestine might be due to an increase in rate of replacement and turnover of intestinal epithelial cells, an elevation of mucosal cell metabolism, a decrease in infected area pH and an alteration in mechanism responsible for transport of nutrient across intestinal wall particularly Na^+ -depend active transport system in duodenum and jejunum (Fernando, 1973).

In addition to destroy enterocytes, *Eimeria* infections may disrupt mucosal capillaries which are led to bleeding and reduction in serum carotenoid concentration (Ruff, 1975).

Conway *et al.*, (1993) found that after coccidial challenge with *Eimeria acervulina*, *Eimeria maxima* and *Eimeria tenella*, serum carotenoid concentration significantly decreased. Shojaei (2004) concluded, serum carotenoid concentrations following coccidial vaccination and *Eimeria* challenge was significantly decrease in challenged group without vaccination. Shojadost *et al.*, 2006 studied *Eimeria* pathogenicity indexes and found similar findings on serum carotenoids concentrations. Ruff *et al.*, (1984) investigated intestinal absorption following challenge of immune chicks with *Eimeria acervulina*. They found that significant malabsorption was seen in unimmunized chicks. Allen (1992) demonstrated reduction of serum carotenoid concentrations as an intestinal damage index post coccidial challenge. The results was shown that treated group by virginiamycin had significantly higher carotenoid concentrations. Augustin *et al.*, (1983) challenged young turkeys with *Eimeria meleagritidis* and *Eimeria Adenoides* and concluded serum carotenoid was decrease in challenge group. Ruff *et al.*, (1975) suggested that the levels of plasma carotenoids were markedly reduced in broiler cockerels infected with *Eimeria acervulina* or *Eimeria tenella*. The mechanism of this depigmentation differed between two species, being primarily associated with interference of absorption of carotenoids from intestinal lumen with *Eimeria acervulina* infection and with leakage through the damaged wall of cecum with *Eimeria tenella* infection. In present study serum carotenoid concentrations of both Ach and Rch groups were significantly reduced but reduction was much more in Rch group. Based on analysis, Rch carotenoid concentrations were lower than Ach at day 3, 5 and 6 but these differences were statistically significant only at day 5 and 6. Rch serum carotenoid at 3, 5 and 6 days post challenge in comparison with Rc was reduced 23, 41 and 45 $\mu\text{g/dl}$, respectively but

Research Article

Ach in comparison with Ac had reduction of 15, 24 and 25 µg/dl at those days. These facts showed lower intestinal carotenoid malabsorption in Arbor-acres breed in comparison with Ross 308 breed.

In conclusion, it seems that under similar conditions, intestinal mucosal damages of Arbor-Acres breed is less in experimental coccidiosis and its intestinal carotenoid absorption capacity remain much higher than Ross 308. Further studies should be applied on lesion scoring, intestinal histomorphometry and performance indexes.

REFERENCES

- Allen PC (1986).** Biochemical change in intestinal mucosa associated with coccidiosis. *Georgia Coccidiosis Conference, Athens, Georgia (USA)* Nov 1985, 194-202.
- Allen PC (1987).** Physiological responses of chicken gut tissue to coccidial infection: comparative effects of *Eimeria acervulina* and *Eimeria mitis* on mucosal mass, carotenoid content, and brush border enzyme activity. *Poultry Science* **66** 1306-1315.
- Allen PC (1992).** Effect of virginiamycin on serum carotenoid level and long segmented filamentous organisms in broiler chicks. *Avian Diseases* **36** 852-857.
- Augustin PC and Ruff MD (1983).** Changes in carotenoid and vitamin A levels in young turkeys infected with *Eimeria meleagridis* or *Eimeria adenoides*. *Avian Diseases* **27** 963-971.
- Conway DP, Sasai K, Gaafar SM and Smothers CD (1993).** Effect of different levels of oocyst inocula of *Eimeria acervulina*, *Eimeria tenella* and *Eimeria maxima* on plasma constituent, packed cell volume, lesion scores and performance in chickens. *Avian Diseases* **37** 118-123.
- Fernando MA and McCraw BIM (1973).** Mucosal morphology and cellular renewal in the intestine of chickens following a single infection of *Eimeria acervulina*. *The Journal of Parasitology* **59** 493-501.
- Greif G (2000).** Immunity to coccidiosis after treatment with toltrazouril. *Parasitology Research* **86** 787-90.
- Mansoori B, Nodeh H, Modirsanei M, Rahabri S and Aparnak P (2009).** D-xylose absorption test: a tool for the assessment of the effect of anticoccidials on intestinal absorptive capacity of broilers during experimental coccidiosis. *Animal Feed Science and Technology* **148** 301-308.
- Matthews JO and Southern LL (2000).** The effect of dietary betaine in *Eimeria Acervulina*-infected chicks. *Poultry Science* **79** 60-65.
- McDougald LR and Fitz-Coy SH (2008).** *Coccidiosis*, chapters on disease of poultry 12th edition 1069.
- Ruff MD and Fuller HL (1975).** Some mechanisms of reduction of carotenoid levels in chickens infected with *Eimeria acervulina* or *Eimeria tenella*. *Journal of Nutrition* **105** 1447-1456.
- Ruff MD and Wilkins GC (1984).** Intestinal absorption following challenge of immune chicks with *Eimeria acervulina*. *Avian Pathology* **13** 25-35.
- Ryley JF, Meade R, Ifazalburst J and Robinson TE (1976).** Methods in coccidiosis research: separation of oocyst from faeces. *Parasitology* **73** 311-326.
- Shojaei SSR (2004).** Study of small intestine mucosal changes following coccidial vaccination in broilers, Unpublished data, (PhD project on Veterinary Parasitology, Registration number: 169 Department of Parasitology, Faculty of Veterinary Medicine, University of Tehran)
- Surai PF, Speake BK and Sparks N (2001a).** Carotenoids in avian nutrition and embryonic development. 2. Antioxidants properties in discrimination in embryonic tissues. *Journal of Poultry Science* **38** 117-145.
- Tzouganaki ZD, Atta-Poltou T and Koupparts MA (2002).** Development and validation of liquid chromatographic method for the determination of lycopene in plasma. *Analytica Chimica Acta* **467** 115-23.
- Williams AW, Boileau TWM and Erdman JW Jr (1998).** Factors influencing the uptake and absorption of carotenoids. *Proceedings of the Society for Experimental Biology and Medicine* **218** 106-8.