

Case Report

**GALLBLADDER AGENESIS – RADIOLOGIST GOOGLE,
A CASE REPORT**

***Mohamed Rafi**

*Registrar in radiology, Department of Imaging, Ahmadi Hospital,
Kuwait Oil company, Ahmadi, Kuwait*

**Author for Correspondence*

ABSTRACT

Gall bladder, the storage organ for the bile in between the meal plays a role in making the bile concentration and help in digestion by excretion immediately after meal. Sometimes there will be complete gall bladder agenesis in a person with near normal life. We are reporting this rare incidence of congenital GB agenesis, literally neat cholecystectomy in adult female –which will give a difficult situation to the radiologist and surgeon, Although GB is absent.

Keywords: Gallbladder agenesis, USG, CT, MRI

INTRODUCTION

The Gall bladder, the storage organ for the bile in between the meal and expulsion of it during meal plays a role in making the bile concentration and help in digestion by excretion immediately after meal. Its nightmare for surgeon –its pathology varies from acute cholecystitis to gangrenous cholecystitis. The Gall balder which develop from the hepatic diverticulum, second part of hepatic diverticulum is pars cystica - smaller ventral invagination which further give rise to cystic duct and gall bladder (Hill, 2018). Sometimes failure of development of pars cystica rise to gall bladder agenesis. Reported incidence is 0.013 and 0.075% (Jenna and Simon, 2016). In our department during our busy outpatient USG, we came across the similar case, which led to further investigation and confirmation of our diagnosis. Clinically they are present with biliary colic, in USG, mostly diagnosed as chronic cholecystitis-contracted GB. By diagnosing this rare entity, we can prevent the unneeded invasive laparoscopy and complication.

CASE

41 Years old non obese healthy female from the south Indian origin who was previously diagnosed as chronic calculus cholecystitis 4 months before, came with the similar complaint of right upper quadrant pain. Although patient was in fasting, By USG gall bladder was not localized even by repeated examination and different radiologist.

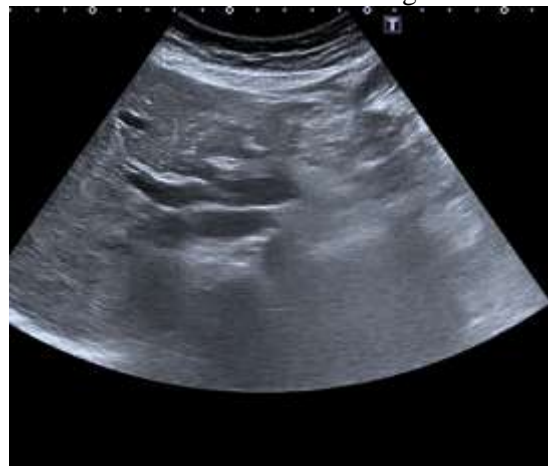

Figure1 : Longitudinal USG shows non visualization of GB with normal CBD

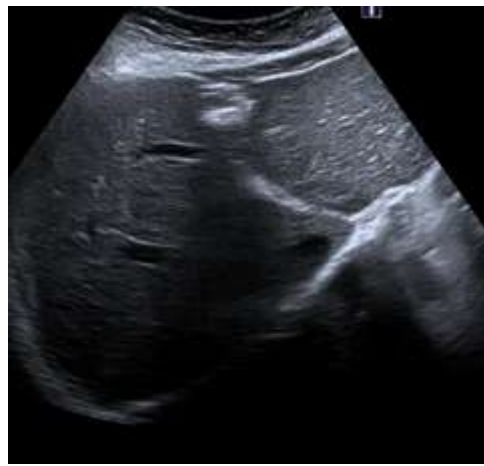

Figure 2 : Transverse USG shows non visualization of GB in GB fossa

Case Report

Then patient was subjected to non-enhanced CT of the abdomen with possible diagnosis of contracted GB. The CT abdomen showed complete absence of Gall bladder, making relief to the patient and refereeing surgeon.

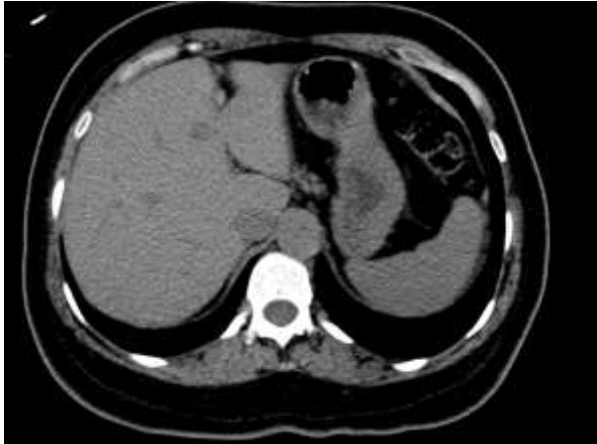

Figure 3

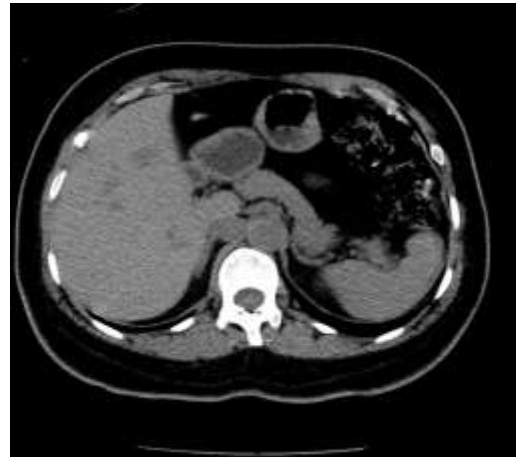


Figure 4

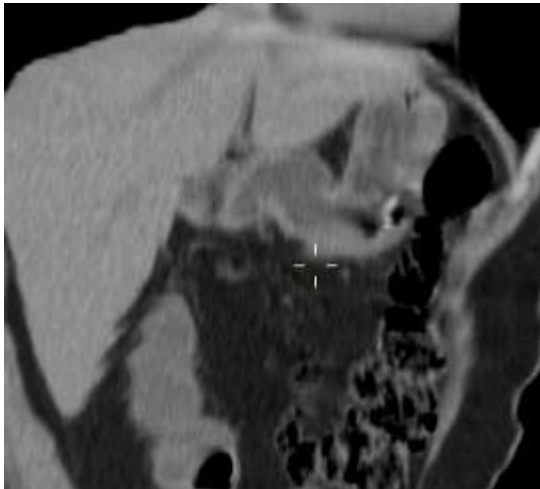


Figure 5

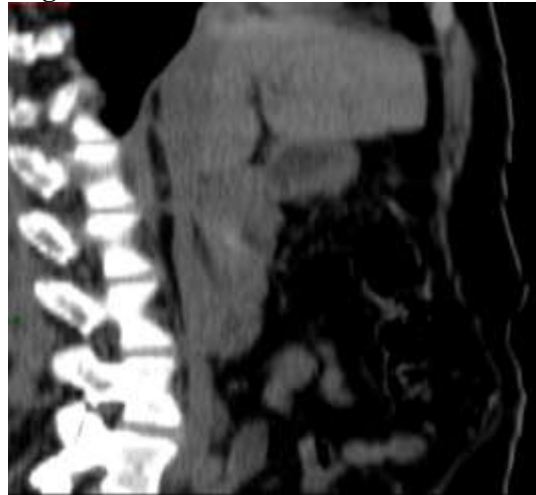

Figure 6

DISCUSSION

Incidence and presnation

Congenital gall bladder agenesis is one of the rare entity with reported incidence of 0.013 and 0.075% (Jenna, 2016). Although its rare entity, thinking one of it as the differential diagnosis is worth, when radiologist on doing USG not able to visualize gall bladder. Incidence is more common in females (M:F-1:3). Autopsy studies report an equal gender incidence (Wilson, 1986).

The first case of agenesis had been reported by Lemary in 1701 (Stephenson, 2010). The incidence of gallbladder agenesis at birth is about 0.02% (Praseedom, 1998), or 1 in 6000 live births. It has been observed in both children and adults, with a median age of 46 at the time of diagnosis (Bennion, 1988). In our case age of the patient is 41, close to the median age of presentation. Patient usually presented in the second or third decade (Kasi, 2011). Our patient is at 3rd decade, which is the most common age of presentation. In 1988, Bennion *et al.*, found 208 symptomatic cases of AG in the literature. 90.1% presented with right upper abdominal pain, 66.3% with nausea or vomiting and 37.5% with fatty food intolerance. Thirty-two percent of these patients presented with a common bile duct dilatation whereas

Case Report

only 27% had gallstones. It is associated with a dilatation of the common duct or gallstones in 25-50% of case (Peloponissios, 2005)

Common pitfalls

Because of the presence of duodenal gas, patient obesity and technical skills of the machine and radiologist and common clinical presentation of biliary colic, congenital gall bladder agenesis had been misreported as contracted GB, Fibrous thickened gall bladder and chronic cholecystitis (Balakrishnan, 2006). And many cases in literature had been diagnosed in laparoscopy after difficult exploration (Balakrishnan, 2006). Failure to visualize the gallbladder at laparoscopy prompts surgeons to undertake a laparoscopic or open exploration of the biliary tracts, frequently it is without any benefit and adds considerably to the morbidity of the procedure. This may in fact expose the biliary tree to iatrogenic injury. Case had been reported where hepatic hemangioma can be misinterpreted as contracted GB and proceeded for laparoscopy and diagnosis of gall bladder agenesis had been confirmed after post-operative MRI (Praseedom, 1998). Similarly any fibrous band and hypertrophied filariform ligament can mimic a GB in case of congenital Gall bladder agenesis.

Classification of Gall bladder agenesis

Bennion *et al.*, (1988) suggested a classification system for AG based on a review of cases worldwide. They identified three groups:

- (1) Multiple fetal anomalies, the most common malformations being cardiovascular, followed by gastrointestinal and genitourinary,
- (2) Asymptomatic cases, in which agenesis of the gallbladder was found at autopsy or laparotomy for another reason and, in some cases, there was a familial association, and
- (3) Symptomatic cases, with the most common associated symptoms being biliary colic (54%), dyspepsia (34%), and jaundice (27%).

Our case represents the symptomatic type, with features of biliary colic.

Associated anomalies of Gall bladder agenesis

Multiple anomalies involving the genitourinary (83% reproductive tract, 42% renal), gastrointestinal (46% imperforate anus, 23% tracheoesophageal fistula), cardiovascular (54% cardiac defects, 23% single umbilical artery), and skeletal (31%) systems had been reported (10) in the autopsy series of gall bladder agenesis. There is no any associated anomalies are detected in our patient. Associated syndromes includes Klippel Feil syndrome, heterotaxy syndrome, polysplenia syndrome and asplenia syndrome

Approach to Clinical diagnosis

Any patient suspected to have gall bladder pathology, USG is initial modality of investigation, if the GB is very well visualized in the USG, and then clinical diagnosis can be made at that point. If GB is not found, we had to proceed CT or MRI for further evaluation rather than blindly boogie to laparoscopy. This prevents unwanted laparoscopy and its complication in case of all balder agenesis. Magnetic resonance cholangiography is a noninvasive imaging method in the evaluation of the biliary tract; it demonstrates or excludes gallbladder agenesis. Cost and time are the limiting factor.

Conclusion

Congenital absence of the gallbladder which gives clinical dilemma and googling of the liver by radiologist, should always kept in my mind by clever radiologist and successful surgeons to prevent complication of laparoscopy and medico legal issues and reduce the anxiety of the patients. If USG failed to demonstrate the GB, patient should be referred to higher modalities like CT or MRI for further diagnosis rather than laparoscopy.

REFERENCES

- Balakrishnan S, Singhal T, Grandy-Smith S and El-Hasani S (2006).** Agenesis of the Gallbladder: Lessons to Learn. *JLS : Journal of the Society of Laparoendoscopic Surgeons*, **10**(4) 517-519.
- Bennion RS, Thompson JE, Jr., and Tompkins RK (1988).** Agenesis of the gallbladder without extrahepatic biliary atresia. *Archives of Surgery*, **123**(10) 1257-1260.

Case Report

Hill, MA (2018). Embryology- *Gastrointestinal Tract - Gall Bladder Development*. Retrieved from https://embryology.med.unsw.edu.au/embryology/index.php/Gastrointestinal_Tract_-_Gall_Bladder_Development [Accessed on: March 2018].

Jenna L Scobie and Simon R Bramhall (2016). Congenital agenesis of the gallbladder: a UK case report, *Oxford Medical Case Reports*, **8**(1).

Kasi PM, Ramirez R, Rogal SS, Littleton K and Fasanella KE (2011). Gallbladder Agensis. *Case Reports in Gastroenterology* **5**(3) 654-662. doi:10.1159/000334988.

Peloponissios N, Gillet M, Cavin R and Halkic N (2005). Agensis of the gallbladder: A dangerously misdiagnosed malformation. *World Journal of Gastroenterology*, **11**(39) 6228-6231. doi:10.3748/wjg.v11.i39.6228

Praseedom RK and Mohammed R. (1998). Two cases of gall bladder agenesis and review of the literature. *Hepato-Gastroenterology* **45**(22) 954–955.

Stephenson JA, Norwood M and Al-Leswas D et al., (2010) Hepatic Haemangioma Masquerading as the Gallbladder in a Case of Gallbladder Agensis: A Case Report and Literature Review. *HPB Surgery*. doi:10.1155/2010/971609.

Turkel SB, Swanson V and Chandrasoma P (1983). Malformations associated with congenital absence of the gall bladder. *Journal of Medical Genetics*, **20**(6) 445-449.

Wilson JE, Deitrick JE (1986). Agensis of the gallbladder: case report and familial investigation. *Surgery*, **99**(1) 106–109.