

Case Report

ACTINOMYCOSIS OF KNEE JOINT: AN UNUSUAL CASE REPORT

Nagarathna Rao H.N.¹, Rao K.S.², Nagaraj T.S.¹, Medha Shankarling¹, Sunita Annie Z.¹,
*Kuladeepa Ananda Vaidya¹ and Sukesh¹

¹Department of Pathology, Srinivas Institute of Medical Science and Research Centre, Mukka,
Mangalore, 575021

²Consultant Orthopaedic Surgeon, Spandana Hospital, Karkala, Udupi Dist 574104

*Author for Correspondence

ABSTRACT

Primary actinomycosis of knee joint is a rare entity and poses a diagnosis challenge to clinicians by mimicking other common knee joint lesions. The classic microscopic appearance of this organism in tissue biopsy often forms the basis of diagnosis. Early diagnosis and treatment of actinomycosis reduces the rate of surgical treatment, mortality and morbidity. Increased awareness regarding this entity and high degree of suspicion are required while evaluating sub-acute or chronic inflammatory lesions involving knee joint so that an early diagnosis is possible and undue delay in treatment can be prevented. In this article we report a rare case of primary actinomycosis of the knee joint in a 62year old male patient, presented with a swelling around the right knee joint.

Keywords: Actinomycosis, Knee Joint, Diagnosis

INTRODUCTION

Actinomycosis is caused by Gram-positive, branching, filamentous bacteria which results in chronic suppurative inflammation of the organs involved (Schwartz and Wilson, 2001). The major clinical forms of actinomycosis are cervicofacial, thoracic, abdominal, pelvic and systemic forms (Kumar *et al.*, 2008; Robinson *et al.*, 2005). Actinomycosis was first described as a clinical entity over 100 years ago (Nagler *et al.*, 1997). It is a suppurative and granulomatous chronic infectious disease, rarely diagnosed in the human. First case of actinomycosis in man was described by Von (1845) and it was attributed to a fungus. Israel and Ponfick (1891) defined the anaerobic nature of actinomyces and isolated it in man. Waksman (1960) showed that actinomyces was a Gram positive bacteria (Lancella *et al.*, 2008). Herewith we are presenting this case of primary actinomycosis of knee joint, since primary bone and joint actinomycosis is considered as a very rare entity with lot of diagnostic challenges.

CASES

A 62year old male presented with pain, swelling with redness around the right knee joint and lower part of right thigh since 2 months. No history of recent trauma, past surgery, loss of weight or appetite was noted. Patient had an episode of low grade fever, few days ago. Patient was a known diabetic and on oral hypoglycemic treatment. No other significant medical histories were elicited. Physical examination of the right knee joint revealed a stiff, moderately swollen and tender, joint. A single sinus adherent to the joint noted surrounded by areas of induration.

Radiographic studies of the knee joint showed nonspecific changes with mild sclerosis in the peri-articular bones and mild reduction of the joint space [Figure 1]. Laboratory investigations revealed mild elevation in white blood cell count (12000/mm³) and erythrocyte sedimentation rate (40mm/h). FNA from indurated area of the swelling was tried, but yielded scanty inadequate, material. Synovial fluid analysis showed a suppurative type of lesion. No other laboratory parameters were significant. Based on clinical and investigative findings, clinical diagnosis of chronic infective arthritis was made. Patient was started on broad spectrum antibiotic and posted for surgery under spinal anaesthesia. Intraoperative findings revealed mild erosion of cartilage, thickened synovium covered by fibrinous exudate. Total synovectomy was done. Abscesses were drained, sinus was excised and necrotic tissues were removed. Specimen was sent in 10% formalin for histopathological examination.

Case Report

Gross examination of the specimen showed, multiple irregular greyish yellow tissue covered by slough (collectively m/s 4x3x3cm), attached to fibrofatty tissue. Histopathological evaluation of the sections from the lesional tissue showed colonies of radiating filamentous organisms surrounded by numerous neutrophils [Figure 2]. Gram staining of the slides revealed the gram positive organism in the center surrounded by a peripheral swollen club shaped splendor hoepli. No evidence of granuloma or caseous necrosis. Periphery of the lesion showed lymphocytes, macropages and areas of fibrosis. Based on these microscopic findings, a final diagnosis of actinomycosis of the knee joint was made. Penicillin was administered parenterally for 2 weeks. The patient was discharged by maintaining oral treatment with amoxicillin. Follow-up was done; patient was responded well to the treatment and symptoms and signs subsided [Figure 3]. On further follow up there were no signs of recurrence.

DISCUSSION

Main causative agent for actinomycosis is *Actinomyces israelii*. This species is strictly a commensal of the oropharynx, gastrointestinal and female genital tracts. Actinomycosis is usually secondary to trauma to these areas. The infection is characterised by abscess formation, draining sinuses and tissue fibrosis (Ruhe *et al.*, 2001).

Actinomycosis of the joint is usually due to adjacent spread of soft tissue infection but the infection may occur following trauma or can be due to hematogenous spread (Kumar *et al.*, 2008; Tekin *et al.*, 2012; Smego and Foglia, 1998; Mert *et al.*, 2001). Common risk factors include post-traumatic osteoarthritis, previous surgery, chronic liver disease, corticoid therapy and intravenous drug abuse (Cordero-Ampuero and de-Dios, 2010), but contrary to it, in our case all these predisposing factors were absent. Only predisposing factor which can be pointed out in our case was diabetes mellitus.

Diagnosing actinomycosis is difficult, as symptoms are often nonspecific (Volante *et al.*, 2005).

Discharge of sulphur granule is a characteristic feature helping the clinical diagnosis. According to some authors, the characteristic sulphur granules, in the specimens, are present in only 35-55% of cases. In these cases, the diagnosis is definitive (Kumar *et al.*, 2008; Smego and Foglia, 1998) but in our case these granules were not seen.

Radiological features of actinomycosis include both destruction and formation of bone, manifesting as multiple lytic lesion with sclerosis and periosteal reaction (Kumar *et al.*, 2008; Robinson *et al.*, 2005). The imaging techniques like computed tomography (CT) and magnetic resonance imaging (MRI) usually yield nonspecific findings (Volante *et al.*, 2005). In the present case also the radiological changes were nonspecific, not adding anything extra to the clinical diagnosis of chronic infective arthritis. In view of these non-specific manifestations and imaging findings, the diagnosis of actinomycosis still remains difficult (Volante *et al.*, 2005).

Fine-needle aspiration cytology (FNAC) is a less invasive diagnostic technique compared to incisional biopsy in diagnosing this condition, but is dependent on sampling of the representative area (Volante *et al.*, 2005). In our case we had also tried with FNA from indurated area of the swelling, but yielded scanty material and could not draw any specific diagnosis.

Tuberculous arthritis may mimic knee Actinomycosis, especially in countries where tuberculosis is endemic (Yusof *et al.*, 2005). In our case we have ruled out tuberculosis by doing Ziehl Neelsen (ZN) stain on cytological smears from joint effusion, and on histological sections taken from synovial tissue. Histopathological examination also not showed any evidence of caseous necrosis or granulomatous inflammation.

The histopathological examination of the lesion is significant to support the pathology by demonstrating the organisms (Metgud, 2008). Histopathological features of actinomycosis are collection of radiating filamentous organisms with central necrosis surrounded by neutrophils and sulphur granules. Gram staining of the slides will reveal the gram positive mycelium in the centre surrounded by a peripheral swollen club shaped structures which gram negative are giving a sunray appearance (Takasaki *et al.*, 2006). Thus it is also called as 'Ray fungus'. The fibrous walls of the mass give woody feel (Yadav *et al.*, 2002). These filaments of these organisms are also positive for PAS and GMS but negative for acid fast

Case Report

staining thus differentiating it from its similar histomorphologic counterpart, nocardiosis whose filaments are acid fast positive (Ramachandra *et al.*, 2014).

In the majority of cases of actinomycosis the therapy consisted of surgical debridement combined with prolonged antibiotic therapy (Tekin *et al.*, 2012). This chronic infection elicits marked fibrotic reaction making difficult for drug penetration and unable to achieve the desired serum levels of the antibiotics delaying response to treatment (Ramachandra *et al.*, 2014; Hay and Adriaans, 1998). Penicillin is the drug of choice for treatment of actinomycosis (Ramachandra *et al.*, 2014) and it must be considered in a moderately high dosage parenterally over a long period of time. Routinely 1-6 million units per day administered for a minimum period of 6-8 weeks. Severe cases may require 12 to 20 million units per day for a more sustained period of time (Dom and Pittevis, 1999).

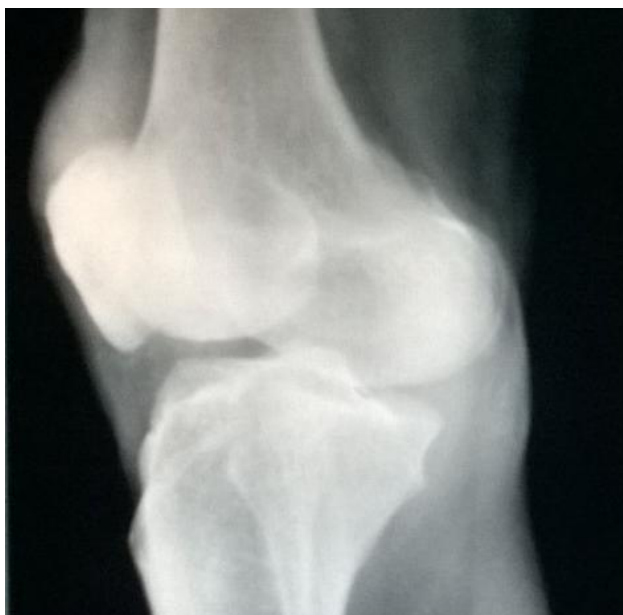

Figure 1: X ray of the knee joint showing nonspecific changes with mild reduction in joint space

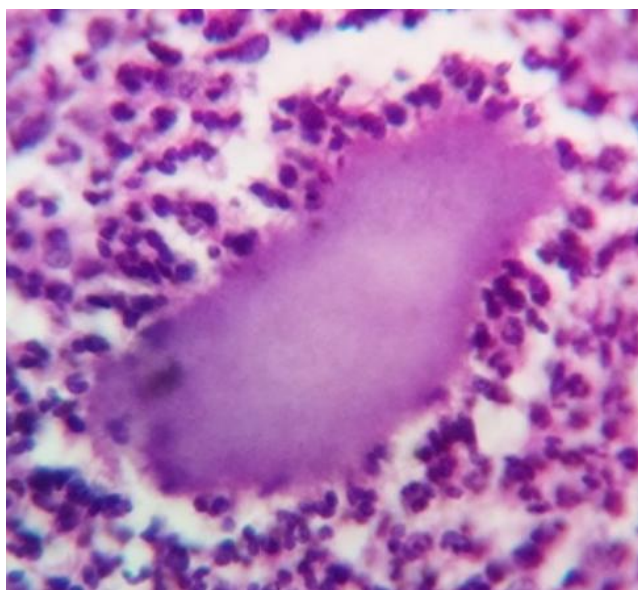


Figure 2: Histopathological section showing actinomycotic colony surrounded by neutrophils (H&E stain, higher magnification)

Case Report

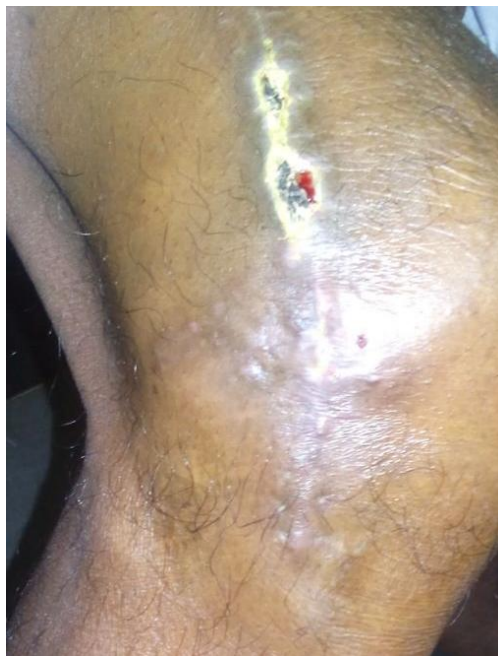

Figure 3: Post-operative photograph showing healed lesion and no signs of recurrence

Surgical treatment is often indicated for curettage of bone, resection of necrotic tissue, excision of sinus tracts, and drainage of soft tissue abscesses (Robinson *et al.*, 2005). Although recommendations for incision and drainage of abscesses, sinus tract excision and more extensive debulking of infected tissue are made, it is unclear how often these procedures are necessary (Tekin *et al.*, 2012; Smego and Foglia, 1998; Kargi *et al.*, 2003).

Conclusion

Primary actinomycosis of knee joint is a rare entity. The classic microscopic appearance of this organism in tissue biopsy often forms the basis of diagnosis. Increased awareness regarding actinomycosis of joint and high degree of suspicion are required while evaluating sub-acute or chronic inflammatory lesions involving knee joint to achieve an early diagnosis and to prevent undue delay in treatment.

REFERENCES

- Cordero-Ampuero J and de Dios M (2010).** What are the risk factors for infection in hemiarthroplasties and total hip arthroplasties? *Clinical Orthopaedics and Related Research* **468**(12) 3268–77.
- Dom K and Pittevis T (1999).** Synovial actinomycosis of the hip: case report and review. *Acta Orthopaedica and Belgica* **65** 242-4.
- Hay JR and Adriaans B (1998).** Bacterial infections. In: Rook/Wilkinson/Ebling, editors. *Textbook of Dermatology*, 6th edition (Blackwell science) Oxford 1171-3.
- Kargi E, Akduman D, Güngör E, Deren O and Albayrak L et al., (2003).** Primary extremity actinomycosis causing osteomyelitis of the hand. *Plastic and Reconstructive Surgery* **112** 1495-7.
- Kumar A, Varshney MK, Trikha V, Khan SA and Yadav CS et al., (2008).** A rare actinomycosis of humerus: an unusual location and a diagnostic dilemma, A case report. *Archives of Orthopaedic and Trauma Surgery* **128** 121-4.
- Lancella A, Abbate G, Foscolo1 AM and Dosdegani R (2008).** Two unusual presentations of cervicofacial Actinomycosis and review of the literature. *Acta Otorhinolaryngologica Italica* **28** 89-93.
- Mert A, Bilir M, Bahar H, Torun M and Tabak F et al., (2001).** Primary actinomycosis of the hand: a case report and literature review. *International Journal of Infectious Diseases* **5** 112-4.
- Metgud SC (2008).** Primary cutaneous actinomycosis: A rare soft tissue infection. *Indian Journal of Medical Microbiology* **26** 184-6.

Case Report

Nagler R, Paled M and Laufer D (1997). Cervicofacial actinomycosis: a diagnostic challenge. *Oral Surgery, Oral Medicine, Oral Pathology, Oral Radiology Endodontology* **83** 652-6.

Ramachandra S, Kuruvila S and John (2014). Actinomycosis of the ankle joint. *APALM* **1**(1) 37-40

Robinson JL, Vaudry WL and Dobrovolsky W (2005). Actinomycosis presenting as osteomyelitis in the pediatric population. *Pediatric Infectious Disease Journal* **24** 365-69.

Ruhe J, Holding K and Mushatt D (2001). Infected total knee arthroplasty due to *Actinomyces naeslundii*. *Scandinavian Journal of Infectious Diseases* **33** 230-1.

Schwartz HC and Wilson MC (2001). Cervicofacial actinomycosis following orthognathic surgery: report of 2 cases. *Journal of Oral and Maxillofacial Surgery* **59** 447-9.

Smego RA Jr and Foglia G (1998). Actinomycosis. *Clinical Infectious Diseases* **26** 1255-61.

Takasaki K, Kitaoka K, Kaieda S, Hayashi T, Abe K and Takahashi H (2006). A case of actinomycosis causing unilateral tonsillar hypertrophy. *Acta Oto-laryngologica* **126** 1001-4.

Tekin R, Gem M, Karakaya YA, Boşnak V and Kapukkaya A (2012). Primary Actinomycosis of the Knee and Ankle Joint: An Unusual Manifestation. *Journal of Bacteriology & Parasitology* **3** 137.

Volante M, Contucci AM, Fantoni M, Ricci R and Galli J (2005). Cervicofacial actinomycosis: still a difficult differential diagnosis. *Acta Otorhinolaryngologica Italica* **25** 116-9.

Yadav SPS, Chanda R, Gathwala G and Yadav RK (2002). Actinomycosis of tonsil masquerading as tumour in a 12-year old child. *International Journal of Pediatric Otorhinolaryngology* **63** 73-75.

Yusof MI, Yusof AH, Salzihan M, Salleh M and Harun A (2005). Actinomycosis of the knee. *Malaysian Journal of Medical Sciences* **11**(1) 68-9.