

**Research Article**

## **HEAVY SYNGAMUS TRACHEA INFECTION OF NATIVE CHICKENS IN PIRANSHAHR CITY, IRAN**

**Haji Mohammadi Mohsen<sup>1</sup> and \*Garedaghi Yagoob<sup>2</sup>**

<sup>1</sup>*Department of Veterinary Medicine, Tabriz branch, Islamic Azad University, Tabriz, Iran*

<sup>2</sup>*Department of Veterinary Parasitology, Tabriz Branch, Islamic Azad University, Tabriz, Iran*

*\*Author for Correspondence*

### **ABSTRACT**

A survey of pulmonary helminthes parasites of domestic chickens was carried out in Piranshahr city, Iran during 2014. One hundred (100) pulmonary samples were examined in necropsies chickens microscopically using the lactophenole and carmine-acid staining technique. The result showed a low prevalence of pulmonary helminthes parasitic infection but in one of the study birds number of *Syngamus trachea* was very high and heavy (48 adult worm in one trachea). Out of a total of 100 domestic chicken studied 3 (3%) were infected by *Syngamus trachea* parasite. The study reveals that there was a low prevalence but Heavy *Syngamus trachea* infection of pulmonary helminthes parasites of domestic chicken in the study area. This calls for improved management and disease control to enhance their potential.

**Keywords:** *Syngamus Trachea, Native Chicken, Piranshahr City, Iran*

### **INTRODUCTION**

Syngamiasis is the infection caused by the nematode worm *Syngamus trachea*. *S. trachea* is a nematode affecting the respiratory system of a variety of domestic and wild avian species (Sanmartin *et al.*, 2004). *S. trachea* is also called the forked "worm" with a letter "Y" shaped appearance due to the male and female's permanent copulating position and "gape worm" because of the gaping stance of affected birds. Syngamiasis is typified by tracheitis, respiratory distresses manifesting as coughing, sneezing and attempts to stretch the neck (Huschen and Horn, 2012). Fatalities are common in young birds and major risk factors are

Inclement weather, diets of the birds and the quality of ration consumed (de Witt, 1995; Huschen and Horn, 2012). *Syngamus trachea* can be very harmful, especially for young birds. They are usually not a problem in modern operations under confinement conditions. But they can be a serious problem in free-range poultry, particularly if the birds have access to humid environments with abundant intermediate hosts (earthworms, snails, etc.). These worms are often a problem in pheasant farms. In regions with a cold winter infections occur mainly during late spring and summer, along with the peaks in the populations of intermediate hosts (Birdlife International, 2012). A few worms are usually well tolerated, especially by adult birds, which usually develop natural resistance if previously exposed to the worms. But in heavy infections the worms cause inflammation of the wall of the trachea and an increased mucus production, sometimes mixed with blood leaking from the small injuries caused by the worms. Clinical signs include coughing, sneezing and respiratory disturbances. Initially the birds try to expel the worms vigorously shaking their heads. Later they repeatedly gape and breathe with a hissing sound. They refuse to drink, lose appetite and weight and become apathetic. Anemia can also occur. Deaths can happen, particularly in young birds (Sinclair and Ryan, 2003).

### **MATERIALS AND METHODS**

#### **Study Area**

The study was conducted in Piranshahr city, Iran. The study vicinity has a subtropical weather, the raining season is usually from April to October while the dry season begins in November and ends in March.

#### **Collection of Samples**

The study area was visited twice in a month and maximum of 20 samples were collected every month from different domestic chicken from August to October, 2014. A total of 100 pulmonary tract samples of

### Research Article

local breed chicken slaughtered at the local markets and shops located in piranshahr city, Iran were collected. The pulmonary tracts were collected into plastic bags and taken to the diagnostic and examination laboratory of the veterinary medicine, Islamic Azad University, Tabriz branch for examination and identification. Samples that could not be immediately analyzed were stored in the refrigerator.

#### Examination of Samples

The pulmonary tracts especially Trachea was cut open by longitudinal incision. Tracheal scrapping was done and any parasite seen was removed with forceps, washed in saline and identified. Examination of samples for helminthes was based on lactophenole and carmine-acid staining technique (Soulsby, 1982). The preparations were then examined under the microscope using x10 and x40 magnification.

#### Data Analysis

The results obtained were analyzed using descriptive statistics. Level of significance was set at  $p < 0.05$ .

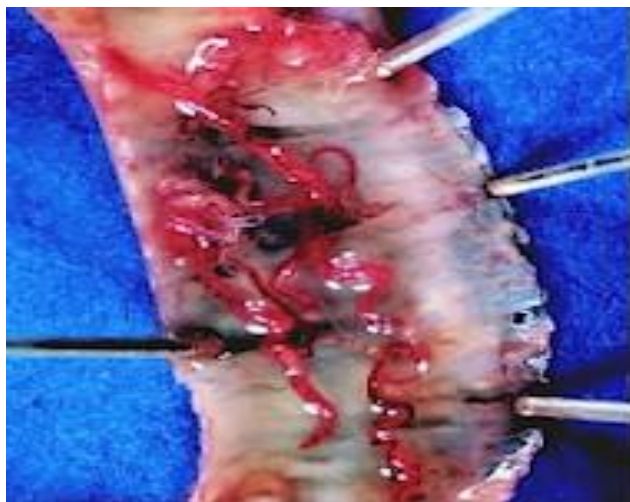
## RESULTS AND DISCUSSION

### Results

The result showed a low prevalence of pulmonary helminthes parasitic infection but in one of the study birds number of *syngamus trachea* was very high and heavy (48 adult worm in one trachea). Out of a total of 100 domestic chicken studied 3 (3%) were infected by *syngamus trachea* parasite (Table-1) and (figure 1-2).

**Table 1: Numbers of *syngamus trachea* worm in 3 infected birds**

Infected birds	Numbers of <i>syngamus trachea</i>	Number of worms	Male	Number of female worms
1	12	6	6	
2	16	8	8	
3	48	24	24	



**Figure 1: *Syngamus trachea* in to the trachea of native chickens**



**Figure 2: Adult worms of *Syngamus trachea* isolated from native chickens trachea**

### Discussion

Syngamiasis is the infestation of avian respiratory system with *Syngamus trachea* and is noted to be widespread in Africa and Asia (Sanmartin, 2004). Limited documented report of Syngamiasis in wild birds in Africa does not however support this level of spread. Pathogenicity of *S. trachea* is severe (Subramanian, 2003) with profound loss of muscle mass (deWitt, 1995) and massive mortalities (Huschen

### **Research Article**

and Horn, 2012) having been recorded in birds. The trachea is the predilection site for the adult worms (Welte and Kirkpatrick, 1986).

The occurrence of parasites is probably, the most damaging infections of domestic chicken and a source of serious economic loss. The main effect of helminthes parasites is the amazing losses they cause to animal industries through meat contamination and morbidity (Naem and Eskandari, 2005). The generally high prevalence rate observed in this report could be due to the fact that birds kept under free range or backyard scavenging flocks are not normally fed with grains in the morning (which use to be the practice in the early years) before going out for grazing. Lack of this practice could be attributed to the present poor economic condition.

The results of this study showed a low prevalence of pulmonary helminthes parasitic infection but in one of the study birds number of syngamus trachea was very high and heavy(48 adult worm in one trachea). Out of a total of 100 domestic chicken studied 3 (3%) were infected by syngamus trachea parasite. The study reveals that there was a low prevalence but Heavy Syngamus trachea infection of pulmonary helminthes parasites of domestic chicken in the study area. This calls for improved management and disease control to enhance their potential.

### **Conclusion**

The study reveals that there was a low prevalence but Heavy Syngamus trachea infection of pulmonary helminthes parasites of domestic chicken in the study area.

### **ACKNOWLEDGMENT**

The authors wish to thanks the Islamic Azad University, Tabriz Branch, Tabriz, Iran for the financial supports, and all laboratory technicians for technical aids in this project.

### **Competing Interests**

Authors have declared that no competing interests exist.

### **REFERENCES**

- Ajayi SA and Ajayi ST (1983).**Incidence of blood gastrointestinal parasites in domestic animals on Jos Plateau. In: *Proceeding of National Workshop on Disease of Livestock and Poultry held at National Veterinary Research Institute*, Vom 17-18.
- Akinwumi JA, Adegege AJ, Olayide SO and Ikpi AE (1979).** Report on Economic Analysis of Poultry. *Federal Livestock Department Magazine*, Lagos.
- Birdlife International (2012).** Tyto alba. IUCN Red List of Threatened Species Version 2013/2 International Union for Conservation of Nature.
- Cole RA (1999).** Tracheal worms In: *Field Manual of Wildlife Diseases: General Field Procedures and Diseases of Birds Biological Resource Division*, edited by Milton F and Franson JC, Madison USA 229-232.
- De Witt JJ (1995).** *Mortality of Rheas Caused by Syngamus Trachea Infection VetQ* **17**(1) 39-40.
- Damerow G (1994).** The chicken health handbook, Story books. ISBN 0.88266-611.
- Eslami A and Anwar M (1973).** Frequence des helminthes chez les volailles en Iran. *Revue d'elevageet de medecineveterinaire des pays tropicaux* **29** 309-311.
- Eslami A, Ghaemi P and Rahbari S (2009).**Parasitic Infections of Free – Range Chickens from Golestan Province, Iran. *Iranian Journal of Parasitology* **4**(3) 10-14.
- Fatih MT, Ogbogu VC, Njoku CO and Saror D (1991).** Comparative studies of Gastrointestinal Helminths of Poultry in Zaria, Iran. *Nevue de elevageet de medecine veterinaire des pays Tropicaux* **44**(2) 175- 177.
- Garedaghi Yaghoob (2011).** Identification of Immunogenic Relevant Antigens in the Excretory-secretory (ES) Products of *Ascaridiagalli* Larvae. *Advances in Environmental Biology* **5**(6) 1120-1126.
- Hodasi JKM (1979).** Helminths fauna of native domestic chickens in Ghana. *Journal of Helminthology* 33-35.

**Research Article**

- Huschen MS and Horn DJ (2012).** Mass death of wintering American robins (*Turdus migratorius*) in Decatur. *Illinois Transactions of the Illinois State Academy of Science* **105**(1&2) 51-55.
- Luka SA and Ndams IS (2007).** Gastrointestinal parasites of Domestic chickens *Gallus gallus domesticus* Linnaeus, 1758 in Samaru, Zaria, Iran. *Science World Journal* **2**(1) 27 - 29.
- Lamka J, Svoboda V and Slezkova J (1997).** Anthelmintic efficacy of ivermectin against *Syngamus trachea* and *Capillaria* spp. in pheasants *VetMed (Praha)* **42**(6) 157-160.
- MAFF (1977).** Technical Bulletin, No.18. Manual of Veterinary Parasitological Laboratory Techniques, HMSO, London.
- Naem S and Eskandari S (2005).** Prevalence of intestinal helminths of native chickens in Urmia Iran. *Iranian* **3**(2) 200 - 203.
- Nair KV and Nadakal AM (1981).** Haematological changes in domestic chicken infected with cestode *Raillietina tetragona*. *Veterinary Parasitology Journal* **8** 49-58.
- Oluyemi JA and Robert AA (1979).** Poultry production in warm wet climate. Macmillan London.
- Oyeka CA (1989).** Prevalence of intestinal helminths in poultry in Anambra state, Iran. *Bulletin of Animal Health and Production in Africa* **37** 217-220.
- Permin A and Hansen JW (1998).** Epidemiology, diagnosis and control of poultry parasites. FAO Animal Health Manuals and Control of Poultry Parasites, FAO Animal Health Manuals 4, Rome: Food and Agriculture Organization of the United Nations (FAO) 160.
- Riise JC, Permin A, McAinsh CV and Frederiksen L (2004).** Keeping village poultry. A technical manual on small - scale poultry production. Network for smallholder poultry development, Denmark.
- Smyth JD (1976).** *Introduction to Animal Parasites*, 2nd edition (Hazzel Watson and Viney limited) Aylesbury bucks.
- Soulsby E JL (1982).** *Helminths, Arthropods and Protozoans of Domesticated Animals*, 7th edition (Lea and Febiger) Philadelphia, Pa, USA.
- Sanmartin ML, Alvarez F, Barreiro G and Leiro J (2004).** Helminth fauna of Falconiform and Strigiform birds of prey in Galicia North west Spain. *Parasitology Research* **92** 255-263, DOI 10.1007/s00436-003-1042-2.
- Sinclair I and Ryan PA (2003).** *Comprehensive Illustrated Field Guide-Birds of Africa*, South of Sahara (New Holland Publishing) SA236.
- Subramanian KS (2003).** Syngamiasis in a Pea fowl (*Pavocristatus*). *Zoo Print Journal* **18**(9) 1204.