

APPLIED ANATOMY ON THE MAXILLA AND MANDIBULAR REGIONS OF THE BOVINE WITH SPECIAL REFERENCE TO ITS IMPORTANT IN REGIONAL ANAESTHESIA

***Allouch G.M.**

Department of Veterinary Medicine, Qassim University, Kingdom of Saudi Arabia

Department of Anatomy, AL-Baath University, Syria

**Author for Correspondence*

ABSTRACT

The aim of this study is to know the dimensions of some foramina skull, for the applied importance which will help in region nerves block as the supra-orbital, infra-orbital, mandibular and mental nerves which will be necessary for head injuries, surgical operations of the head including ophthalmectomy and eyelids disorders, dehorning as well as the lips injuries and dental operations in the bovine. The Applied anatomical measurements for 24 parts of the skull were made for this study. The skull lengths were 51.23 cm, 27.97 cm and 22.72 cm respectively. The distances of the supra-orbital foramen and groove were 13.91cm, 5.07cm, 8.11cm and 7.22 cm. The dimensions infra-orbital foramen, from the facial tuber to infra-orbital canal, the facial tuber to the infra-orbital foramen, from the latter to the nasal process, to nasoincisive notch and from the foramen to the first upper premolars were 2.5cm, 4.78cm, 4.7cm, 5.86 cm and 2.32cm respectively. The length and the height of mandible parts were 38.3cm, 22.6cm, 5.02cm and 19cm respectively. Moreover; dimensions of mandibular foramen were 3.81cm, 8.05 cm and 8.9cm respectively, The distance to the mental foramen in all directions were 3.71 cm, 6.76 cm, 32.14 cm, 1.8 cm, 33.4 cm, 3.9 cm, 7.9 cm, 1.23 cm and 2.4 cm respectively. These data are discussed with regard to their application to clinical maneuvers around the head of the camel and horse.

Keywords: *Applied Anatomy, Skull, Head, Bovine*

INTRODUCTION

The applied anatomy of the bovine head is very important because of the presence of the organs and structures such as the lips, teeth, tongue, eyes, nose and horns. The applied anatomy is one of the principles of the clinical and surgical practice; because it enables the veterinarian to envisage details of structures relevant to the case at hand, also they are basics of the clinical and surgical practices (Wehausen and Ramey, 2000; Karimi *et al.*, 2011). On the other hand, similarly, face nerves and their passages from different foramina in the skull are of clinical importance in regional anesthesia. The head is thus helped for the equilibrium in the body for deglutition, olfaction and defense by horns (Olopade, 2003). The former literatures described the heads of the domestic animals. Radinsky (1984) studied the skull as being composed of two major components; the neurocranium and the splanchnocranium. Dental eruption and oral pathologies by Otesile and Obasaju (1982); Kene and Agbo (1998) while Olopade *et al.*, (2005) in WAD goat, Monfared *et al.*, (2013) in IN goat and Andrew *et al.*, (2014) in GVD Goat as well as Monfared (2013) in camel and Monfared (2013) in horse demonstrated parameters and measurements in the maxillary and mandible bones of the head region and their application to clinical applications around the head. Budras *et al.*, (2011) recorded that the bovine has the often double infra-orbital foramen. There is a little reference on the applied and applied anatomy of the head and its clinical value for regional anesthesia in the bovine. The present study was implemented because there was an insufficiency of comprehensive parameters and Measurements on the head region of the bovine and its applied implications.

MATERIALS AND METHODS

Skulls of ten adult bovine of both sexes were used for this study. Bovine heads were obtained from slaughterhouse.

Research Article

The heads were cut at the occipitoatlantal joint and processed according to the hot water maceration techniques for skeleton preparation that have been reported by Simoens *et al.*, (1994); Tasbas and Tecirlioglu (1996); Allouch and Alshick (2008). A total of 24 diminutions were measured using measuring tape, callipers of 0.02 mm. The measurements were taken after establishment of standard method (Olopade and Onwuka, 2005; Uddin *et al.*, 2006; Monfared, 2013 a, b).

Measured Landmarks

- 1- Skull length: was taken from the rostral end of the alveolar process of the incisive bone to the occipital crest and divided into cranial and nasal skull (Figure A).
- 2- Nasal skull length: from the cranial edge of the maxillary bone cranially at the level incisor tooth to cranial border of the frontal bone caudally (Figure A).
- 3- Cranial skull length: from the cranial border of the frontal bone cranially to occipital crest caudally of the occipital bone (Figure A).
- 4- Supra-orbital foramina distance: between the two supra-orbital foramina (Figure B).
- 5- Supra-orbital foramen to external frontal crest (temporal line): the value was taken oblique caudally extending from the supra-orbital foramen to the mid-level of the external frontal crest (Figure C).
- 6- Supra-orbital foramen to horn: the measurement was taken horizontally parallel to the external frontal crest (temporal line) to the base of horn (Figure C).
- 7- Supra-orbital groove: runs rostrally and caudally from the supra-orbital canal passing through the supra-orbital foramen (Figure C).
- 8- The facial tuber to infra-orbital canal: from the level of the facial tuber to the mid-level of the infra-orbital canal (Figure D).
- 9 - From the facial tuber to the infra-orbital foramen: measurement was taken craniodorsally obliquely from the facial tuber to the infra-orbital foramen (Figure D).
- 10- From the infra-orbital foramen to the (middle-line Nasal process of the incisive bone): measurement was taken dorsorostrally obliquely from the infra-orbital foramen to the (middle-line Nasal process of the incisive bone (Figure D).
- 11- From the infra-orbital foramen to the nasoincisive notch: measurement was taken vertically from the infra-orbital foramen to the nasoincisive notch between the dorsal nasal bone and the ventral incisive and maxillary bones (Figure D).
- 12- From the infra-orbital foramen to the first upper premolar: measurement was taken vertically from the infra-orbital foramen to the first upper premolar at alveolar border of the first upper premolar.
- 13- Mandibular length: from the level of alveolar border of the incisive bone to the caudal border of the mandible (Figure E).
- 14- Maximum mandibular height: from the basal level of the mandible to the highest point of the coronoid process (Figure E).
- 15- Coronoid process (height point) to condylar process: from the maximum height of mandible to the condylar process (Figure E).
- 16- Condylar process to the base of the mandible: straight line from the condylar process to the base of the mandible (Figure E).
- 17- Mandibular foramen to the caudal border of mandible: the horizontal line from the mandibular foramen to the extreme caudal border of the mandible (Figure F).
- 18- Mandibular foramen to mandibular angle: from the mandibular foramen to the angle of the mandible (Figure F).
- 19- Mandibular foramen to base of mandible: straight vertical line from the mandibular foramen to the base of the mandible (Figure F).
- 20- Lateral alveolar border to mental foramen: distances from the mental foramen to the lateral extent of the alveolar border of lower 4th incisor (Figure G).
- 21- Mental foramen to the Lateral alveolar border of the first premolar tooth: from the mental foramen to the lateral extent of the alveolar root of lower first premolar (Figure G).

Research Article

22- Mental foramen to the caudal mandibular border: from the level of the mental foramen to the extreme caudal border of the mandible (Figure G).

23- Mental foramen to diastema: from the mental foramen to the mid-level of the diastema (Figure G).

24- Mental foramen to base of the mandible: from the mental foramen to the mid-level of the ventral border of the mandible (Figure G).

Statistical Analysis: Data was analyzed using Paleontological Statistics Software Excel for Education and Data Analysis. All the measurements were expressed as mean measurements with the standard deviation (Mean \pm SD).

RESULTS AND DISCUSSION

Results

The measurements of the bovine skull are illustrated in table 1.



Figure A: Skull of the Bovine; lateral view.1: Skull length, 2: Nasal length 3: Cranial length.

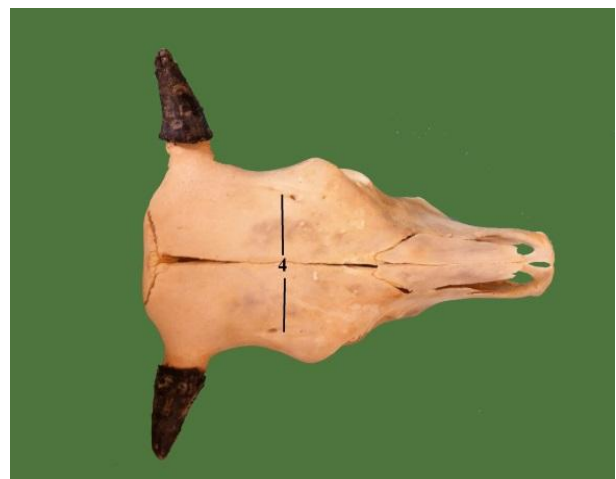

Figure B: Skull of the Bovine; Lateral view. 4- supra-orbital foramen

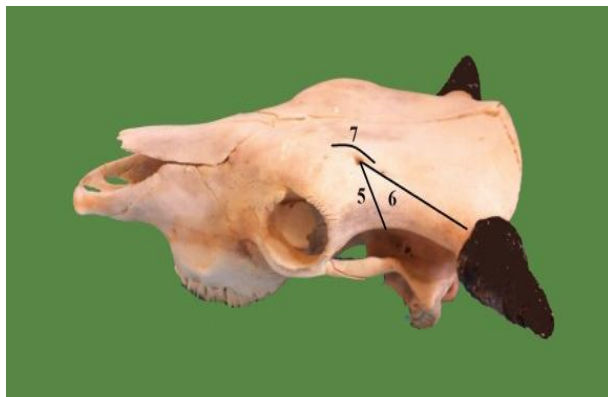


Figure C: Skull of the Bovine; lateral view 4Supra-orbital foramina distance 5-Supra-orbital foramen to external Frontal(temporal line).6-Supra-orbital foramen to horn 7-Supra-orbital groove

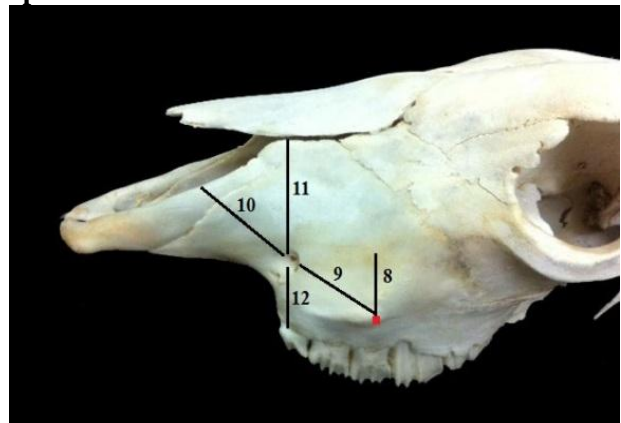


Figure D: Skull of the Bovine; lateral view. 8- the tuber facia to the infra-orbital canal.9- The facial tuber to infra-orbital foramen.10- The infra-orbital foramen tuber to the nasal process of the facial bone 11- The infra-orbital foramen to the nasoincisive notch, 12-The infraorbital foramen to the first upper premolars

Research Article

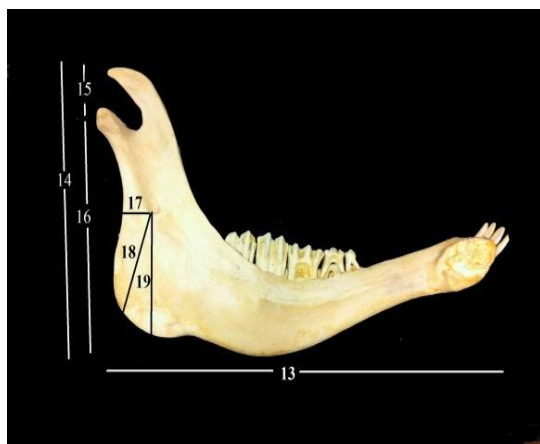


Figure F: mandible of the Bovine; medial View.
 13- Mandibular length, 14-Maximum mandibular height: Maximum mandibular height.15- Coronoid process to condylar process.16- Condylar process to the base of the mandible. 17-Mandibular foramen to the caudal border of mandible. 18- Mandibular foramen to mandibular angle.19-Mandibular foramen to base of mandible

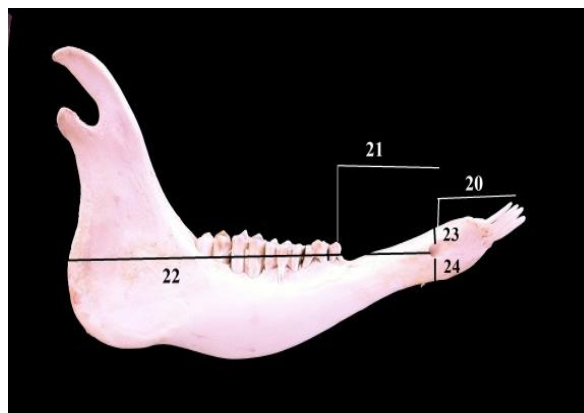


Figure G: mandible of the Bovine; Lateral view.
 20- Lateral alveolar root to mental foramen.21- Mental foramen to the Lateral alveolar root of the first premolar tooth.22- Mental foramen to the caudal mandibular border. 23-Mental foramen to diastema.24- Mental foramen to base of the mandible.

Discussion

The present study carried out that the skull length, nasal and cranial skull lengths in bovine were (51.23 cm, 27.97 cm and 22.72 cm) respectively. Getty (1975) and Dyce *et al.*, (2002) did mentioned the measurement, they just described the skull bones in domestic animals, while Yahaya *et al.*, (2012) and Monfared (2013) mentioned that in camel were 46.2cm, 32.5cm, 13.3cm respectively.

Monfared (2013) recorded in horse were (47.5cm, 21.9cm, 25.6cm) respectively. These results are closed to consideration as large animals and the same size and those animals nearly.

Concerning the distance between the supra-orbital foramen and supra-orbital groove in this study were (13.91cm, 5.07cm, 8.11cm and 7.22 cm).

Literature on distance to this foramen was insufficient and very limited amount of data available to the veterinary searches. Only Allouch (2008) recorded that it was approximately 2/3 the distance extending from the orbit to the base of the horn for horn nerve block in bovine.

Monfared (2013 a,b) mentioned that Greatest width between the supra-orbital foramina was (18.3) cm in camel and about (21.4 cm) in horse while in this study it was 13.91cm.

Its applied importance is to identify the topographic anatomy to perform surgery in the area of the head ophthalmectomy and eyelid droopy as well as dehorning as a result of the increasing growth of the causative to make cuts in the body of animals (Allouch, 2006), palpable ridge running from the zygomatic process back to the horn and serves as a landmark for cornual nerve block. The site for anesthesia is located directly underneath the temporal line halfway between the ear and the eye (Budras *et al.*, 2011).

Insufficient anesthesia may occur due to difficulties in precisely localizing the nerve for anesthesia when it runs deeply in the tissues or because of an abnormal length of the supra-orbital nerves.

In such cases, anesthesia is achieved by subcutaneous infiltration with local anesthetic at the base of the horn.

Research Article

Table 1: Morphometric of the bovine (n = 10)

Morphometric parameter		Mean+ SD
1	Skull length	51.23±2.36
2	Nasal skull length	27.97±3.00
3	Cranial skull length	22.72±1.75
4	Distance supra-orbital foramen	13.91±0.13
5	Supra-orbital foramen to external frontal crest	5.07±1.02
6	Supra-orbital foramen to Horne	8.11±0.79
7	Supra-orbital groove	7.22±0.09
8	facial tuber to infra-orbital canal	2.5±0.25
9	The facial tuber to the infra-orbital foramen	4.78±0.23
10	The infra-orbital foramen to the nasal process of the incisive bone	4.7±0.10
11	The infra-orbital foramen to the nasoincisive notch	5.86±0.40
12	The infra-orbital foramen to the first upper premolars	2.32±0.13
13	Mandible length	38.3±5.81
14	Maximum mandibular height	22.6±1.33
15	Coronoid process to condylar process	5.02±0.73
16	Condylar process to the base of the mandible	19±0.40
17	Mandibular foramen to the Caudal border of mandible	3.81±0.76
18	Mandibular foramen to mandibular angle	8.05±0.77
19	Mandibular foramen to base of mandible.	8.9±0.51
20	Lateral alveolar four incisor to mental foramen	3.71±0.30
21	Mental foramen to the first premolar	6.76±0.53
22	Mental foramen to the caudal mandibular border	32.14±0.99
23	Mental foramen to diastema	1.23±0.20
24	Mental foramen to base of the mandible	2.4±0.32

On the other hand, the results of the study showed the facial tuber to infra-orbital foramen in bovine were 4.78 cm, the distance between the facial tuber and the nasal process of the incisive bone was 4.7 cm and the distance between the infra-orbital foramen to the nasoincisive notch was 5.86 cm. It had been confirmed that the infra-orbital foramen in the skull of bovine was over the alveolar border for the first upper premolar tooth about 2.32 cm, the infra-orbital nerve give off through the foramen (Getty, 1975) in bovine, (Ommer and Harshan, 1995; Dyce *et al.*, 2002) in domestic animals and in camel (Monfared, 2013). On the other hand, the infra-orbital foramen was located Midway between the rostral end of the facial crest and the nasoincisive notch, which is a landmark for a nerve block (Budras *et al.*, 2011). The infra-orbital foramen was located directly dorsal to the upper first premolar tooth in bovine, while was located directly dorsal to the second upper premolar tooth in camel (Monfared, 2013) and located directly dorsal to the third upper premolar tooth in horses (Monfared, 2013). This information would provide a major landmark to regional anesthesia involving the infra-orbital nerve in this region. Therefore, these data can be useful for tracking the infra-orbital nerve and necessary for the desensitization of the skin of

Research Article

nose, nostrils and upper lip; also via alveolar brr. upper teeth and face on that side of the level of the foramen (Ommer and Harshan, 1995). These parameters are of clinical importance as a guide for infra-orbital nerve block necessary for clinical examination and operations on the upper incisor, canine and first two premolars teeth of the upper jaw.

In this study, the bovine mandible length was 38.3cm. This value was the lower from one-humped camel was 39.9cm (Yahaya *et al.*, 2012 and Monfared, 2013), and higher in horse was 28.5cm (Monfared, 2013 a, b).

On the other hand; the maximum mandibular height was 22.6cm, while from the coronoid process to condylar process was 5.02cm, and from the latter to the base of the mandible was 19 cm.

The distances from the mandibular foramen to the caudal border of mandible and from the mandibular foramen to mandibular angle, and from the foramen to the base of mandible were 3.81cm, 8.05cm and 8.9 cm respectively. In bovine these values were higher than camel. They were in camel 3.8 cm, 8.05 cm and 2.6 cm respectively by Yahaya *et al.*, (2012) and Monfared (2013). Moreover, in horse, the distance from the mandibular foramen to the caudal border of mandible was 5.79 cm. It was higher than bovine, while the two other measurements were lower than bovine. They were 5.8 cm and 5.3cm respectively (Monfared, 2013 a, b).

The anesthetic agents must to be injected on the medial side of the mandible, thereby; a successful nerve block produces anesthesia of the lower jaw with its teeth and the lower lip. These informations are necessary for attaining the regional anesthesia of the mandibular nerve and also have clinical importance for desensitization of all the teeth in lower jaw (Hall *et al.*, 2000).

The dimensions mental foramen was 2.71cm, 6.76.4cm, 32.14cm, 1.23cm and 2.4cm respectively. The mental foramen can be felt in the first third space between canine and first premolar externally, moreover; it lies about 2 cm backwards from the mouth angle (Allouch, 2008).

The mental nerve block is indicated for injures suturing of the lower lip, chin and for the operations on the lower incisors and first and second premolars. The information which were registered that the distance between the lateral alveolar of the lower four incisor tooth to the mental foramen was 3.71cm, while Monfared (2013) mentioned that in camel it was 4,74 cm longer than bovine in this study. In horse it was 6.94 cm longer than bovine (Monfared 2013 a, b). In this study; this value was closed to camel, while it was almost multiplier in horse.

There is no data on the morphometric parameters on the bovine head regions to make comparisons with.

Finally, it can be concluded that the morphometric values of the skull in the applied anatomy of the bovine head region are very important for further researches in this field. On the other hand, these results have clinical importance that will help the regional anesthesia of the different nerves in the head especially during ophthalmectomy and eyelid operations as well as dehorning, treating head injury and dental operations.

REFERENCES

- Allouch G (2006).** *Applied Anatomy Textbook*. Veterinary medicine collage, AL Baath University 37-39.
- Allouch G (2008).** Textbook of Comparative anatomy, *The Bones, Ligaments and Joints* 329, 334, 356, 363 -366, 377, Veterinary medicine collage, AL Baath University.
- Andrew K, Edwell SM, Humphrey S and Casanova PM (2014).** Clinical Anatomy of the Head Region of Gwembe Valley Dwarf Goat in Zambia Av. *Alcalde Rovira Roure*, Lleida,Catalunya, Spain **191** E-25198.
- Budras KD, Habel KB, Mülling CHKW and Greenough PR (2011).** *Bovine Anatomy*, 2nd edition, Extended edition, (Schlütersche erlagsgesellschaft mbH & Co.) KG, Hans-Böckler-Allee 7, 30173 Hannover, Germany 34, 40, and 53.
- Budras KD, Habel KB, Mülling CH KW and Greenough PR (2011).** *Horse Anatomy*, 2 edition, Extended edition (Schlütersche erlagsgesellschaft mbH & Co.) KG, Hans-Böckler-Allee 7, 30173 Hannover, Germany 149.

Research Article

- Dyce KM, Sack WO and Wensing CJG (2002).** *Textbook of Veterinary Anatomy*, 3rd edition (WB Saunders Company) Philadelphia.
- Getty R (1975).** *Sisson and Grossman's The Anatomy of the Domestic Animals*, 5th edition (Saunders) Philadelphia ISBN-13 978-0721641027.
- Hall LW, Clarke KW, Trim CM and Wright S (2000).** *Veterinary Anaesthesia and Analgesia*, 10 edition (ELBS and Bailliere Tindall) London.
- Kene ROC and Agbo CN (1998).** Dental abnormalities of three breeds of Nigerian goat. *Tropical Veterinarian* **16** 15- 22.
- Monfared AL, Naji H and Sheibani MT (2013).** Applied Anatomy of the Head Region of the Iranian Native Goats. *Global Veterinaria* **10** 60-64.
- Monfared AL (2013).** Gross Anatomy of the Head Region of the Iranian Native Horse and its Clinical Value During Regional Anesthesia. *Global Veterinaria* **10**(2) 214-218.
- Monfared AL (2013).** Some aspects of clinical anatomy of the head region of the caspian miniature horse and its clinical value during regional anesthesia.
- Monfared AL (2013).** Applied anatomy of the head regions of the one-humped camel and its clinical implications during regional anesthesia.
- Olopade JO (2003).** The Morphometry of the craniofacial and maxillofacial regions of the West African Dwarf Goats (*Capra hircus*). M. Sc. thesis, Department of Veterinary Anatomy, University of Ibadan, Ibadan, Nigeria.
- Olopade JO and Onwuka SK (2005).** Some aspects of the clinical anatomy of the mandibular and maxillofacial regions of the west African dwarf goat in Nigeria. *International Journal of Morphology* **23** 33-36.
- Olopade JO and Onwuka SK (2005).** Morphometric studies of the craniofacial region of the west Africa dwarf goat in Nigeria. *International Journal of Morphology* **22**(2) 145-8.
- Olopade JO and Onwuka SK (2005 b).** Morphometric study of the skull of West African Dwarf Goat in South West Nigeria. *NVJ* **26** 18-21.
- Ommer PA and Harshan KR (1995).** *Applied Domestic Animals*, 1st edition (Jaypee) obtained for early medieval horses in Poland [11] (brother's medical publisher), India.
- Otesile EB and Obasaju MF (1982).** Relationship between age rostral teeth development in Nigerian goats. In: *Proceedings of the 3rd international conference on Goat Production and Disease University of Arizona*. Tucson, Arisona, U.S.
- Radinsky L (1984).** Ontogeny and phylogeny in horse skull evolution. *Evolution* **38** 1-15.
- Simoens RP and Lauwers H (1994).** Morphometric analysis of foramen magnum in pekingese dogs. *American Journal of Veterinary Research* **5** 33-9.
- Yahaya A, Olopade JO, Kwari D and Wiam IM (2012).** Osteometry of the skull of one-humped camels. Part I: immature animals. *Italian Journal of Anatomy and Embryology IJAE* **117**(1) 23-33.