

Research Article

AN ANALYSIS OF CYSTIC FLUID OF *COENURUS GAIGERI* FROM GOAT ORIGIN USING SODIUM DODECYL SULPHATE POLYACRYLAMIDE GEL ELECTROPHORESIS

***Arunkumar S and Prakash Krupakaran R¹**

¹Department of Veterinary Parasitology, Veterinary College and Research Institute, Orathanadu – 614625, Thanjavur (District), Tamil Nadu

²Department of Veterinary Physiology and Biochemistry, Veterinary College and Research Institute, Tirunelveli-627358, Tamil Nadu Veterinary and Animal Sciences University, Chennai-600051

*Author for Correspondence

ABSTRACT

In the present study, *Coenurus gaigeri* cysts (a larval stage of *Taenia gaigeri*) were collected from goats slaughtered at the abattoir in Orathanadu, Thanjavur district, Tamil Nadu. The cysts collected were confirmed to be *Coenurus gaigeri* using their predilection sites, size and morphology. The cysts were washed thoroughly with PBS (pH 7.4) and the fluid from the cyst was aspirated with the help of a sterilized syringe and needle and collected directly in centrifuge tube. It was centrifuged at 10,000 rpm for 15 minutes at 4°C and the supernatants were used for further study. The total protein content of the cystic fluid estimated by Lowry method was 1.54 mg/mL. On Sodium dodecyl sulphate-polyacrylamide gel electrophoresis (SDS-PAGE), two prominent bands at 66 kDa and 43 kDa and three minor bands at 25 kDa, 20 kDa and 14 kDa were observed in the cystic fluid of *Coenurus gaigeri*. Further studies are warranted to identify the immunogenic proteins in cystic fluid, which will be useful for serodiagnosis of *Coenurus gaigeri* infection in goats.

Keywords: *Coenurus gaigeri*, Cystic Fluid, Protein Profile, SDS-PAGE

INTRODUCTION

Coenurus gaigeri, is a larval stage of *Taenia gaigeri* and affects thigh, neck muscle, diaphragm, heart, kidney, uterus, rectum and urinary bladder of domestic goats (Varma and Malviya, 1989; Patro *et al.*, 1997). *Coenurus gaigeri* in goats may reach maturity in organs other than brain and spinal cord. The cysts are mostly seen in intramuscular and subcutaneous tissues of these animals and have worldwide distribution (Soulsby, 1982; Sharma *et al.*, 1995). The occurrence of this metacestode in goats has been reported by different workers in different parts of India (Dey *et al.*, 1988; Sharma and Chauhan, 2006; Madhu *et al.*, 2013). However, the characterization of cystic fluid will help to identify protein profile and further characterization by western blotting, which will be useful to know about the immunogenic proteins in *C. gaigeri*. Hence, the present study was aimed to identify the polypeptide profiles in cystic fluid of *C. gaigeri* in goats.

MATERIALS AND METHODS

The cysts were collected from goats slaughtered at local abattoir in Orathanadu and Thanjavur areas. The cysts collected were confirmed to be *Coenurus gaigeri* using their predilection sites, size and morphology. Mature *C. gaigeri* has a smooth inner surface and contains many scolices. The cysts were washed thoroughly with PBS (pH 7.4) and after careful preservation in PBS, they were used for further processing (Skeurman and Hillard, 1966). The fluid of each cyst was aspirated with the help of a sterilized syringe and needle and collected directly in centrifuge tube. Then, it was centrifuged at 10,000 rpm for 15 minutes at 4°C and the supernatants were collected and stored at -20 °C till further use. The total protein content of the samples was estimated by Lowry method (1951). Each gel well was loaded with 80 µL of cystic fluid sample in 10 % SDS-PAGE under non-reducing conditions at 100 V for 8 hours. The gel was

Research Article

silver stained by the method of Merril *et al.*, (1981). The electro- phoretogram was studied using the protein marker (low molecular weight Genei, Bangalore) in the range of 3.5 to 205 kDa.

RESULTS AND DISCUSSION

In the present study, the total protein concentration of the cystic fluid was 1.54 mg/ mL and SDS-PAGE analysis was carried out in cystic fluid of *C.gaigeri* (Figure 1). On Sodium dodecyl sulphate-polyacrylamide gel electrophoresis (SDS-PAGE), two prominent bands at 66 kDa and 43 kDa and three minor bands at 25 kDa, 20 kDa and 14 kDa were observed in the cystic fluid of *Coenurus gaigeri*. Arunkumar *et al.*, (2014) reported that three prominent bands ranging from 60 kDa to 10 kDa (60, 20 and 10 kDa) and three minor bands at 200 kDa, 47 kDa and 35 kDa in *Cysticercus tenuicollis* fluid. Among the prominent bands, the intensity was stronger in 60 kDa followed by 10 and 20 kDa and the lower bands were not sharper and found diffused. A band at 200 kDa was very faint among all the other bands. The intensities of low molecular weight prominent bands were weaker and the separation was not very discrete suggesting the presence of non -proteinaceous complex nature of these proteins. Protein bands with the molecular weights ranging from 13 to 120 kDa were observed in cystic fluid of *C. gaigeri* of goat. A sharp band at 66 kDa level was also reported in the fluid (Koradafshari *et al.*, 2010). Similar results were observed in the present study. However, the slight variations in the relative molecular weights of the polypeptides may be due to the influx of season on the reproductive cycle of parasite and the geographical location of the parasite. Further studies are warranted to identify the immunogenic proteins in cystic fluid, which will be useful for serodiagnosis of *C. gaigeri* infection in goats.

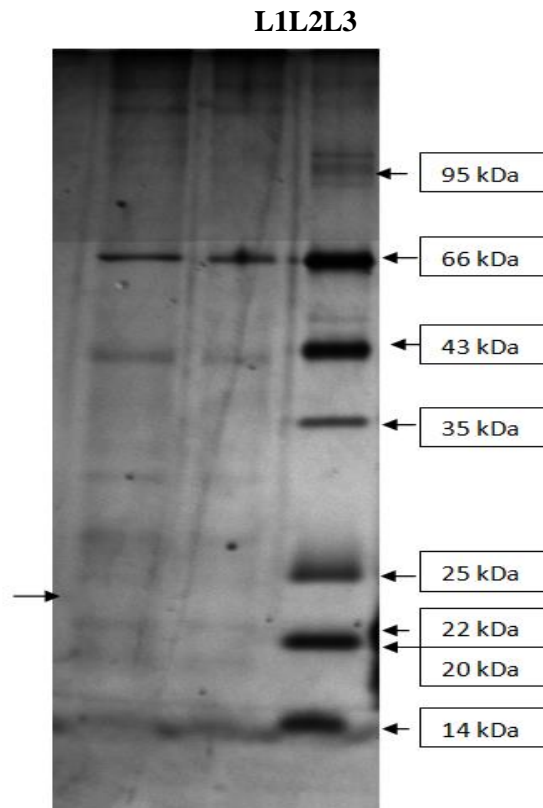


Figure 1: SDS-PAGE Analysis of E/S Antigens of *Coenurus gaigeri* (Silver Staining)

Lane 1: E/S Antigens of *C.gaigeri* (10 microliters)

Lane 2: E/S Antigens of *C. gaigeri* (5 microliters)

Lane 3: Mid Range Protein Marker

Research Article

REFERENCES

- Arunkumar S, Prakash Krupakaran R, Balamurugan TC and Pandian DV (2014).** Electro-phoretic analysis of cystic fluid proteins of *Cysticercus tenuicollis* from goats. *CIBTech Journal of Microbiology* **3**(4) 52-54.
- Dey PC, Nayak DC, Mohanty DN, Nayak S and Patnaik GM (1988).** A brief note on massive infection of *Coenurus gaigeri* cysts in a desi goat. *Indian Veterinary Journal* **65** 165-166.
- Laemmli UK (1970).** Cleavage of structural proteins during the assembly of the head of bacteriophage T4. *Nature* **227** 680-685.
- Lowry OH, Rosebrough NJ, Farr AL and Randall RJ (1951).** Protein measurement with the folin phenol reagent. *The Journal of Biological Chemistry* **193**(1) 265-275.
- Madhu DN, Tamil Mahan V, Sudhakar NR, Maurya PS and Pawde AM (2013).** *Coenurus gaigeri* cyst in the thigh of a goat and its successful management. *Journal of Parasitic Diseases* **13** 242-244.
- Merril CR, Godman D, Sedman SA and Ebert MH (1981).** Ultrasensitive stain for proteins in poly acrylamide gels show regional variation in cerebrospinal fluid proteins. *Science* **211** 1437-1438.
- Patro DN, Suhani B, Sahoo DK, Nanda SK, Pradhan PK and Nayak BC (1997).** Incidence of generalized *Coenurus gaigeri* infection in a goat farm. *Indian Veterinary Journal* **74** 68-69.
- Sharma DK, Sanil NK, Agnihotri MK and Singh N (1995).** Subcutaneous coenurosis in Barbary goat. *Indian Veterinary Journal* **72** 217-218.
- Sharma DK and Chauhan PPS (2006).** Coenurosis status in Afro-Asian region: a review. *Small Ruminant Research* **64** 197-202.
- Skeurman KD and Hillard JJ (1966).** *A Handbook for Studies of Helminth Parasites of Ruminants.* Near east animal health institute Hand book no. 2, (FAO of the United Nations, Beirut, Lebanon).
- Soulsby EJJ (1982).** *Helminths, Arthropods and Protozoa of Domesticated Animals*, 7th edition, (The English Language Book Society and Bailliere Tindall, London, UK) 117-118.
- Varma TK and Malviya HC (1989).** Prevalence of coenurosis in sheep, goat and pig in Bareilly, Uttar Pradesh. *Journal of Veterinary Parasitology* **3** 69-71.