

Research Article

MACROSCOPIC AND MICROSCOPIC STUDY OF TONGUE IN WISTAR RATS

Ghazale Cheshmi and *Frangis Ghassemi

Department of Biology, Jahrom branch, Islamic Azad University, Jahrom, Iran

**Author for Correspondence*

ABSTRACT

The aim of the present study was to investigate the structure of the tongue in rat since tongue is an important organ in taking food. For this purpose, the tongue of 8 adult male and 8 female rats (wistar) was dissected from the root. Their weight, length and wide were measured. Then, they were fixed in formalin (10%) and prepared by tissue processing (fixation, dehydrated, clearing and impregnation). The serial sections (5 μ) were obtained and subjected to Haematoxylin and Eosin stains. The morphology and morphometric study of the tongue were studied by light microscope and progress capture soft ware. The results showed that the epithelium of muscular tongue in male and females were keratinized stratified squamous. Its length and width in both sexes were similar approximately with 2.67 ± 0.02 cm and width of its apex, body and root were 0.58, 0.66 and 1.2 cm respectively. Deep median sulcus was seen on midline of tongue and four types of lingual papillae with different distribution and density were observed on its dorsal surface. Filiform papillae with the highest density and distribution were whole of tongue, a few fungi form. p with taste buds were on midlateral and two circumvallate with many taste buds were on posterior of tongue mucous and serous glands were in ventral surface of tongue. The results showed that the morphology and structure of tongue in both sexes are similar and related to diet pattern.

Key Words: *Papillae, Taste Bud, Diet*

INTRODUCTION

The morphology and microscopic structure of the tongue was investigated in vertebrates (Igbokwe and Okolie, 2009; Ebru *et al.*, 2010) and many rodents as mouse (Iwasaki *et al.*, 1996; Carrard *et al.*, 2008), rat (Iwasaki *et al.*, 1999; Nasr *et al.*, 2012), mice (Kobayashi *et al.*, 1990; Iwasaki *et al.*, 1999) and rabbit (Silva *et al.*, 200; Nonaka *et al.*, 2008).

The tongue is muscular organ with three layers including mucosa, submucosa and muscularis. Mucosa is covered by pseudostratified squamous epithelium with variation in the keratinization. Six types of the lingual papillae with different density and distribution were known in mammals (Agungpriyono *et al.*, 1995; Jackowiak and Godynicki, 2007). These papillae are divided to mechanical (Filiform.P, fungiform.P, conical.P) and gustatory papillae (vallate.P, foliate.P, lentiform.P).

Filiform papillae are needle shape and they were oriented to pharynx. They were divided to three distinct types as type I which are needle like and covered with thin keratinized stratified squamous epithelium and they were located on apex and anterior of body (Jwasakis, 2002). The bifid or trifled filiform papillae (type II, III) were shorter and thicker than type 1, and placed on posterior area (Nasr *et al.*, 2012).

Fungiform.P less than filiform.P and are on the apex of the tongue (Igbokwe and Okolie, 2009). These papillae In addition mechanical function, are gustatory duo to have a taste bud which is on their conical surface. Lamina propria like too many mammals is thin in filliform.P and very thick in fungiform.P (Topark, 2006).

The purpose of this study was to determine anatomy of tongue especially lingual papillae on light microscopy in female and male rat (wistar) and compared in both sexes.

MATERIALS AND METHODS

The tongue of 8 adult male and female rats (Wistar) was dissected from the root. Their weight, length and wide were measured. Then, they were fixed in neutral buffered formalin (10%) for 48 hours and prepared

Research Article

by tissue processing (dehydrated with alcohol 70 – 100%, clearing by xylol and paraffin impregnation. The serial sections (5 µm) were obtained by microtome and subjected to Haematoxylin and Eosin stains. The morphology and morphometric study of the tongue were studied by light microscope and progress capture soft ware.

RESULTS AND DISCUSSION

Results

The tongue of wistar rat in both sexes was composed of three layers as follows:

Mucosa was covered by stratified squamous epithelium and thick keratin, thick submucosa with blood vessels and glands (almost serouse) and thick muscularis layer (Figure 1). The tip of the tongue is flat with a deep median sulcus on dorsum and three parts (apex, body and root) were distinguished (Figure 2). Length and width of these pares were different (Table 1). Frenulum was from apex to posterior of body.

Table 1: Comparatives characteristic of tongue in female and male of rat (wistar)

Parameter	Female	Male
mean of length	2.65 Cm	2.69 Cm
mean of width (Apex)	.058 Cm	.058 Cm
mean of Width (Body)	0.69 Cm	0.64 Cm
mean of width (Root)	1.00 Cm	1.20 Cm

Table 2: Comparatives characteristic of lingual papillae in female and male of rat (wistar)

Female	Male	Size (mm)	Density	Distribution	Papillae
0.310	0.261	Altitude	low	Apex, midlateral	Fungiform. P
0.150	0.160	width			
0.310	0.333	Altitude	High	Whole of dorsum	Filiform. P
0.131	0.114	width			
0.811	0.761	Altitude	1 number	Posterior of body	Vallate. P
3/83	3/20	width			

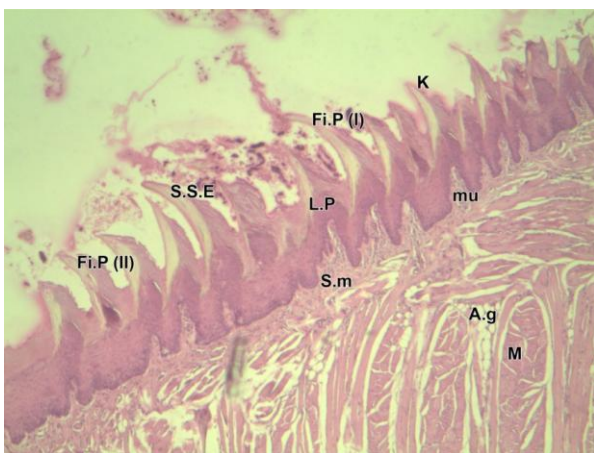


Figure 1: Apex of tongue in male Rat (wistar) (10x- H&E) Stratified squamose epithelium (S.S.E); lamina propria (L.P); muscle bundle (M); keratin (K); mucosa (mu); submucosa (S.m); vessel (V); **filiform papilla (Fi.P1, 2)**; adipose gland (A.g),

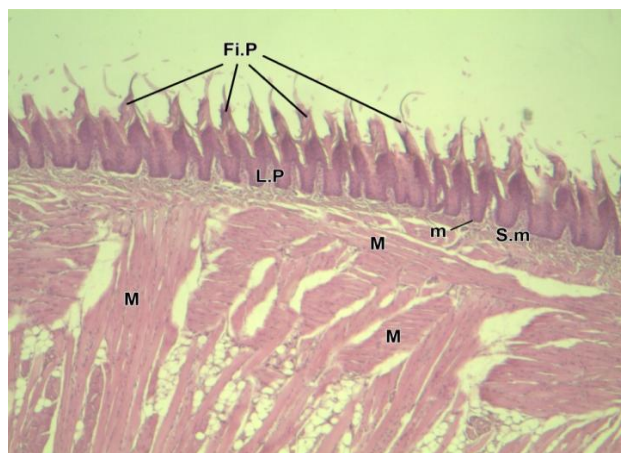


Figure 2: Apex of tongue in female Rat (wistar) (10x- H&E) stratified squamous; **filiform papilla (Fi.P)**; lamina propria (L.P); mucosa (m); submucosa(S.m); muscle bundle (M)

Research Article

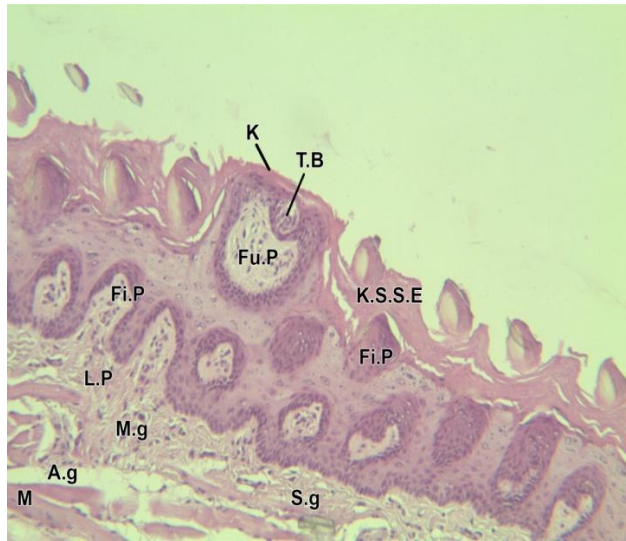


Figure 3: Body of tongue in male Rat (wistar) 10x- Keratinized stratified squamous epithelium (H&E) (K.S.S.E); lamina propria(L.P); **fungi form papillae (Fu.P)**; taste buds (T.B); muscle fibres (M); keratin (K); filiform. papillae (Fi.P); mucus gland (M.g); serouse gland (S.g)

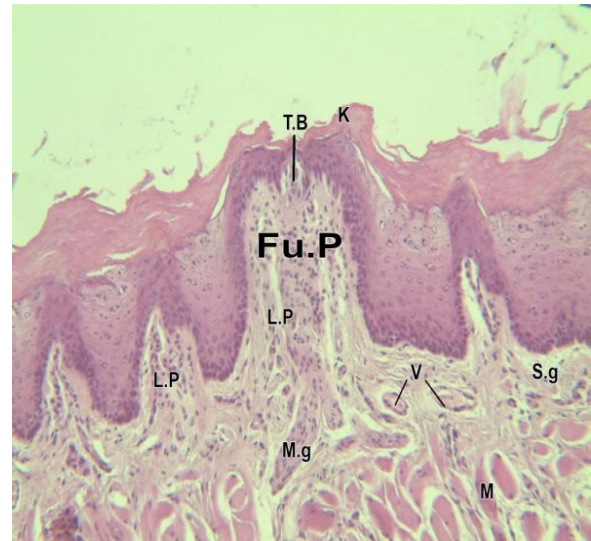


Figure 4: Apex of tongue in Female Rat (wistar) (10x- H&E) lamina propria (L.P); **fungi form papillae (Fu.P)**; taste buds (T.B); muscle fibres (M); keratin (K); vessel (V); mucus gland (M.g); serouse gland (S.g)

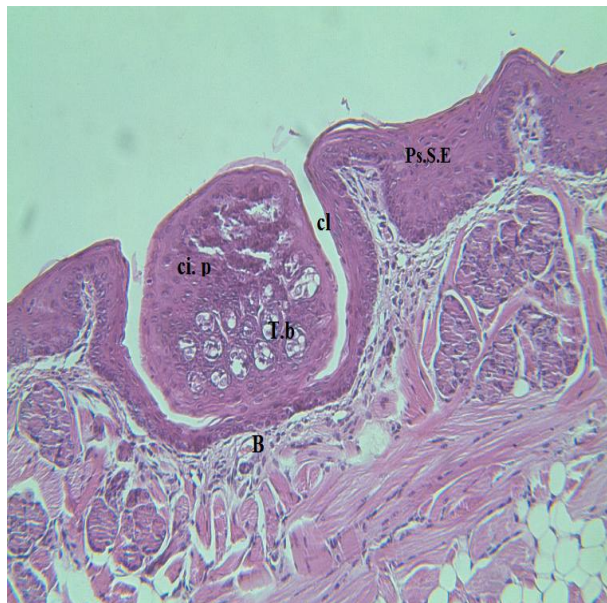

Figure 5: posterior of tongue in male Rat (wistar) (10x- H&E) **Circumvallate papillae (ci, p)**; taste buds (t.b); blood vessel (B); Cleft(Cl); pseudostratified squamous epithelium (Ps.S.E)

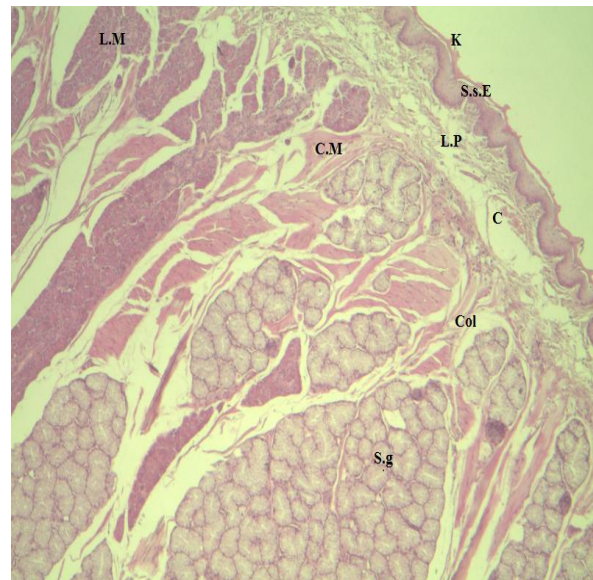


Figure 6: posterior of tongue in male Rat (wistar) (10x- H&E) stratified squamous epithelium (S.S.E); lamina propria(L.P); circular muscle (C.M); longitudinal muscle (L.M); keratin (K); **collagenous fiber (col)**; serouse gland (S.g)

Three types of papillae include filiform, fungi form, and circumvallate papillae were observed on the dorsum (Igbokwe and Okolie, 2009). The density and distribution of papillae were different and decreased from the apex to root of tongue (Table 2).

Research Article

Filiform papillae have a pointed needle shape with high density were placed in the anteriolateral of the tongue and their orientation forward to pharynx (Figure 1, 3).

Fungiform papillae less than filiform papillae and were on the tongue apex (Figure 4). These papillae have mechanical and gustatory function because they have one taste bud which is on their conical surface. In this study, foliate papillae were not observed on the contrary (Taiwo *et al.*, 2009).

The one circumvallate papillae is suited on front of root. This was observed without microscope and was seen as papillae which surrounded by narrow canal in cross section (Figure 5).

Epithelium and keratin in ventral surface were thinner than dorsal surface. Many glands (serous and mucous gland), thick lamina propria and more muscular mass (circular and longitudinal) were observed in this surface. The most of muscle were transverse bundle and longitudinal bundle were between them (Figure).

Colagenous fiber was in front and many lymphoid cells in posterior of tongue.

Discussion

In present study, anatomy of tongue especially lingual papillae was observed with light microscope and compared in female and male rat (wistar).

According previous study (Iwasaki *et al.*, 1999; Nonaka *et al.*, 2008), stratified squamous epithelium and thick keratin on filiform.P was necessary for protection against damage due to taking hard food.

Observation of different types of papillae on dorsal surface of tongue in male and female rat (wistar) suggests that their tongue is specialized for digestion. Filiform.P has a similar structure and localization as those of rats and mice (Kobayashi *et al.*, 1990; Toprak, 2006). Since rat (wistar) and mice are similar in food source, this result is expected.

Long and biforked filiform.P which were placed in the apex, aid to take food particles and orientation of them (toward to posterior) facilitate swallowing (Jackowiak and Godinicki, 2005). The distribution, structure and morphology of these papillae were adapted to gallinaceous diet. Although these papillae were on the whole of dorsal surface of tongue but high density of them was on apex and decrease to posterior are. This finding was unlike previous finding about mice's tongue (Taiwo *et al.*, 2009).

Although foliate papillae were observed on tongue in some vertebrates (Jackowiak, 2006; Emura *et al.*, 2004) and were seen on the lateral surface of the rat's tongue (Taiwo *et al.*, 2009) but in this survey, it wasn't seen. Further research is suggested about these papillae.

Gustatory papillae include fungi form and circumvallate papillae because they have taste bud. Despite fungi form. P have mechanical role in some vertebrates (Benetti *et al.*, 2009) but obtained results showed that they have both roles (gustatory and mechanical) in this species. Presence obvious keratin on the surface and a few taste buds (one) in these papillae showed that their mechanical role is preferable (Figure 3, 4). The number of taste bud is vary in mammals and placed on conical surface (Benetti *et al.*, 2009).

The one circumvallate papillae is suited front of root (Kobayashi *et al.*, 2004). These papillae have many taste buds in lateral walls epithelium and tubular canal is around it (Mistretta and Baum, 1984). The serous and mucous gland which was in submucosa and related to taste buds via its canal and aid to gustatory (Figure 5) these papillae is oval and big as seen without microscope (Figure 6).

Thick epithelium and keratin in dorsal surface especially on apex and filiform papillae are useful for contacting hard food. Although the oral epithelium covered by keratin in all of mammals but keratinization is variable and related to their diets (Kobayashi *et al.*, 2004).

Thick lamina propria with blood vessel and collagenous fiber supported mucosa well (Figure). Density of muscle and collagen aid to movement of tongue and mastication. A few vessels in lamina propria This may be relate to low absorption in oral cavity. Because food consumed by rat is hard and is not digested in the mouth (Ofusori *et al.*, 2008). On the other presence of taste buds in fungi form and Vallate papillae confirm to begging of food digestion. Presense of fungiform.P on epithelium of apex aid to take food whereas this papillae almost pleased on middle or posterior of tongue (Silva *et al.*, 2002; Yoshimura *et al.*, 2008). Its taste bud (one) were exposed to food, masticated and facilitated to swallow food particles (Taiwo *et al.*, 2009).

Research Article

Conclusion

Obtained results showed that morphology and microscopic anatomy of tongue are similar in both sexes of rat (Wistar). Their structural specifications are taxonomic and adaptations to their feeding patterns.

ACKNOWLEDGMENT

We would like to thank authorities of Islamic Azad University, Jahrom branch, to assist this project.

REFERENCES

- Agungpriyono S, Yamada J and Kitamura N et al., (1995).** Morphology of the dorsal lingual papillae in the lesser mouse deer, *Tragulus javanicus*. *Journal of Anatomy* **187** 635–640.
- Benetti EJ, Pícoli LC, Guimarães JP and Motoyama et al., (2009).** Characteristics of filiform, fungi form and Vallate papillae and surface of interface epithelium-connective tissue of the maned sloth tongue mucosa (*Bradypus torquatus*, Illiger, 1811): Light and Scanning Electron Microscopy Study. *Anatomy Histology and Embryology Journal* **38**(1) 42- 48.
- Carrard VC, Pires AS and Badauy CM et al., (2008).** Effects of aging on mouse tongue epithelium focusing on cell proliferation rate and morphological aspects, *Bulletin of Tokyo Dental College* **49**(4) 199-205.
- Ebru KS, Melek KH and Ismail SH (2010).** Characteristics of dorsal lingual papillae of Zavot cattle. *Journal of Animal and Veterinary Advances* **9** 123-130.
- Emura S, Hayakawa D and Chen H et al., (2004).** Morphology of the lingual papillae in the tiger. *Okajimas Folia Anatomica Japonica* **81** 39–44.
- Iwasaki S, Yoshizawa H and Kawahara I (1999).** Ultrastructure study of the relationship between the morphogenesis of filiform papillae and the keratinization of the lingual epithelium in the rat. *Journal of Anatomy* **195** 27-38.
- Jackowiak H (2006).** Scanning electron microscopy study of the lingual papillae in the European Mole (*Talpa europea*, L., Talpidae). *Anatomia, Histologia, Embryologia* **35** 190–195.
- Jackowiak H and Godynicki S (2007).** Thescanning electron observations on the structure of the lingual papillae of the feathertail glider, *Acrobates pygmeus*, Burramyidae.
- Jackowiak H, Trzcielińska-Lorych J and Godynicki S (2009).** The microstructure of lingual papillae in the Egyptian fruit bat (*Rousettus aegyptiacus*) as observed by light microscopy and scanning electron microscopy. *Archives of Histology and Cytology* **72**(1) 13-21.
- Kobayashi K, Kumakura M, Yoshimura K and Takahashi et al., (2004).** Comparative morphological studies on the stereo structure of the lingual papillae of selected primates using scanning electron microscopy. *Ann. Anat.* ,186 : 525-530.
- Igbokwe CO and Okolie C (2009).** The Morphological Observations of Some Lingual Papillae in the Prenatal and Prepuberal Stages of Red Sokoto Goats (*Capra hircus*). *International Journal of Morphology* **27**(1) 145-150.
- Iwasaki S (2002).** Evolution of the structure and function of the vertebrate tongue. *Anat* **201** 1–13.
- Iwasaki S, Yoshizawa H and Kawahara I (1999).** Ultrastructure study of the relationship between the morphogenesis of filiform papillae and the keratinization of the lingual epithelium in the rat. *Journal of Anatomy* **195** 27-38.
- Jwasakis A (2002).** Evolution of the structure and function of the vertebrate tongue. *Journal of Anatomy* **201**(1) 1-13.
- Nasr ES, Gamal AM and Elsheikh EH (2012).** Light and scanning electron microscopic study of the dorsal lingual papillae of the rat *Arvicanthis niloticus* (Muridae, Rodentia). *Journal of American Science* **8**(4).
- Mistretta CM and Baum JB (1984).** Quantitive study of taste buds in fungiform and circumvallate papillae of young and aged rats. *Journal of Anatomy* **138**(2) 323-332.

Research Article

Nonaka K, Zheng J and Kobayashi K (2008). Comparative morphological study on the lingual papillae and their connective tissue cores in rabbits. *Okajimas Folia Anatomica Japonica* **85** 57-66.

Ofusori DA, Enaibe BU, Falana BA, Adeeyo OA, Yusuf UA and Ajayi SAA (2008). comparative morphometric analysis of the stomach in *Rat Rattus norvegicus*, *Bat Eidolon helvum* and *Pangolin Manis tricuspis*. *Journal of Cell and Animal Biology* **2**(3) 79-83.

Silva MCP, Watanabe I and Kronka MC (2002). Three-dimensional architecture of the connective tissue core and surface structure of the lingual papillae in the rabbit. *Histology and Histopathology* **17** 455-461.

Taiwo A, Abayomi D, Ofusorti O and Ayoka A (2009). A comparative histological Study of the tongue of Rat, Bat and pangolin. *International Journal of Morphology* **27** 1111-1119.

Toprak B (2006). Light and scanning microscopic structure of filiform papillae in mice. *Veterinarski Arhiv* **76** 555-562.

Yoshimura K, Hama N, Shindo J, Kobayashi K and Kageyama N (2008). Light and scanning electron microscopic study on the lingual papillae and their connective tissue cores of the Cape hyrax *Procavia capensis*, *Journal of Anatomy* **213**(5) 573-582.