

**Research Article**

## **NASAL GLIAL HETEROTOPIA: A RARE BENIGN NERVOUSTUMOR: A CASE REPORT AND LITERATURE REVIEW**

**\*Megha Gupta, Utsav Joshi, Narayani Joshi, B.P. Nag and Sushma Bohra**

*Department of Pathology, Mahatma Gandhi University of Medical Sciences and Technology, Sitapura, Jaipur*

*\*Author for Correspondence*

### **ABSTRACT**

Glial Heterotopias are rare, benign congenital midline teratomatous extra cranial glial tissue. Here in we present a case of nasal glial heterotopia in an 8-month-old female child and literature review.

**Keywords:** *Nasal Glial Heterotopia, Nasal Glioma, Nasal Mass, Immunohistochemistry, GFAP, S-100, EMA*

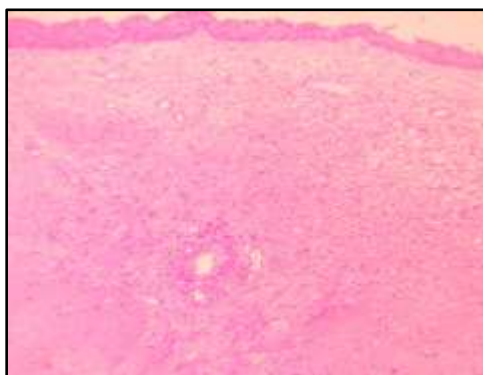
### **INTRODUCTION**

Heterotopia is a condition where microscopically normal cells or tissues are identified in an abnormal location (Chawla et al., 2011). Glial Heterotopias are congenital (often midline) developmental, non-neoplastic, displacement of neuroglial tissue in extra cranial sites without connection to the cranial cavity (Bruce, 2008). Most of these are benign found in nasal region, particularly at the bridge of the nose and nasal cavity. Nasal glial heterotopia is frequently diagnosed in newborns; a few cases have also been reported in adults (Penner and Thompsons 2003)

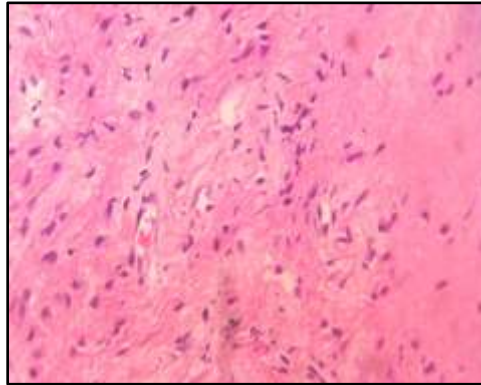
### **CASES**

An 8-month-old female child presented in the ENT outpatient department with a mass in the nasal cavity present since birth. It was gradually increasing in size. Her parents also gave the history of running nose. No history of epistaxis, trauma, nasal obstruction or allergic rhinitis was present. On general examination, child was playful and haemodynamically stable.

On ENT examination, there was no abnormality in the ears but a firm, non-pulsatile mass was located in the left nasal cavity without changes on the overlying skin. On probe test, the probe could not be reached posteriorly and laterally in the left nasal cavity. A clinical diagnosis of turbinate hypertrophy was made. On CT scan of PNS, there was a 20x17x12 mm sized well defined round to oval non-enhancing lesion was seen in the left nasal cavity in the close proximation of nasal septum causing expansion of nasal cavity, deviation of the nasal septum to the right side and elevation of the nasal bone, findings suggestive of benign nasal lesion.

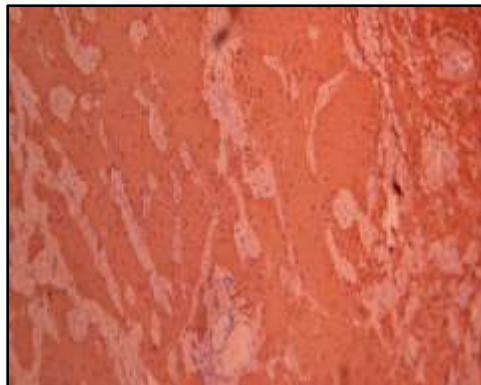

**Figure 1: 4X: HandE Stained sections of the tissue showing that the mass is covered with respiratory epithelium and the underlying stroma is suggestive of benign spindle cells**

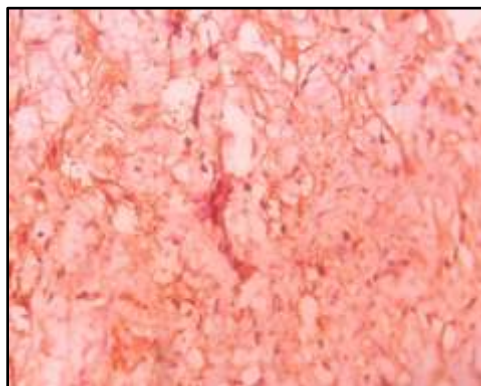


**Figure 2: 40X: HandE Stained section of the tissue showing the underlying stroma suggestive of glial tissue. Neuroglia fibres intermixed with a fibrous connective tissue stroma**

The patient was operated for the nasal mass and the tissue was sent to the department of pathology. Gross examination revealed a single soft tissue mass measuring 1x1x1.5 cm in size. On histological examination, the mass was lined by respiratory epithelium, with a fine fibrillary stromal tissue in the sub-epithelial region that was glial tissue and ependymal element was seen (Figure 1 and Figure 2).

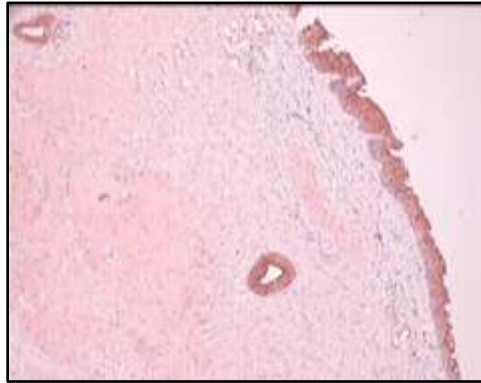


**Figure 3: 10X: GFAP: Staining positive for the glial islands**



**Figure 4: 40X: S-100: positive for glial tissue**

The diagnosis of nasal glial heterotopia was given. The diagnosis was confirmed by immunohistochemistry for glial fibrillary acidic protein (GFAP) and S-100, which was positive (Figure 3 and Figure 4).



**Figure 5: 4X: EMA: Staining positive for the Respiratory Epithelium and the cells lining the rudimentary endymal canals**

Ependymal element on immunohistochemistry stained positive for epithelial membrane antigen (EMA) (Figure 5).

## DISCUSSION

The medical literature characterizes nasal glial heterotopia as being congenital mass presenting in the first year of life (Penner and Thompsons 2003). Shwetha and Subbarao (2013) reported a case of nasopharyngeal glial heterotopia in an 8 month old male baby similar to the age presentation in our case. Neuroglialheterotopia have been described in various sites with nose and nasopharynx being the commonest (Shwetha and Subbarao, 2013).

Intracranial glial heterotopia can prove quite challenging because of the clinical presentation may not immediately bring diagnosis to the forefront of the differential diagnosis (Penner and Thompsons 2003). Glial tissue in nose can be extra nasal (60%), intranasal (30%) and mixed (10%) (Krishna *et al.*, 2005).

The term “Nasal Glioma” is a confusing misnomer as it implies a neoplastic condition, which is not. It needs to be differentiated from glioma, which is a malignant tumor of brain. Clinically these masses are firm in consistency, non-compressible, non-pulsatile greyish or purple lesions. These masses can protrude through the nostrils and can be confused with nasal polyps (Salati and Rather, 2011). CT scan or MRI forms the mainstay of investigations in glial heterotopia to rule out the intracranial communication. In the present case there was no intracranial connection.

Two cases of glial heterotopia were reported by Ramadass *et al.*, (2011) one of which was in left nasal cavity, diagnosed histopathologically and further confirmed by immunohistochemistry. They also stressed the importance of CT scan and MRI in the diagnosis of the lesions.

Nasal obstruction is the main complain in nasal glial heterotopia (Penner and Thompsons 2003; Shwetha and Subbarao, 2013). Nasal glial heterotopia should be differentiated from encephalocele (Ramadass *et al.*, 2011). The differentiation of nasal glial heterotopia from encephalocele is based on the presence of a connection between mass and intracranial tissue (Penner and Thompsons 2003). Histopathology and immunohistochemistry helped in clinching the diagnosis. Hence, in this case merit documentation.

## REFERENCES

- Bruce M Weing (2008).** Non- neoplastic lesions of the nasal cavity and paranasal sinuses. In: *Atlas of Head and Neck Pathology*, edited by Bruce M Weing, 2<sup>nd</sup> edition (Elsevier Health Sciences) 20-22.
- Carla R Penner and Lester DR Thompsons (2003).** Glial Heterotopia: A clinicopathological and immunophenotypic Analysis of 10 cases, with review of literature. *Annals of Diagnostic Pathology* 7(6) 354-359.
- Chawla N, Kishore S, Kudesia S and Kalia RB (2011).** Glandular heterotopia of the neck of femur. *Indian Journal of Pathology and Microbiology* 54 189-90.

**Research Article**

**Kamath S and Subbaro KC (2013).** Nasopharyngeal glial heterotopia: A rare cause of airway obstruction in an infant. *Indian Journal of Pathology and Microbiology* **56**(1).

**Krishna LG, Uppoor R, Rao KN and Harish K (2005).** Heterotopic central nervous tissue – nasal glioma: A case report. *Indian Journal of Radiology and Imaging* **15** 511-6.

**Ramadass T, Narayanan N, Rao P and Parameshwaran A (2011).** Glial Heterotopia in ENT – Two case reports and review of literature. *Indian Journal of Otolaryngology and Head and Neck Surgery* **63**(4) 407-410.

**Salati SA and Rather AA (2011).** Congenital Intranasal Glioma: A case report. *Case Reports in Surgery* (Hindawi Publishing Corporation) 1-3.