

Case Report

FOURNIER'S GANGRENE-A CASE REPORT

***Narayan Reddy B.¹, Kumar Krishna Mohan² and Naveen P.²**

¹*Department of Dermatology and DVL, MediCiti Institute of Medical Sciences, Ghanpur, RR District, Telangana State*

²*Oxygen Hospitals, Alwal, Hyderabad*

**Author for Correspondence*

ABSTRACT

Though Fourniers gangrene is not uncommon, it is fulminant, usually a localized disease involving scrotum and penis, which may also reach up to the abdominal wall. The usual organism found is anaerobic streptococcus synergistic with other organisms. With a focus of infection in the body like candidial balano-posthitis and co-morbid condition like Diabetes will help in the rapid spread of gangrene after compromisation of vascularity to the tissues. An early diagnosis including evaluation of predisposing cause its and etiological factors also metabolic and physiological parameters with timely resuscitation with surgical debridement, broad-spectrum antibiotic coverage, and continuous monitoring is essential for a good outcome, therefore reducing mortality and morbidity of this condition. In this study, we report a case of a young, diabetic, without any multiorgan failure was managed successfully with good outcome.

Keywords: *Fourniers Gangrene, Necrotizing Fascitis, Candidial Balano-Posthitis, Diabetes Mellitus*

INTRODUCTION

Fourniers gangrene or Necrotizing fascitis was identified by a French Venereologist in 1883. Paty and co-workers reported prevalence of 1 in 7500 persons (Paty and Smith, 1992).

Other researchers have reported approximately 600 cases of Fourniers gangrene in the world literature since 1996 (Ayumba and Magoha, 1998). Most reported cases occur in patients between 30-60 years of age group. The male: female ratio approximately is 10:1.

Fourniers gangrene is not confined to any particular region, although the largest clinical series reported are from Africa (Ayumba and Magoha, 1998).

Fournier's gangrene (FG) a rapidly progressive gangrene of the scrotum and penis extending into surrounding areas rapidly if early diagnosis and intervention is delayed. It is a serious surgical emergency. FG is described as necrotizing soft tissue infections originating from or limited to the genitalia or perineum irrespective of sex.

Fournier reviews the systemic and local factors that influence this fulminate process. Local factors related to the trauma of the genitalia accounted for a vast majority of the cases of genital gangrene. Diabetes was known as the leading predisposing systemic factor.

CASES

A 35 years married, male patient, realtor from local urban area came to our OP with pain and ulceration of the tip of the penis for the last one day duration. He was asymptomatic till yesterday, no history of extramarital contact or injury. He is married, has 2 children. There was no history of Diabetes and white discharge in the spouse.

On examination, moderately built, no abnormal growth or discharge per urethra, prepuce is swollen with vertical fissures all around the prepuce orifice (Figure-1). A provisional diagnosis of Candidial balanoposthitis was made. Prescribed Fluconazole 150 mg. Azithromycin 500 mg. PO and topical Clotrimazole cream Tab. Ibuprofen an analgesic and anti inflammatory was given and advised to come back with routine investigations and STD profile reports.

Case Report

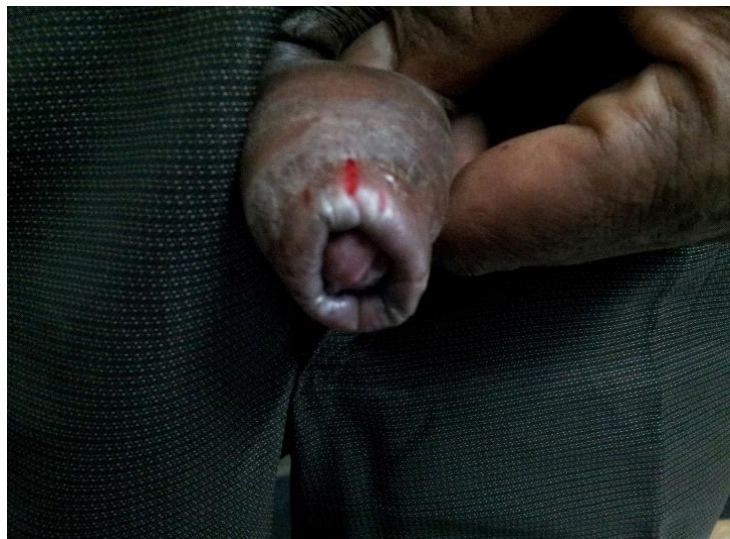

Figure 1: Penis with swollen prepuce with vertical fissures all around the prepucial orifice

Next day he presented with swelling of shaft of the penis with dusky, red colored blisters, some oozing with foul smelling discharge and on palpation bullae was flaccid, crepitus was present. Patient was looking toxic. He was not able to pass urine so foley's catheter was introduced (figure-2), and pain reduced so also tenderness. No lymphadenopathy was observed. On examination tachycardia of 110 per minute, BP 100/60 mm Hg, Respiratory rate was 26/min, Temperature was 102°F. Heart & Lungs, no abnormality was noted, Abdomen was soft, no organomegaly.

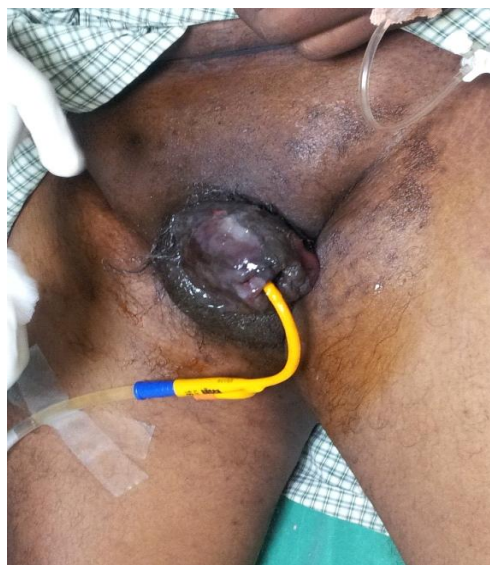

Figure 2: Shaft of the penis dusky, red colored blisters with Foley's catheter

Admitted in the intensive care unit as he was ill looking, there was raised random blood sugar level of 338 mg/ml, leukocytosis of 18,000cells/ml other parameters like serum electrolytes, LFT, RFT, blood gases were normal. Fluid from the lesions; Urine and the blood was sent for C/S. Insulin, oxygen, IV fluids were started, Lanzolid, Amikacin, Metronidazole IV given. With investigation it was found to be associated co-morbid condition of Diabetes mellitus and typical clinical presentation, made us to diagnose Fournier's gangrene. Referred to Urologist for further evaluation. (Figure 3)

Case Report

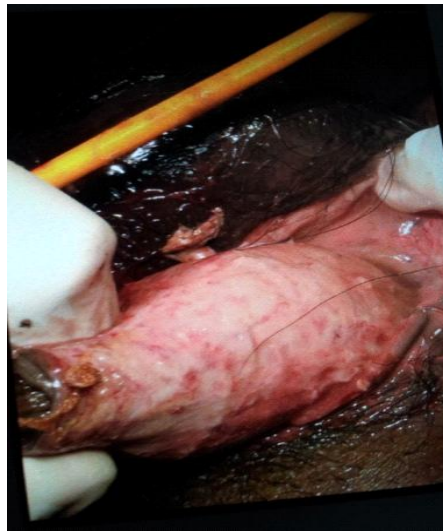

Figure 3: Excision of penile skin

After the case was referred to urologist, excision of gangrenous tissues was done under general anesthesia in two sittings. Necrotic tissues were sent for biopsy. Intra and post-operative periods were uneventful. Patient recovered and received treatment to control diabetes. HPE of excised tissue shows necrosis, fibrinoid thrombosis of nutrient vessels, polymorphonuclear cell infiltration with microorganisms identified in the involved tissues which are in favor of Fournier's gangrene (Figure-4).

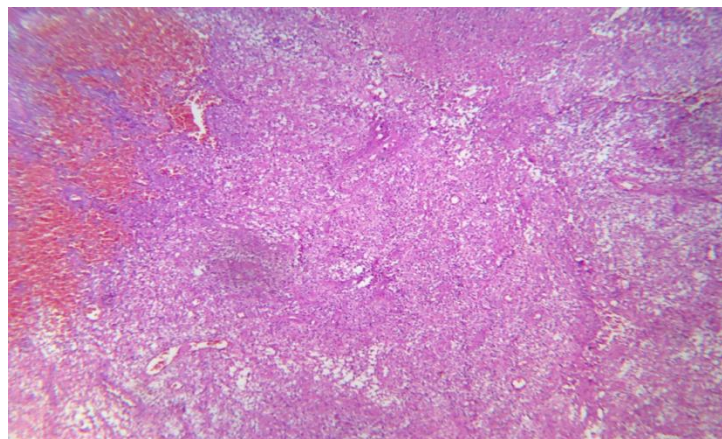


Figure 4: Necrosis, fibrinoid thrombosis of vessels, polymorphonuclear cell infiltration of tissue

DISCUSSION

Fournier's gangrene results from immune deficiency, urogenital trauma, scalds, diarrhoea, foreign body and idiopathic. Organisms involved are *Clostridium perfringens*, *Clostridium Welchii*, Staphylococci, streptococci, aerobic, anaerobic streptococci and *Pseudomonas* species and fungi (Goyette, 1997). Polymicrobial organism's virulence results in production of toxins or enzymes that promote further multiplication of organisms and spread of gangrene (Mergenhagen *et al.*, 1958). Fournier's gangrene has an identifiable cause in 75-95% of cases (Smith *et al.*, 1998).

Fascial necrosis and digestion are hallmark of this disease process. Enzymes from the microorganisms cause coagulation of nutrient vessels causing thrombosis reduced local blood supply which in turn causes low tissue oxygen tension. Enzymes like lecithinase, collagenase cause digestion of fascial barriers, thus fueling rapid extension of the infection. Necrotizing process commonly originates from an infection in ano-rectum, urogenital tract or skin of the genitalia (Clayton *et al.*, 1990). Dermatological causes include

Case Report

hydraadenitis suppurativa, Ulcerations due to scrotal pressure, trauma, poor perineal hygiene, accidental, intentional or surgical trauma, presence of foreign bodies in the genital or rectum may lead to disease process (Stevens *et al.*, 2005). Predisposing factors are malnutrition, extremes of age, alcoholism, cirrhosis, obesity, SLE, long term corticosteroid therapy, HIV infection and malignancies. Diabetes is present in as many as 60% of the cases (Rajbhandari and Wilson, 1998). Old age, Leukemias, HIV infection, any other high risk condition like Diabetes is to be taken care of.

Pain is the first symptom, dusky red to black spot, tenderness and crepitus on palpation, dark brown, turbid fluid with pus is characteristic feature associated with foul smell. According to the structures involved may cause fasciitis, myositis and necrosis of the tissues. Feculent odour is due to anaerobic bacteria, crepitus is due to clostridium species or other gas producing organisms. Systemic symptoms like fever, tachycardia, and hypotension may be present. Skin overlying the affected region may be normal, erythematous, oedematous, cyanotic, bronzed, indurated, blistered and or frankly gangrenous.

Balanitis, Cellulitis, Acute epididymitis, Testicular torsion, obstructed hernia are to be considered in the differential diagnosis. Diagnosis of Fourniers gangrene is based primarily on clinical findings. Apart from the routine investigations like CBP, RBS, LFT, RFT, Blood and urine cultures, ketone bodies, ABG sampling, DIC panel and culture of open wounds, pelvic imaging studies, ECG are to be done.

Treatment of Fournier's gangrene involves several modalities. Early Surgical intervention is essential to reduce the mortality and morbidity by excision of necrotic tissue (Sugihara *et al.*, 2012). Early recognition is the important factor for better outcome as the infection spreads very fast within a few hours. Wound debridement as early as possible to be done and all necrotic tissue should be excised. If primary closure of the skin is not possible local skin flap or split thickness skin grafts are advocated. Aggressive resuscitation to restore normal organ perfusion and function to be attained. Fluid and electrolyte balance to be maintained. Airway management hyperbaric oxygen should be provided. Early broad spectrum antibiotics should be given. If tissue stains show fungi empiric antifungal agents like Amphotericin B should be started. Meanwhile discharge from the lesion and blood should be sent for culture and sensitivity.

If extensive soft tissue is lost, lymphatic drainage is compromised causing dependent edema and cellulites may result. In 1995 Laor and colleagues introduced the Fournier gangrene severity index [FGSI] based on temperature, heart rate, respiratory rate, WBC count, haematocrit, serum sodium, potassium, creatinine and bicarbonate. Each parameter is assigned a score between 0 and 4 with the higher values indicating greater deviation from normal. FGSI greater than 9 is associated with increased mortality (Laor *et al.*, 1995). In 2010, Yilmazlar and colleagues updated the FGSI (UFGSI), adding two additional parameters- Age and Extent of the disease- to further refine the prognostic utility of FGSI (Yilmazlar *et al.*, 2010). Increased age and medical comorbidities are associated with increased risk of death due to multi organ failure ranging from 20-30% (Czymek *et al.*, 2009).

Conclusion

Balano-posthitis and infection may spread rapidly to shaft of the penis due to Diabetes as existing comorbid condition. Fourniers gangrene is rapidly spreading fascial necrosis of the tissues due to vascular compromise of the nutrient vessels, by the enzymes released from the polymicrobials causing thrombosis. If timely diagnosis and intervention is not undertaken may lead to sepsis and multiorgan failure causing high mortality.

REFERENCES

- Ayumba BR and Magoha GA (1998).** Epidemiological aspects of Fourniers gangrene at Kenyatta national Hospital, Nairobi. *East African Medical Journal* **75**(10) 586-9.
- Ayumba BR and Magoha GA (1998).** Management of Fourniers gangrene at Kenyatta National Hospital, Nairobi. *East African Medical Journal* **75**(6) 370-3.
- Clayton MD, Fowler JE, Sharifi R and Pearl RK (1990).** Causes, presentation and survival of fifty-seven patients with necrotizing fasciitis of male genitalia. *Surgery, Gynecology, and Obstetrics* **170**(1) 49-55.

Case Report

- Czymek R, Hildebrand P and Kleeman M et al., (2009).** New insights into the epidemiology and etiology of Fourniers gangrene: a review of 33 patients. *Infection* **37**(4) 306-12.
- Goyette M (1997).** Group A streptococcal necrotizing fasciitis Fourniers gangrene- Quebec. *Canada Communicable Disease Report* **23**(13) 101-3.
- Laor E, Palmer LS, Tolia BM, Reid RE and Winter HI (1995).** Outcome prediction in patients with Fourniers gangrene. *Journal of Urology* **154**(1) 89-92.
- Mergenhagen SE and Thonard JC et al., (1958).** Studies on synergistic infections. *Journal of Infectious Diseases* **103**(1) 33-44.
- Paty R and Smith AD (1992).** Gangrene and Fourniers gangrene. *Urologic Clinics of North America* **19**(1) 149-62.
- Rajbhandari SM and Wilson RM (1998).** Unusual infections in diabetes. *Diabetes Research and Clinical Practice* **39**(2) 123-8.
- Smith GL, Bunker CB and Dinneen MD (1998).** Fourniers gangrene. *British Journal of Urology* **81**(3) 347-55.
- Stevens DL, Bisno AL and Chambers HF et al., (2005).** Practice guidelines for diagnosis and management of skin and soft tissue infections. *Clinical Infectious Diseases* **41**(10) 1373-406.
- Sugihara T, Yasunaga H, Horiguchi H, Fujimura T, Ohe K and Matsuda S et al., (2012).** Impact of surgical intervention timing on the case fatality rate of Fourniers gangrene: an analysis of 379 cases. *BJU International* **110**(11pt c) E1096-100.
- Yilmazlar T, Ozturk E, Ozguc H, Ercan I, Vuruskan H and Oktay B (2010).** Fourniers gangrene: an analysis of 80 patients and a novel scoring system. *Techniques in Coloproctology* **14**(3) 217-23.