

### Case Report

## SINGLE STAGE RECONSTRUCTION OF ALAR RIM DEFECT USING AURICULAR COMPOSITE GRAFT: A CASE REPORT

Surabhi Chopra, Shaila Bangad, Y.U. Kelgaonkar, Sham S. Somani and \*Sachin B Ingle

Department of ENT and Pathology, MIMSR Medical College, Latur, Maharashtra

\*Author for Correspondence

### ABSTRACT

A case report of reconstruction of a post-surgical alar rim defect, in a woman of 50 years of age, occurring as a result of basal cell carcinoma of the nose, using a composite graft taken from the ear in a single stage is described. This report highlights the key steps in such a process with the ease with which we could achieve success.

**Key Words:** Alar defect, Composite graft, Ear, Nose, Reconstruction

### INTRODUCTION

Alar rim defects are common due to a wide variety of causative factors namely post traumatic, post excisional (malignancy), post infective, congenital, etc. These alar defects can be of various sizes. Surgical reconstruction of the nose evolved along with time, the choice of reconstructive method being based on the size, location, and depth of the defect requiring replacement. Reconstruction of the nasal alar/vestibular complex following trauma or surgery presents a challenging problem. Options include bone, cartilage, and composite grafts as well as prosthetic materials. The fragile alar rims are complex structures whose specialized and supportive skin ensures the competence of the external valves and the patency of the inlets to the nasal airways. Auricular composite grafts are a useful reconstructive option, particularly for alar reconstruction. Auricular composite grafts are being used increasingly for repair of nasal deformities. Most commonly these grafts have been employed to repair alar rim and columellar defects secondary to trauma or tumour resection.

### CASES

A 50 year old woman presented to us with history of a right alar mass of size 1x1 cms since 6 months (Figure 1). On biopsy of the mass a diagnosis of basal cell carcinoma was made. The patient was posted for surgical excision of the mass under general anaesthesia. After excision 1.3 cms defect was noted in right alar margin with loss of the skin, cartilage and inner mucosa (Figure 2).

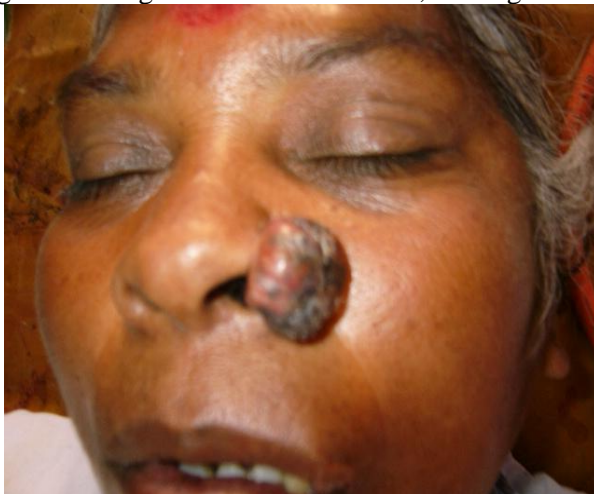


Figure 1: Image of the patient with basal cell carcinoma of nose

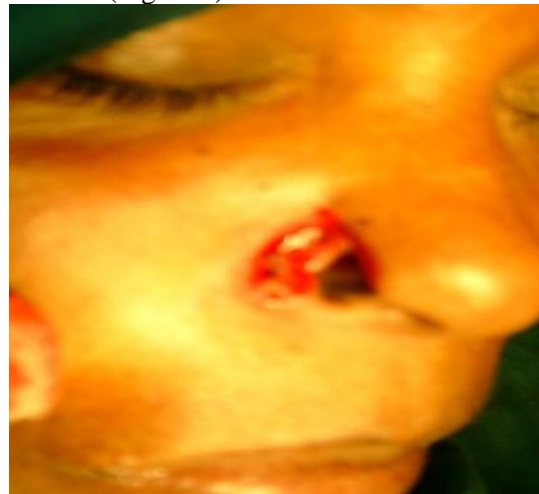
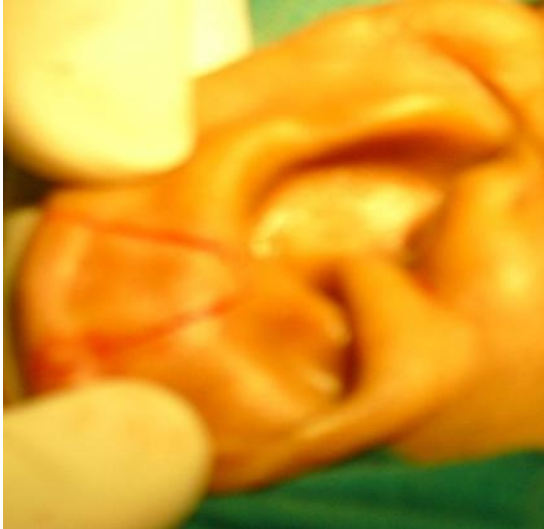
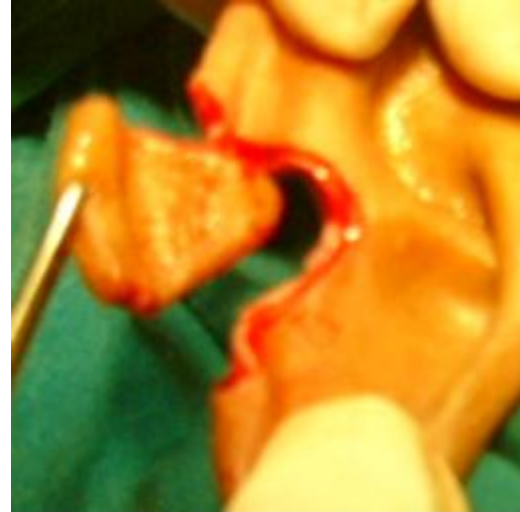Figure 2 : Image of the defect

### **Case Report**

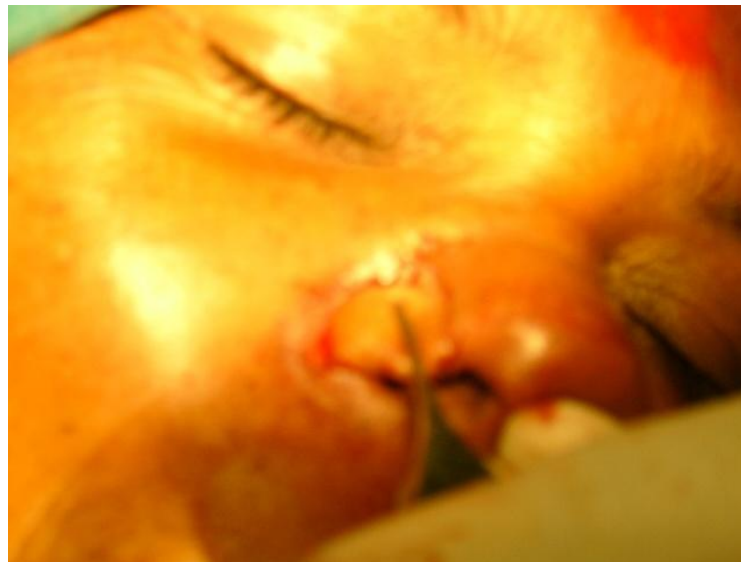On examination, the site of the defect had minimal scarring and no signs of inflammation. Looking at the site and size of the defect, a plan was made to reconstruct the defect in a single stage operation, using a composite graft taken from the ear, from the root of the helix (Figure 3). The composite graft was harvested from the root of the right helix after marking the defect and the donor site was closed primarily (Figure 4).



**Figure 3 : Image of donor site**



**Figure 4 : Harvesting of composite graft**



**Figure 5: Graft sutured to the defect**

The composite graft was immediately sutured to the recipient site for better opposition of the margins. The inner mucosal layer was sutured first to the composite graft using 6-0 chromic catgut and the skin was sutured using a 6-0 nylon taking interrupted sutures (Figure 5). The nasal cavity was packed with paraffin gauze and a small dressing was applied after applying a thin layer of ointment outside. The take of the composite graft was total and the final correction of the contour and defect was excellent. There was some colour mismatch; this too has improved with time the donor site healed without any problem.

## Case Report

### DISCUSSION

In planning the reconstruction of the nose, accurate analysis of the defect is essential; if the three layers (skin, skeleton and lining) are lacked the reconstruction becomes more complex and less predictable; choosing the donor site is important for the skin thickness, color, texture and size of the defect and the remaining skin (Brown 1996).

Small through and through defects of the nasal ala may be managed with a composite graft of auricular tissue obtained from the earlobe, helical rim or the root of the helix. Composite chondrocutaneous grafts from either the helical rim or the root have been recommended for small through and through defects of the nostril rim. The traditional auricular composite graft used for nasal reconstruction is a wedge shaped section of the helical rim that includes two layers of skin separated by cartilage. In general terms, any grafted tissue more than 5mm distant from a vascular bed is at significant risk of necrosis (Gilles 1990). Auricular composite grafts used for reconstruction of the alar rim should be no larger than 1.5cms in diameter so the center of the graft is never more than 5 to 8 mm away from a blood supply (Konig 2002). Composite grafts include full thickness skin and accompanying periosteum and cartilage. They can be used when both the soft tissue and underlying cartilaginous skeleton has been lost (Argamaso 1995).

In general, smaller the size of the composite graft the greater the chance of successful revascularization and graft survival. A composite graft designed with a maximum diameter of 1 cm is successful (Daniel 1994). It is recommended that a graft larger than 2 cm not be attempted. The donor site for composite grafts can be the ear, opposite ala or nasal septum (Barton 1999). The scar tissue from the recipient site is excised for obtaining good vascularised bed helping for the survival of the transplanted composite graft. Very gentle and delicate handling and care of the graft is necessary and should be transferred to the recipient site at the earliest. The advantages of composite grafts are that it is a single stage operation with excellent contour correction. The disadvantages are that it is not indicated for larger defects (size limitation) and the final color match may not be very good (Sood 1997).

### REFERENCES

- Brown JB, Cannon B (1996).** Composite free grafts of skin and cartilage from the ear. *European Journal of Plastic Surgery* **82**(2) 253-259.
- Gilles HD (1990).** Plastic surgery of the face. *London: Oxford Medical Publishers* **23**(6) 35-42.
- Konig F (2002).** On filling defects of the nostril wall. *Berl Klin Wochensr. Laryngoscope* **39**(3) 137-142.
- Argamaso RV (1995).** An ideal donor site for the auricular composite graft. *British Journal of plastic surgery* **28**(12) 219-303.
- Daniel E Rousso, Fred G Fedoh (1994).** In Nasal Plastic Surgery. McCollough EG, WB Saunders Company. *British Journal of Plastic Surgery* **23**(3) 328-329.
- Barton FE (1999).** Nasal Reconstruction. In Smith JW, Aston SJ, editors. *Grabb and Smith's Plastic Surgery* 4<sup>th</sup> Edn Little Brown and Company 493.
- Sood VP (1997).** Corrective Rhinoplasty 1<sup>st</sup> Edn CBS Publishers and Distributors 158-159.