

Case Report

LETHAL MULTIPLE PTERYGIUM SYNDROME ASSOCIATED WITH MULTIPLE SYSTEMIC MALFORMATIONS –A CASE REPORT

***R. Ramana Rao, B. Narasinga Rao and V. Durgesh**

Department of Anatomy, Maharajah's Institute of Medical Sciences, Nellimarla, Andhra Pradesh, India

**Author for Correspondence*

ABSTRACT

The present case was a third trimester still born foetus diagnosed to be very rare with only 200 reported cases termed as Lethal Multiple Ptergium Syndrome. Cervico sternal contracture (Pterygium colli), bilateral axillary and popliteal pterigia, potter face, bilateral hydronephrosis, bilateral cryptorchidism, bilateral pulmonary hypoplasia were the prominent presenting features. Polydactyly of both hands, bowing of the proximal parts of both forearm bones and leg bones happened to be the associated characteristics of this syndrome. Mal development of the collecting system of the kidneys and the hypoplasia of lungs were responsible for the mortality of the foetus.

Key Words: *Lethal Multiple Ptergium Syndrome, Cervico Sternal Contracture, Pterygium Colli, Popliteal Pterigia and Potter Face*

INTRODUCTION

Lethal Multiple Ptergium syndrome is a very rare congenital anomaly with only two hundred reported cases, Characterised by abnormal contractures with soft tissue webbing across various joints, polydactyly/syndactyly, fusion of the limb bones at various joint levels Woodward *et al.*, (2005); cryptorchidism Wynbrandt and Mark (2003) and potter face Turnpenny (2005). The lethal form of the syndrome is represented by hypoplasia of lungs, kidneys and mal development of the gastrointestinal system Wynbrandt (2003). Hence the present case is also a still born foetus obtained from the Maharajah's Institute of medical sciences Nellimarla following all the protocols the foetus is taken up for the study.

CASES

A 27 year female with a non consanguinous marriage of five years, G₂P₂L₁A₀D₁ with a healthy first child, and no family history of congenital abnormality, underwent spontaneous preterm parturition at Maharajahs Institute of Medical Sciences to deliver a 31 wk stillborn male foetus with gross anatomical anomalies the following were the observations.

Foetal Autopsy - Findings

External Features:

Foetal Measurements:

Weight of the fetus: 1.6kgs.

Head Circumference: 28cm

Right upper limb length: 10.5cm

Left Upper Limb length: 11cm

Right Lower Limb length: 9.5cm

Left Lower Limb length: 11.5cm

Facial abnormalities included Potter's face with micrognathia, Hypertelorism, epicanthic folds, flat nose and Low set of ears. Cervico sternal Pterygium was present along with bilateral axillary pterygium of which Right axillary contracture was relatively more. Though the figure did not show the popliteal pterigia amongst the bilateral popliteal pteridium observed the right popliteal pterygium was more.

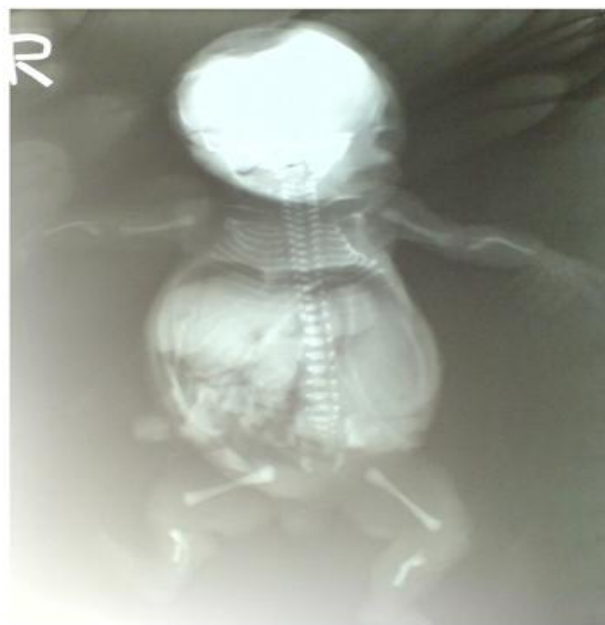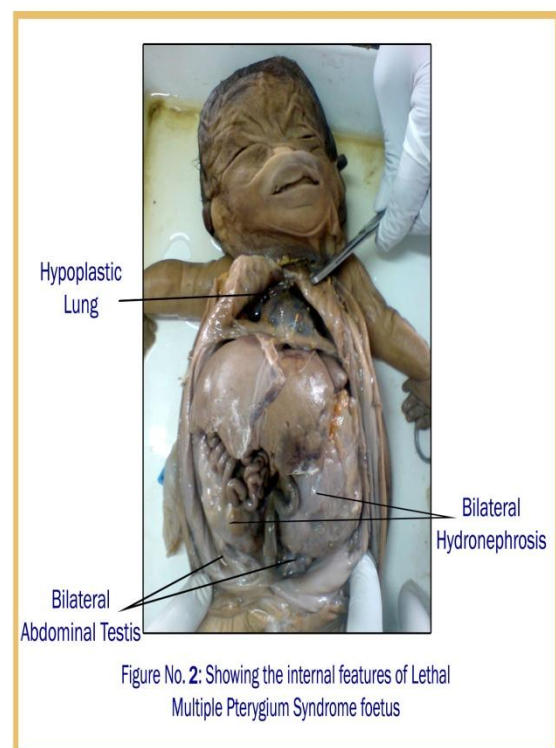
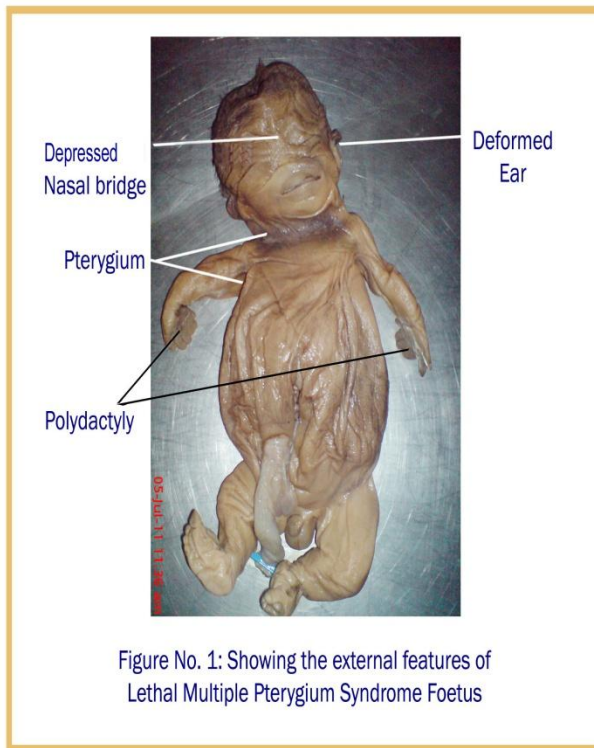
Both the upper extremities showed polydactyly with heptadactyly on right side with syndactyly of fourth, fifth and sixth digits; left hand presented hexadactyly. Narrow and tubular Thorax and grossly distended abdomen were observed. No evidence of abnormalities in the vertebral column or in the external

Case Report

genitalia was observed. Anal atresia was absent. Lower limbs did not show any external variations (Fig. 1).

Internal Features: Bilateral Hydronephrosis was observed. Both the testes were located at the lower pole of the kidneys indicating bilateral cryptorchidism .Bilateral Hypoplastic Lungs was witnessed (Fig. 2).

Foetogram: Micrognathic mandible was a feature along with broad clavicles and ribs.



Case Report

Bilateral fusion of radius to ulna and tibia to fibula proximally was evident this lead to the bowing appearance.

Vertebral column showed relatively larger intervertebral disc spaces when compared with that of a normal foetus radiograph (Fig. 3).

DISCUSSION

Woodward (2004) gave an account of the Multiple Pterygium Syndrome to be having multiple limb contractures across the joints, digital syndactyly and scoliosis and attributing Hypoplastic Lungs, hydrops as the features of the lethal type of Multiple Pterygium Syndrome.

Wynbrandt (2003) described in detail about the multiple pterygium syndrome by the following features; presence of pterygia the fibrous malformations giving webbed skin appearance at some of the flexor aspects of the joints, undescended testis, syndactyly and fusion of the cervical vertebrae leading to scoliosis, but only mentioned the existence of a severe Lethal Multiple Pterygium Syndrome.

De Die-Smulders (1990) on reviewing 36 pterygia cases attributed lethality to the hygroma colli. The author observed that big joints only showed the pterygia, micrognathia was also mentioned as an associated feature, hypoplastic bones were the only radiological findings which were also seen in the present case as well.

A detailed study by Orphanet (2006) and Cox *et al.*, (2003) underlines a wide variety of characteristic representations of Lethal multiple pterygium syndrome in addition to the above said features: occasionally presence of midforehead haemangioma, intestinal malrotation, cardiac hypoplasia, diaphragmatic hernia, obstructive uropathy, microcephaly, or cerebellar and pontine hypoplasia. The author also discriminated amongst a type I Lethal multiple pterygium syndrome represented by vertebral fusion and type II Lethal multiple pterygium syndrome by long bone fusion.

Tolmie *et al.*, (1987) and De Die-smulders *et al.*, (1990) opined while describing the three male fetuses of Lethal multiple pterygium syndrome born to mothers who were second-degree relatives through the female line that Lethal multiple pterygium syndrome in this family to be of X-linked recessive inheritance. In the present case no such family relation could be established in supporting such an inheritance.

Having reviewed all the available data of 14 cases of Lethal multiple pterygium syndrome Cox *et al.*, (2003) stated that the Lethal multiple pterygium syndrome phenotype could be due to the foetal akinesia appearing either in the first or late second trimester. In most of the occasions the primary etiology being obscure with very few pathological conditions like metabolic or neurodevelopmental disorder or a specific primary myopathy left demonstrable.

Cardiac hypertrophy and connective tissue abnormality were observed along with pterygia by Hartwig *et al.*, (1989) and suggested that the Lethal multiple pterygium syndrome to be the consequence of the fragile collagen abnormality Brink (2003) reported a case of Lethal multiple pterygium syndrome at 31 wks of gestation incidentally the present case reported was also of 31 wks of gestation in accordance Froster.UM (1997) reported two cases of late gestation age Lethal multiple pterygium syndrome still born to non consanguineous parents in agreement with the family history of the present case on the contrary Chen *et al.*, (1980) reported 4 cases of Lethal multiple pterygium syndrome occurred to consanguineous parents. Martin *et al.*, (1986) while reporting three cases of Lethal multiple pterygium syndrome observed hydrops in all of them and opined that any attempt to force an identity from the classification of (Hall *et al.*, 1982) would not be appropriate. Vincenzo *et al.*, (1994) did not exclude an autosomal recessive inheritance, but emphasized on an X-linked recessive inheritance. Vincenzo *et al.*, (1994) and Froster *et al.*, (1997) also suggested that the syndrome combined the manifestations of a jugular lymphatic obstruction sequence with those of an early severe foetal akinesia sequence with two possible mechanisms: an abnormally fragile collagen constitution or an early fetal muscular "dystrophy". Petter and Sian (2005) stated that the potter face resulted from oligohydramnios to be a consequence of bilateral renal dysplasia.

Case Report

The present case showed multiple Pterygia, Pterygium Coli in the neck region, both the axilla and popliteal region also had contractures explaining the disproportionate lengths of the limbs of Right and left side seemingly the right side contractures were of greater extent. Most of the characteristic features observed were coinciding with above authors, as the foetogram showed fusion of the long bones in the proximal region of the fore arm and leg. Hence the present case is concluded to be the second type of Lethal multiple pterygium syndromes as described by Orphanet (2006). As there is no family history of congenital anomaly no possible genetic predisposition could be arrived at.

Conclusion

Meticulous evaluation of progressive viability of the foetus and diagnosis of the condition at an early foetal gestation is pivotal determinants for the future of the foetus. Beyond the Knowledge of mere morphometric values of the foetus, calculating their implications and suggesting an outcome with an emphasis would only be possible for a medical person by updating with the facts of the existence of such lethal variants of viable degree congenital anomalies. Detailed genetic study though warranted in the present case could not be accomplished as handing over of the foetus was much delayed.

REFERENCES

- Brink DS, Luisiri A and Grange DK (2003).** Case Report: Lethal Multiple Pterygium Syndrome. *Pediatric Pathology and Molecular Medicine* **22**(6) 461-470.
- Chen H and Chang Ch et al., (1980).** Multiple Pterygium syndromes. *American Journal of Medical Genetics* **7**(2) 91-102.
- Cox PM and Brueton LA et al., (2003).** Diversity of Neuromuscular pathology in Lethal Multiple Pterygium syndrome. *Pediatric Developmental Pathology* **6**(1) 59-68.
- De Die-smulders CE, Schrandt stumpel CT and Fryns JP (1990).** The Lethal Multiple Pterygium Syndrome: a nosological approach. *Genetic Counselling* **1**(1) 13-23.
- Froster UG and Stallmach T et al., (1997).** Lethal Multiple Pterygium syndrome: suggestion for a consistent pathological workup and review of reported cases. *American Journal of Medical Genetics* **68**(1) 82-85.
- Hall JG and Reed SD et al., (1982).** Lethal Multiple Pterygium syndrome: a review and report of eleven patients. *American Journal of Medical Genetics* **12**(4) 377-409.
- Hartiwig NG and Vermeij Keers C et al., (1989).** Case of Lethal Multiple Pterygium Syndrome with special reference to the origin of Pterygia. *American Journal of Medical Genetics* **33**(4) 537-541.
- James Wynbrandt and Mark D Ludman (2004).** The Encyclopedia Of Genetic Disorders and Birth defects. 2nd Edition Published by Viva Books as an arrangement with Facts on File New York 216.
- Martin NJ, Hill JB et al., (1986).** Lethal Multiple Pterygium syndrome: three consecutive cases in one family. *American Journal of Medical Genetics* **24**(2) 295-304.
- Orphanet (2006).** Lethal multiple pterygium syndrome Orphan number: ORPHA33108 Online publication by Orphanet version 4.6.3 Available: www.orpha.net/consor/cgibin/Disease_Search.php?lng=EN&data_id=10308
- Petter T and Sian E (2005).** Congenital Abnormalities and Dysmorphic Syndromes. In Emery's Elements Of Medical Genetics In 12th Edition Elsevier Churchill Livingstone Edinburgh 252.
- Tolmie JL, Patrick A and Yates JR (1987).** A lethal multiple pterygium syndrome with apparent X-linked recessive inheritance. *American of Medical Genetics* **27**(4) 913-919.
- Vincenzo Suma, Alberto Marini, Francesco Bellitti, Guglielmo Serpotta and Riccardo Saia (1994).** Pterygium syndrome multiple lethal. Available: <http://www.sonoworld.com/Fetus/page.aspx?id=214>
- Woodward Kennedy, Sohaey Byrne Oh and Puchalski (2004).** Diagnostic Imaging Obstetrics. 1st Edition Published by AMIRSYS /ELSEVIER Utah.