

Case Report

A RARELY USED POSTERIOR SURGICAL APPROACH TO THE UPPER POSTERIOR PART OF HUMERUS

***Sathis Kumar G.**

Department of Orthopaedics, ACG Medical College, Chennai, India

**Author for Correspondence*

ABSTRACT

The posterior aspect of the proximal region of humeral diaphysis can be exposed through the longitudinal approach to the posterior aspect of the upper end of humerus. No nerves or major blood vessels are exposed in the dissection, although care must be taken to protect axillary and radial nerve. This approach was used in a case of excisional biopsy of an exostosis in proximal part of the humerus of a 14 year old boy.

Key Words: *Proximal Humeral Diaphysis, Posterior Approach*

INTRODUCTION

Proximal humerus has been traditionally exposed using the delto-pectoral approach. Other surgical approaches to the shoulder are more focused towards the joint perse. When we are required to have a good exposure of the posterior aspect of the proximal humeral diaphysis, we run out of options. Here we report a case of exostosis of the right proximal humerus from the posterior aspect approached through the rarely used longitudinal posterior approach of the upper end of humeral diaphysis.

CASES

A 14 year old boy came to us with complaints of swelling in the posterior aspect of the left shoulder region. No history of pain or sudden increase in size of swelling. On examination, it was a bony swelling found in the posterior aspect of the left proximal humeral diaphysis. There was no tenderness and shoulder range of movements was normal. There was no distal neurovascular deficit. We investigated with X-rays and MRI which confirmed the bony swelling to be osteochondroma (exostosis) of the posterior aspect of the proximal humeral diaphysis. We decided to excise it.

Under general anaesthesia, In right lateral position with left arm over board (figure 1), a posterior midline skin incision was made from a point 2 finger breath below the posterior aspect of the acromion to the deltoid tuberosity, fascia incised. The interval between the posterior border of deltoid muscle and lateral head of triceps was found. Deltoid retracted laterally. The tumour cap became visible (figure 2, 3). The lateral head of triceps was subperiosteally elevated medially to expose the base of the pedicle and tumour was excised in to-to. Wound closed in layers. No neurovascular structures were encountered in this approach. Surgical time was 1 ½ hours. There were no issues with wound healing nor did we encounter any neurovascular complications.

At 6 months follow up, patient had no recurrence of the tumour both clinically and radiologically. Shoulder range of movements was full and free. Patient had no neurovascular complications.

DISCUSSION

We could not find the right surgical approach for the posterior aspect of the upper humeral diaphysis through standard text books like Hoppenfeld, Muller, and Campbell & Jordon. Even our search through the internet yielded original paper (Berger, 1989) describing the required approach. The routinely done Posterior midline surgical approach, to the posterior aspect of the humeral diaphysis has been used to expose the middle and distal third of that bone. It necessitates separation of lateral and long head of the

Case Report

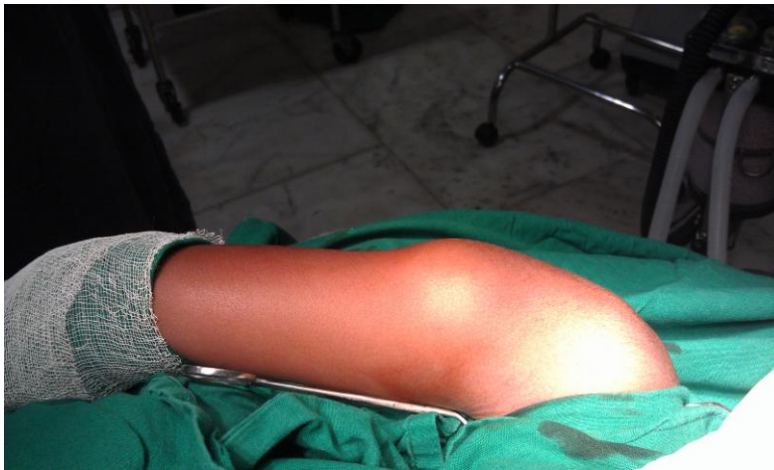

Fig 1

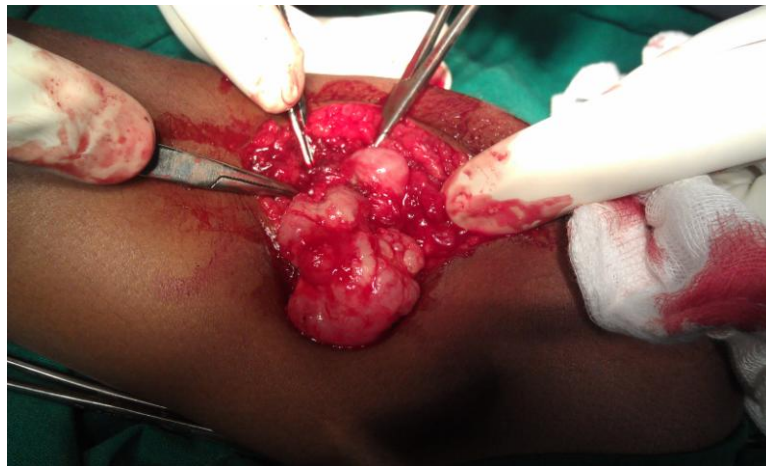


Fig 2

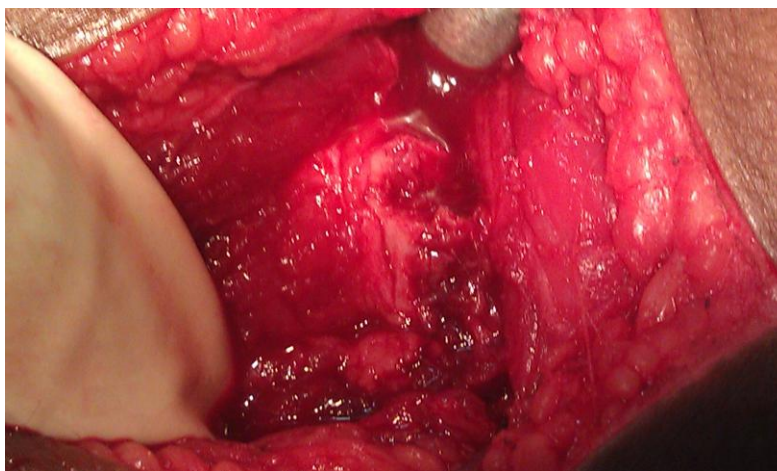


Fig 3

Case Report

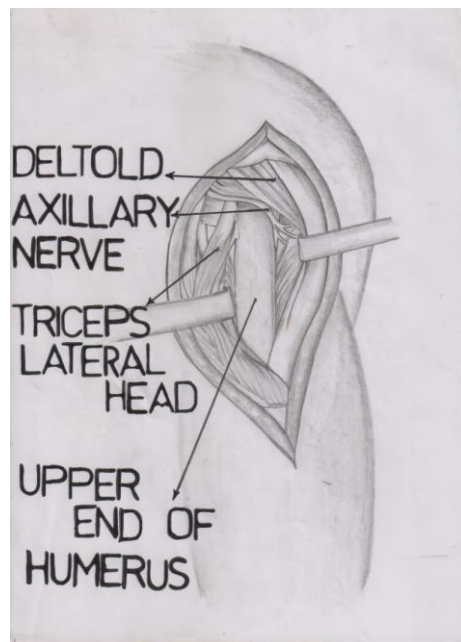


Fig 4

triceps, as well as dissection of radial nerve and it has not been recommended for exposure of proximal part of the humerus. Rarely, a posterior approach to the proximal third of the humerus is needed, as in this patient, whose case was just described. The posterior aspect of this part of humerus can be exposed by releasing the origin of the deltoid muscle from the spine of the scapula and reflecting the deltoid laterally, to give access to the interval between the deltoid and the triceps. However the dissection is extensive and likely to weaken the deltoid muscle, and places the axillary nerve at risk.

Another posterior approach to the shoulder through the interval between teres minor and infraspinatus muscle after retracting the deltoid muscle has been described. This approach however does not expose the proximal part of humeral diaphysis and cannot be extended to provide access to this area because of the interposed axillary nerve and posterior humeral circumflex artery.

The surgical approach which we have used provides adequate exposure to proximal humeral diaphysis posteriorly and it does not endanger any major neurovascular structures. However the limitation of this approach is that the axillary nerve and posterior humeral circumflex artery are located just cephalad to this margin and they may be damaged directly by further proximal dissection (figure 4).

Conclusion

With the right patient selection, the just discussed posterior approach for the proximal humeral diaphysis exposure is a worthwhile and rewarding procedure.

REFERENCES

- Berger et al., (1989).** A posterior surgical approach to proximal part of the humerus. *JBJS* 71-A(3).
- Christopher Jordan (No Date).** Thieme medical publishers 2000. Atlas of Orthopaedic surgical exposures 23-34.
- Crenshaw AH (No Date).** Surgical approaches, In campbell's operative orthopaedics 11th edition 1 103 – 104.
- Hoppenfeld, Stanley and DeBoer PIET (No Date).** Surgical exposures in Orthopaedics: 4th edition 88-92.
- Kaplan EB (No Date).** Surgical approaches to the Neck, cervical spine and upper extremity 104-109.

Case Report

Muller ME, Allgower M, Schneider R and Willenegger H (No Date). Manuel of internal fixation
Technique recommended by the AO group, Translated by Schatzker J. 3rd edition 442-444.

Rockwood and Green (No Date). 6th edition fractures in adults 1129.