

Research Article

A STUDY ON FORAMEN OVALE IN HUMAN SKULLS

Chandra Philips X.¹ and *Arun Kumar S. Bilodi²

¹Department of Anatomy, Mahatma Gandhi Medical College and Research Institute (MGMC & RI),
Plliyarkuppam, Pondicherry 607402

²Department of Anatomy, Velammal Medical College Hospital & Research Institute (VMCH & RI),
Velammal Village, Anuppanadi Post:
MADURAI -625009, Tamil Nadu

**Author for Correspondence*

ABSTRACT

The objective of present study was to study the morphology of foramen ovale. This case was studied in the Department of Anatomy of Sikkim Manipal Institute of Medical Sciences, Sikkim. A fifty unknown human skulls from the Anatomy Department of Sikkim Manipal Institute of Medical Sciences, Sikkim constituted the materials for the present study. In all the skulls, posterior part of greater wing of sphenoid bones were studied for the different sizes and shapes of foramen ovale were studied along with maximum length and width of foramen ovale were also studied Their variations of length and breadth were noted. Also variations of accessory foramina, any bony growth were noted. Foramen ovale is used to diagnose squamous cell carcinoma meningioma by technique of CT guided transfacial fine needle. It is through foramen ovale many invasive surgical as well as diagnostic procedures can be carried out and biopsy of the deep lesions of the brain which reduces the morbidity can be taken.

Key Words: *Foramen Ovale, Greater Wing of Sphenoid, Mandibular Nerve, Accessory Meningeal Artery, Pre Sphenoids and Post Sphenoids Centers*

INTRODUCTION

In the posterior part of greater wing of sphenoid, there is opening known as Foramen ovale. Through this foramen pass four structures, namely i) Mandibular nerve, ii) Accessory meningeal artery, iii) Lesser petrosal nerve and iv) Emissary vein. This foramen which present in greater wing of sphenoid bone is posterior and lateral to foramen rotundum (Reymond *et al.*, 2005; Standring, 2006). Various studies have shown abnormal morphologies. They are Sometimes they are covered by ossified ligaments extending between lateral pterygoid process and spine sphenoid bone (Błaszczuk *et al.*, 1980; Kapur *et al.*, 2000). There may be bony spur located in the venous compartment situated antero-medially giving rise to double foramina of foramen ovale (Lang *et al.*, 1984). In another study conducted, foramen ovate has been divided into 2 or 3 components in 4.5% of the 100 macerated skulls associated with irregularities (Reymond *et al.*, 2005).

MATERIALS AND METHODS

The anterior approach of measurement of the foramen ovale has been used since its description Hartel in 1914. The free hand technique of Hartel in introducing an electrode through the foramen ovale cause seriously complication. Therefore, the method has been improved by a combination of new technology and the modification including used of radiographic technique by several experts. However, even with an ideal positioning of the patients head it can be difficult to clearly visualize the foramen ovale. So, we follow with cadaver skulls.

Materials

- 1) A pair of dividers.
- 2) Measuring scale.

Research Article

Methods

A total of 50 dried adult human skulls of unknown age and gender were utilized for the study. These skulls were obtained from the Anatomy Department Sikkim Manipal Institute of Medical Sciences (SMIMS). The posterior part of greater wing of sphenoid bone was carefully examined for existence of an oval aperture and foramen ovale was identified. Patency was confirmed by inserting a bristle through each skull. Skulls in poor condition or skulls with partly damaged surrounding of the foramen ovale were not considered. In each skull following finding were recorded-

- 1) Maximum length and width of foramen ovale was measured in both sides of the skull by using a pair of dividers. Variation in right and left side in length and breadth was evaluated.
- 2) The variation in shape, accessory foramen, and bony growth around the margins of foramen was noted.

The shape of the foramen ovale was assessed by direct inspection as either oval, almond, round or slit. Statistical analysis was done by using student's test. Measurement of the foramen ovale were done by placing a pair of divider to span across the antero-posterior (length) and transverse (width) diameters of the foramina and then carefully transferred to a meter rule for the reading to be taken.

Observations

The present study was conducted on a total number of 100 sides in 50 dry adult skulls and following observation was made.

- 1) Mean length of the foramen ovale on right side was 7.27mm.
- 2) Mean length of the foramen ovale on left side was 7.46mm.
- 3) Maximum length of foramen ovale on right side was 9mm.
- 4) Maximum length of foramen ovale on left side was 9.5mm.
- 5) Minimum length of foramen ovale on right side was 3mm.
- 6) Minimum length of foramen ovale on left side was 4 mm.

The difference between the length of right and left side was not statistically significant ($P>0.05$).

- 1) Mean width of foramen ovale on right side was 3.18 mm.
- 2) Mean width of foramen ovale on left side was 3.21 mm.
- 3) Maximum width of foramen ovale on right side was 5 mm
- 4) Maximum width of foramen ovale on left side was 5 mm.
- 5) Minimum width of foramen ovale on right side was 2 mm
- 6) Minimum width of foramen ovale on left side was 2.5 mm.

The difference between the width on right and left side was statistically significant ($P>0.05$).

Shape of the Foramen Ovale was also Observed

- 1) Foramen ovale was typically oval on 68 sides (68%), 38 on right side (76%) and 30 on left side (60%).
- 2) Almond on 30 sides (30%), seen the foramen ovale, 14 on right side (28%) and 16 on left side (32%).
- 3) Round in 1 side (1%), seen the foramen ovale, 1 on the right side (2%) and 0 on the left side (0%).
- 4) D-Shape on 1 side (1%), seen the foramen ovale, 1 on the right side (2%) and 0 on the left side (0%).

Variant foramen ovale was also observed the study. Out of 100 cases 9 cases showed variant foramen ovale. They are-

- 1) In 2 cases (1 left side) had spine on the margin of foramen ovale and one plate on the right side.
- 2) In 1 case had spine on both sides
- 3) In 1 case left side had tubercle protruding from the margin along with D-shape foramen ovale.
- 4) In 2 cases 1 left showed bony plate protruding from the margin of the foramen ovale and 1 spine on right side.
- 5) In case 1 (right side) showed double foramen ovale.
- 6) In 1 case showed deficient posterior margin on both sides.
- 7) In 1 case showed spine on right side with almond shaped

Research Article

Table 1: Dimensions of foramen ovale in right and left side

Values	Length(Right)	Length(Left)	Width(Right)	Width(Left)
Maximum	9	9.5	5	5
Minimum	3	4	2	2.5
Mean	7.27	7.46	3.18	3.21
Standard deviation	1.306	1.16	1.5	1.5
P Value	>0.05=1.96		>0.05	
CV (%)	17.96	15.55	47.17	46.73

CV= Coefficient of Variation (percentage error)

Since the calculated value of “t” is greater than the table value of “t” at 0.05 probability level, it can safely be concluded that there is significant evidence of having differences in the dimensions of foramen ovale of both right and left sides from person to person. Therefore the hypothesis of no difference is rejected.

1. Maximum length and width of foramen ovale was measured in both sides of the skull by using a pair of dividers. Variation in right and left side in length and breadth was evaluated.

2. The variation in shape, accessory foramen, and bony growth around the margins of foramen was noted. The shape of the foramen ovale was assessed by direct inspection as either oval, almond, round or slit. Statistical analysis was done by using student’s test. Measurement of the foramen ovale were done by placing a pair of divider to span across the anteroposterior (length) and transverse (width) diameters of the foramina and then carefully transferred to a meter rule or the reading to be taken.

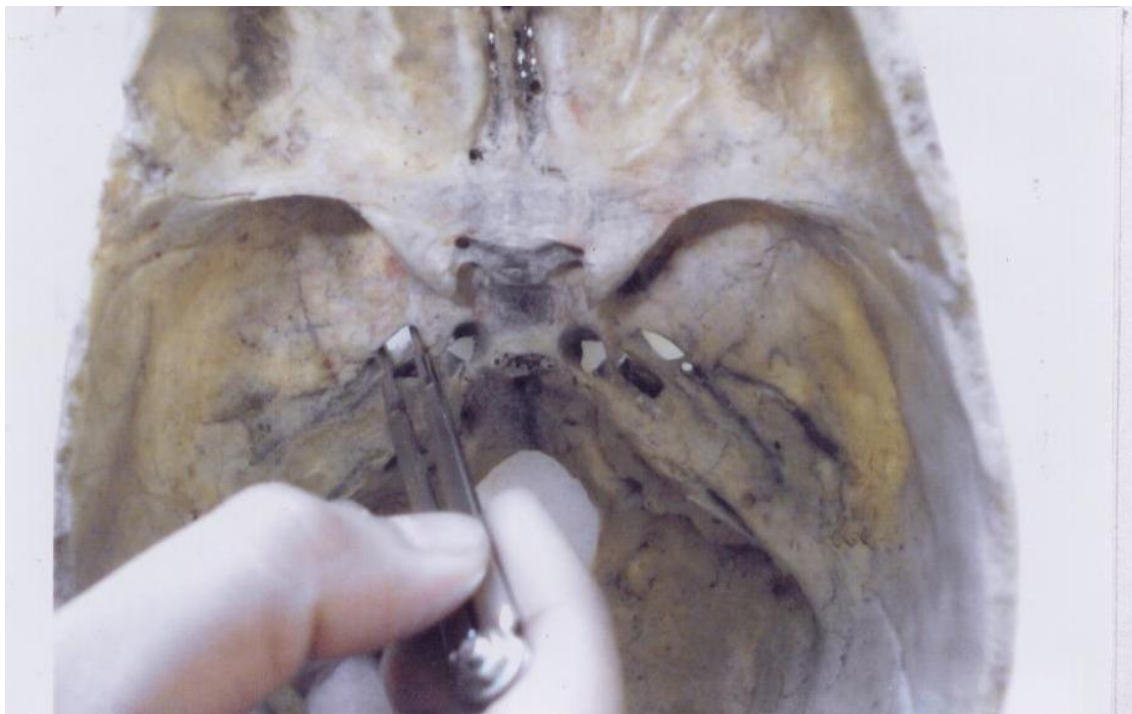


Figure 1: Shape of the foramen ovale was also observed

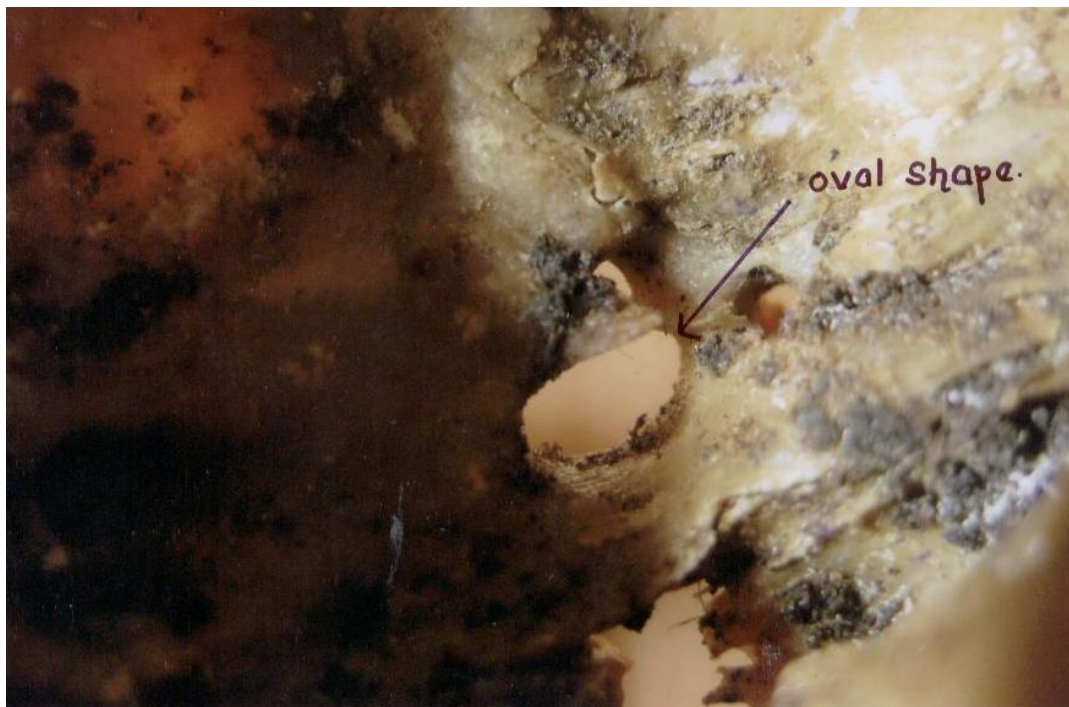

Figure 2: Foramen ovale was typically ovale on 68 sides (68%), 38 on right side (76%) and 30 on left side (60%)

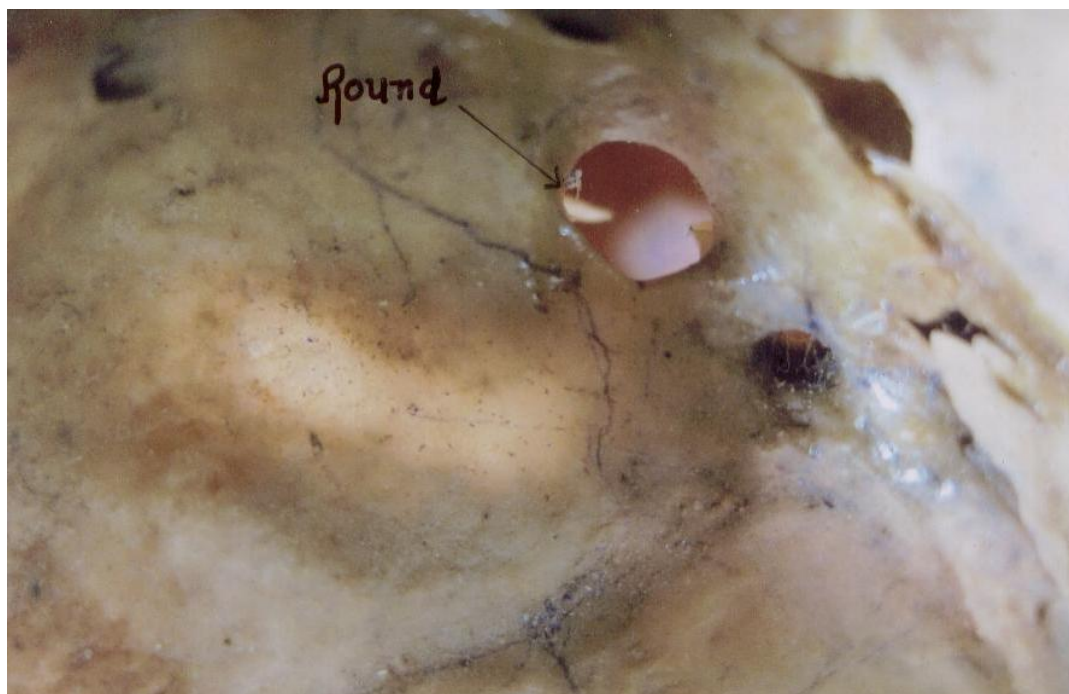

Figure 3: Round in 1 side (1%), seen the foramen ovale, 1 on the right side (2%) and 0 on the left side (0%)

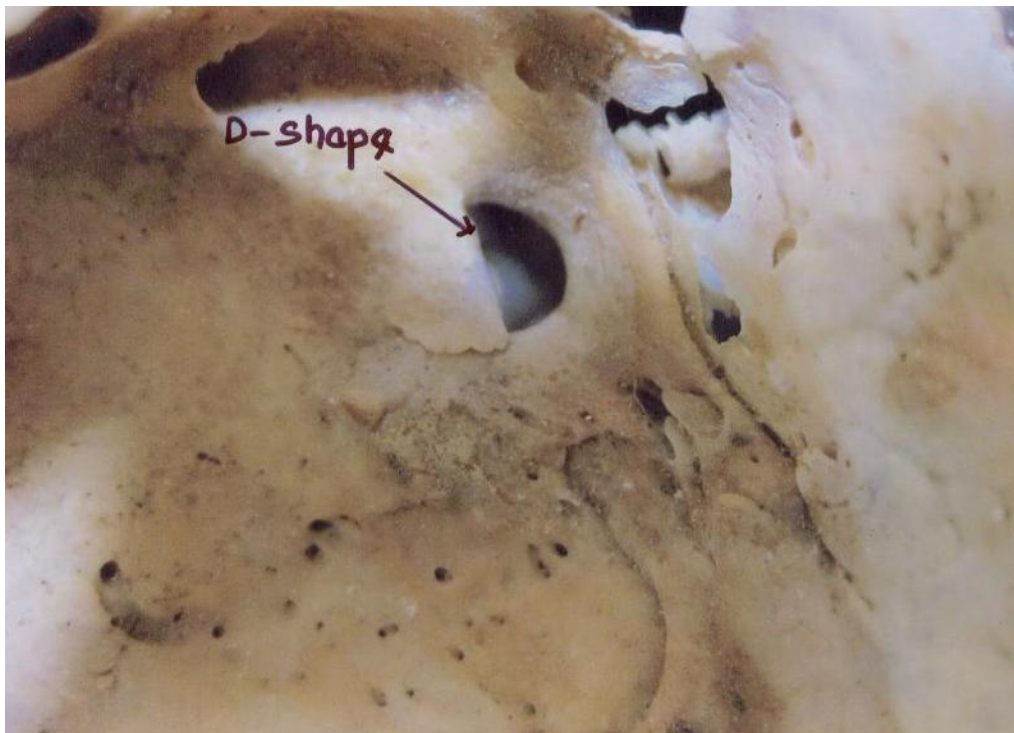


Figure 4: D-Shape on 1 side (1%), seen the foramen ovale, 1 on the right side (2%) and 0 on the left side (0%)

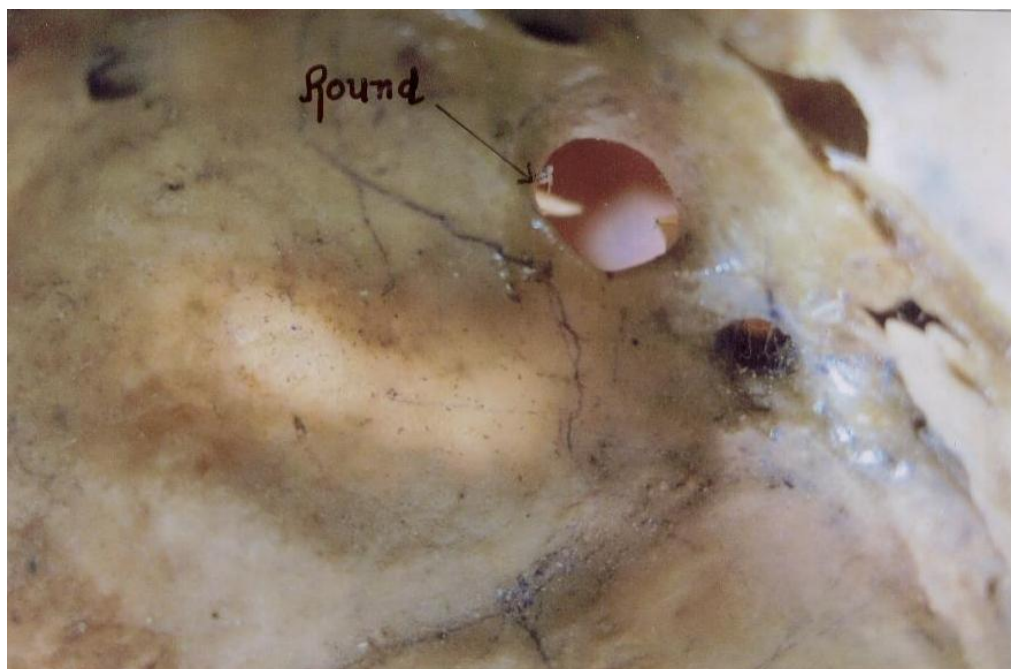

Figure 5: Round in 1 side (1%), seen the foramen ovale, 1 on the right side (2%) and 0 on the left side (0%)

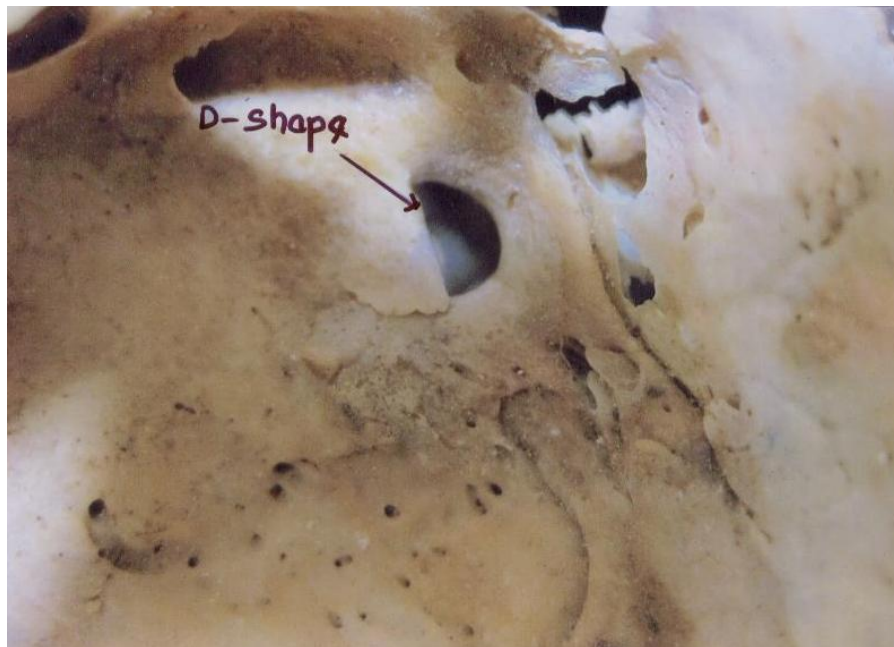


Figure 6: D-shape on 1 side (1%), seen the foramen ovale, 1 on the right side (2%) and 0 on the left side (0%)

Variant foramen ovale was also observed the study. Out of 100 cases 9 cases showed variant foramen ovale, they are:

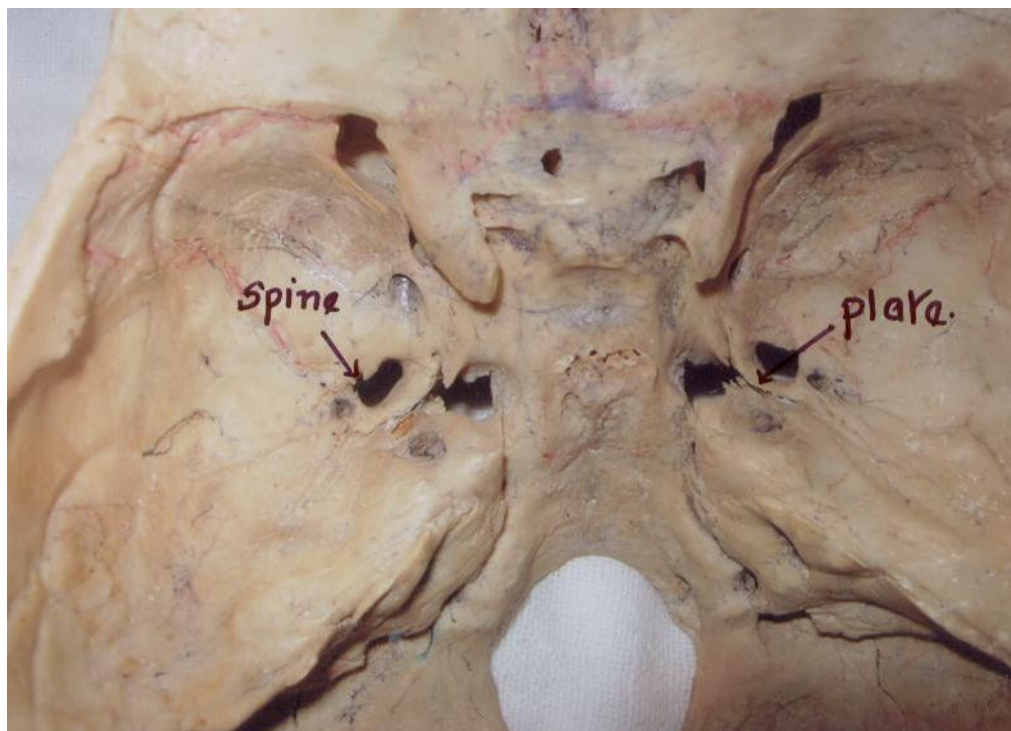


Figure 7: In 2 cases (1 left side) had spine on the margin of foramen ovale and one plate on the right side

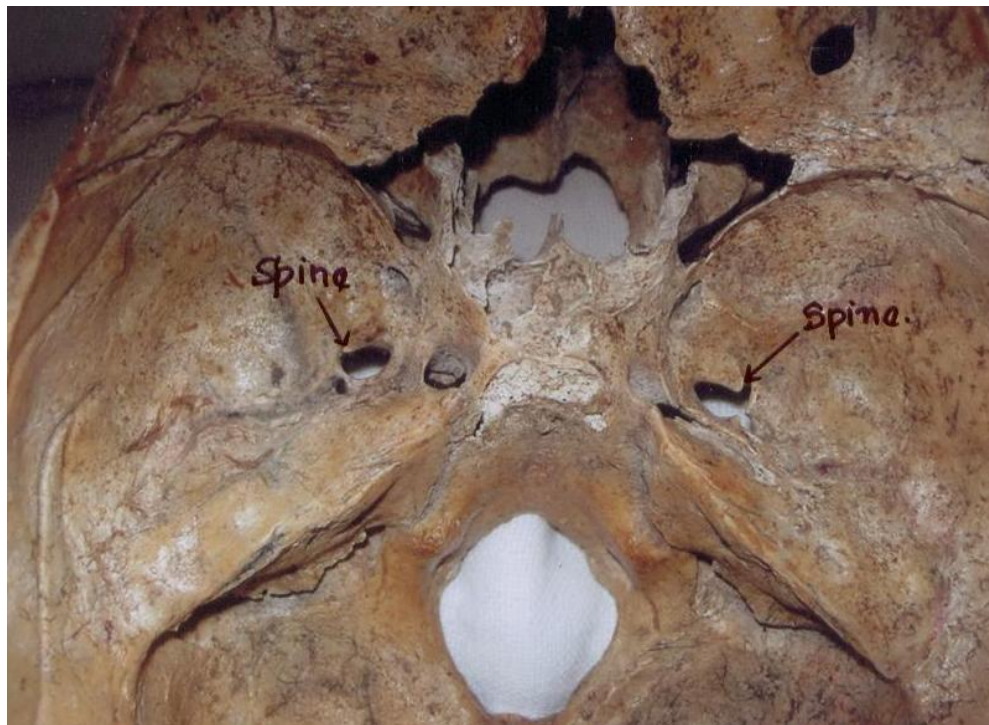


Figure 8: In 1 case had spine on both sides

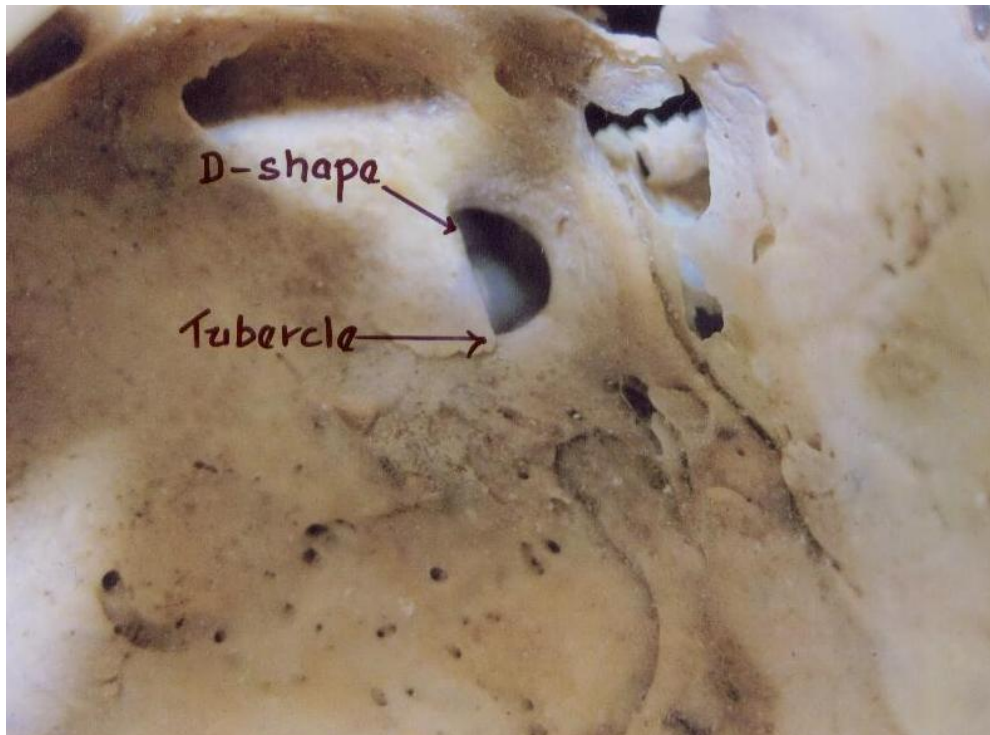


Figure 9: In 1 case left side had tubercle protruding from the margin along with D-shape foramen ovale

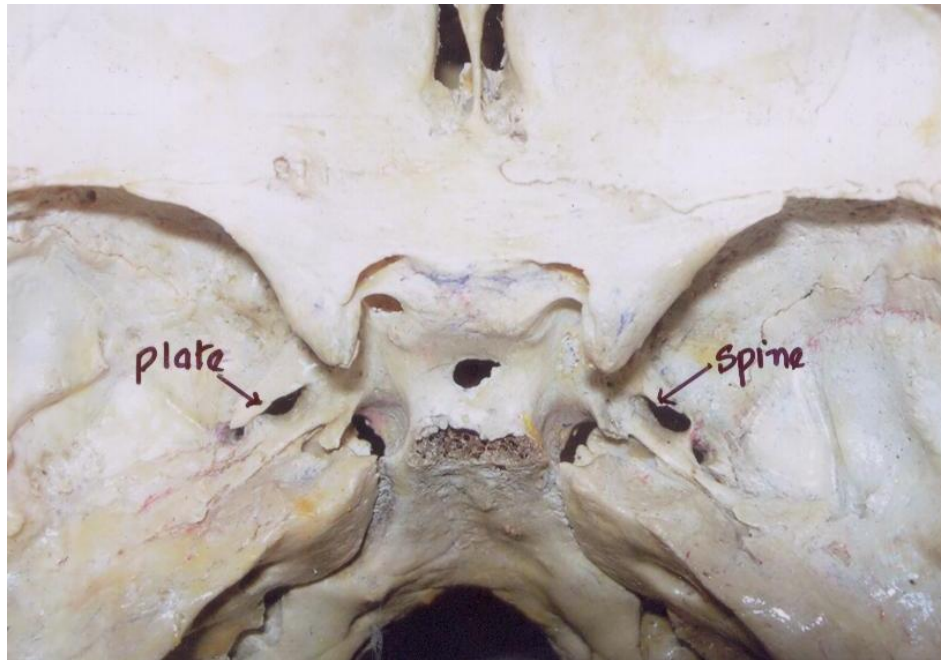


Figure 10: In 2 cases 1 left showed bony plate protruding from the margin of the foramen ovale and 1 spine on right side

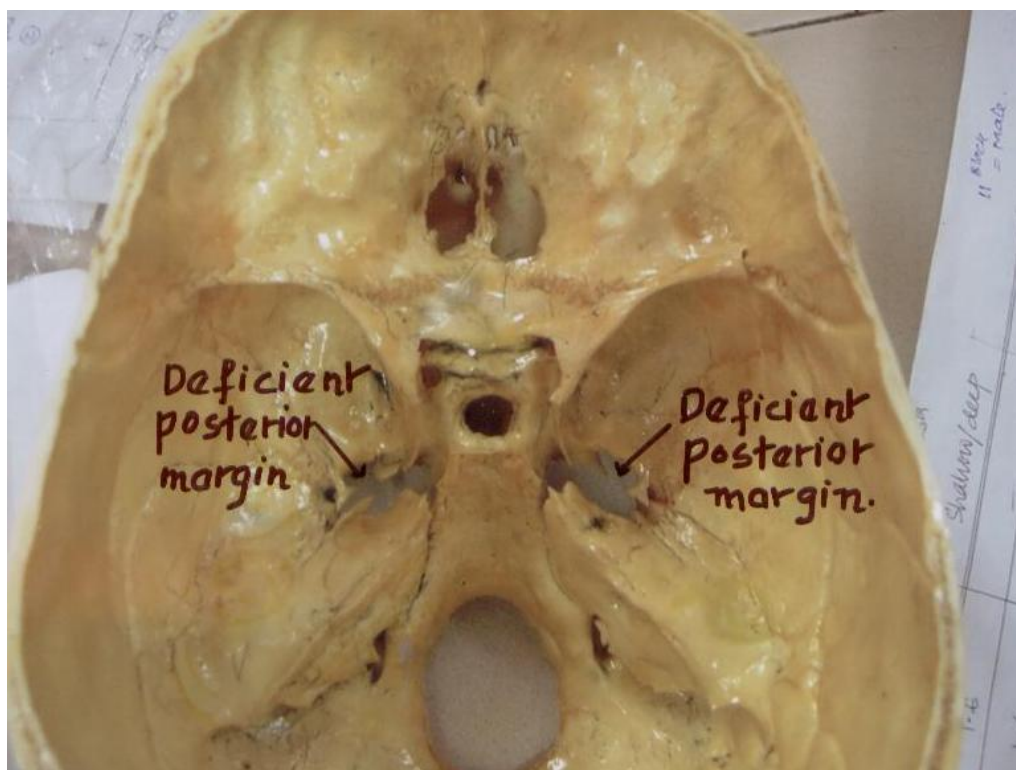


Figure 11: In 1 case showed deficient posterior margin on both sides

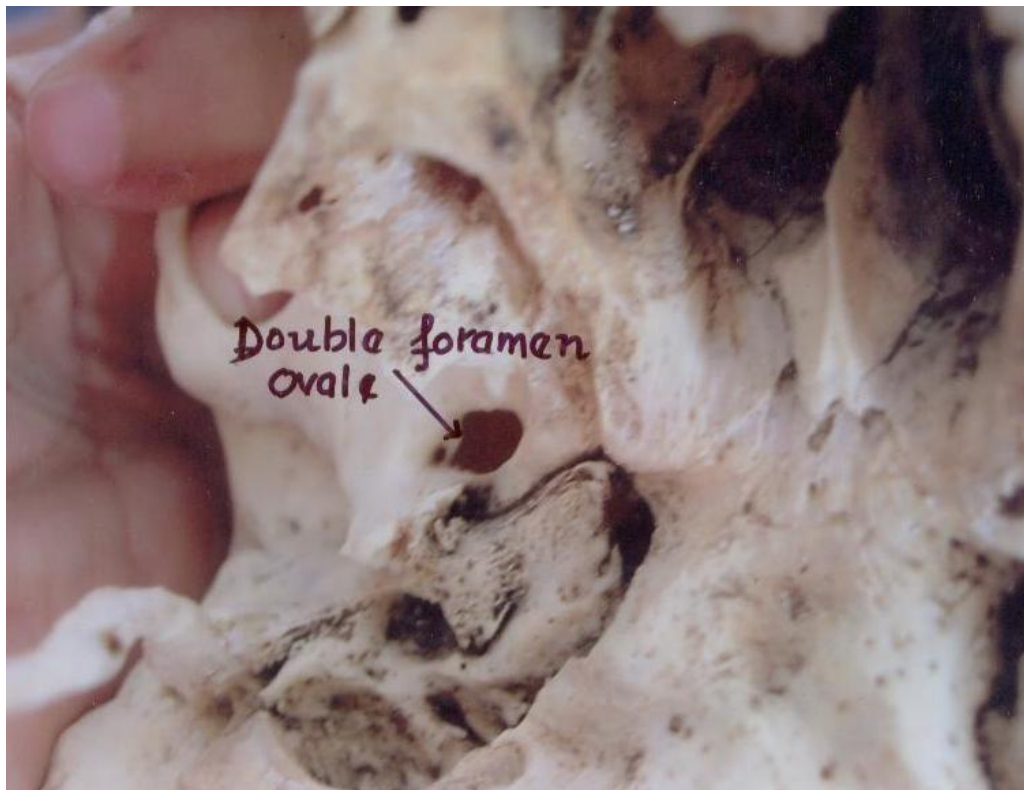

Figure 12: In case 1 (right side) showed double foramen ovale

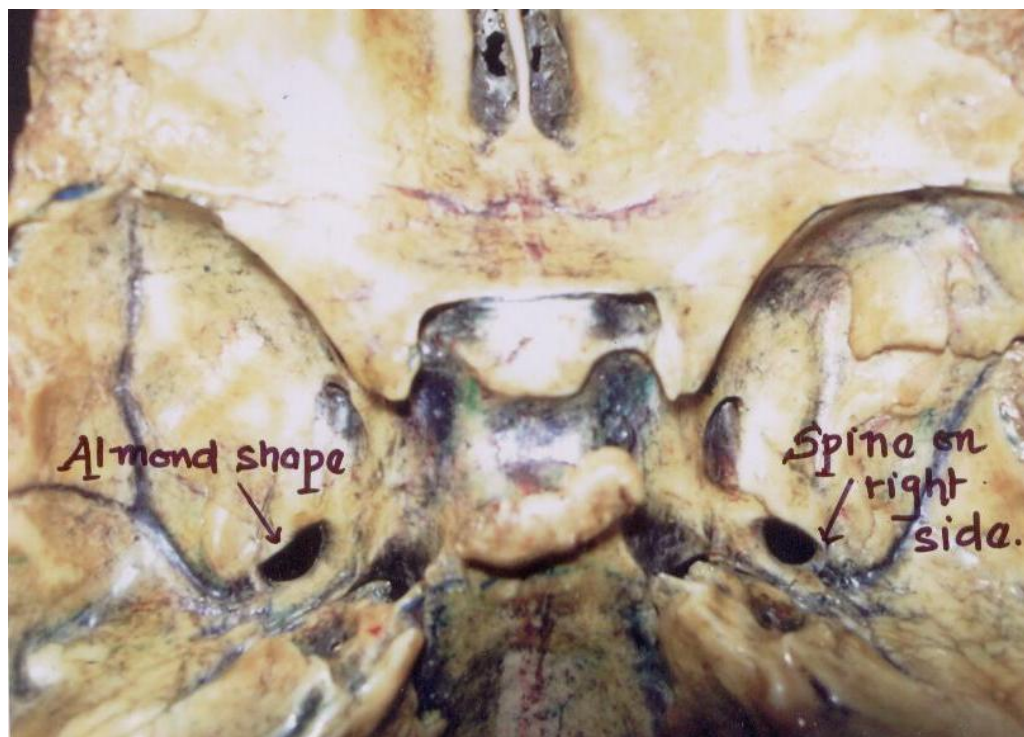


Figure 13: In 1 case showed spine on right side with almond shape

Research Article

RESULTS AND DISCUSSION

Developmentally

Sphenoid bone has two ossification centres namely intramembranous and endochondral ossification centres which consists basisphenoids (body) and orbitosphenoids (paired lesser wings) and alisphenoids (greater wings). Presphenoids and postphenoids centers give rise to Basisphenoids. This is associated with development of greater wing of sphenoid bone. It is in the alisphenoid, the first ossification centers appear and by membranous ossification a large portion of greater wing is formed. Now foramen ovale is formed where mandibular nerve is surrounded by cartilage. Now in the 7th month of intra uterine life, foramen ovale is seen as clear round opening in the area of unossified cartilage. In new born, mean length of foramen ovale is 3.85mm and at of adult is 7.82mm. Its width in new born is 1.81mm and that of adult is 3.7mm (Lang, 1983). It is through foramen ovale many invasive surgical as well as diagnostic procedures electroencephalographic analysis in cases of epileptic fits who are undergoing are being carried out selective amygdalo-hippocampectomy (Wieser and Siegel, 1991). Also in cases of trigeminal neuralgia through microvascular decompression by percutaneous trigeminal rhizotomy (Gerber, 1994; Gusmao *et al.*, 2003) and in tumours of cavernous sinus by percutaneous biopsy (Sindou *et al.*, 1997). Foramen ovale is also used to diagnose squamous cell carcinoma meningioma by technique of CT guided transfacial fine needle. Also for the biopsy of the deep lesions of the brain which reduces the morbidity (Dresel *et al.*, 1991; Barakos and Dillon, 1992). Spine, spur, tubercle, bony plate is various types of bony outgrowths that occur during the development between its first appearance and perfect ring formation (James *et al.*, 1980). It is through foramen, access to the trigeminal nerve is possible. So the position of foramen ovale is of paramount clinical importance during the anaesthesia of mandibular nerve and also in the base of the skull asymmetry (Reymond *et al.*, 2005).

In study conducted by Somesh *et al.*, (2011) dry unknown 82 skulls at Srinivas Institute of Medical Sciences, Mangalore, Foramen ovale were of various shapes they were --in 93 sides they were typical, in 47 sides they were almond shape, in 18 sides they were typically round and they were irregular shaped in 6 sides. There were oval shaped on both sides in 25 on both sides and almond shaped were observed on both sides in 12 sides. So the incidences of oval, almond, round, and irregular of foramen ovale were 56.70%, 28.65%, 10.97% and 3.65% respectively. At the base of the 7 skulls margin of the foramen ovale had the spines (2left, 5right). In 5 skulls there were tubercles protruding from the margin. There were bony lamina extending from lateral pterygoid plate dividing the foramen into two incomplete compartments, a larger medial and smaller lateral compartment which were observed in 2 skulls (Somesh *et al.*, 2011). In Bilodi *et al* studies, 25 unknown human studies were studied at Nepalgunj Medical College, Nepalgunj, Nepal, Showed following findings:

i) Dimension of the foramen ovale

Maximum length of foramen ovale was 9mm, on the left side, and 8.9mm on the right side. Minimum length of foramen ovale was 3.2mm on the left side and 2.9mm on the right side.

Maximum width on both sides the left side was 5mm, while minimum width was 3.21mm plus or minus 1.02 mm on the right side 3.29mm plus or minus 0.85mm

ii) Regarding the Shape of foramen ovale: Foramen ovale showed oval in 40%, Round in 14%, slit like in 12%, Irregular in 24%, Almond in 4%, triangular in 6%.

iii) Regarding the bony growths: Spines in 12%, Tubercles in 12%, Bony spurs in 10%, Plate round the margins in 4%

Present Study

In the present study the mean length of foramen ovale was 7.27+/- 1.41mm on right side and 7.46+/- 1.41 mm on left side. Though left foramen ovale was longer than right no significant difference was observed between the two sides ($P>0.05$). In a developmental study conducted in Japan an average maximum length of the foramen ovale was 7.48mm and average minimal length of the foramen ovale was 4.17mm and difference between the right and left side was not observed which is similar to present study.

Research Article

A German study showed length to be 7.2mm and a fluoroscopically assisted laser targeting of the foramen ovale conducted in New York showed the length to be less compared to present study. They reported 6.9 mm on the right and 6.8 mm on the left side.

According to the present study maximum width of foramen ovale on right side is 5 mm and left side is 5 mm while minimum width was 2 mm on right side and 2.5mm on left side. Mean width on right side was 3.18 mm and left side was 3.21 mm. Difference between the width of right and the left side was not statistically significant ($P>0.05$). Similar finding was observed by a German study where average width was 3.7 mm in adult skull. Average width on right side was 3.4 mm and 3.8 mm on left side was reported in a study conducted by fluoroscopy assisted laser targeting of the foramen ovale in New York.

Variation in the shape of foramen ovale showed maximum number of foramen to be ovale shape (61.4%) followed by almond shape, round shape and D-shape. Similar findings were observed in Japan. They reported that majority of the foramen ovale to be oval in shape and observed that they were irregular in shape compared with the other foramen in the human sphenoid bone. Certain earlier workers have reported bony outgrowth also. A bony spur is located anteriorly and medially according to the Radiojevitc and Javanovic (1956) cited by Lang. Spur was present in 2.8% of the subjects studied.

In the Present Study (4.2%) sides showed spine, at the margin of foramen ovale (12.8%) sides showed bony plate, protruding from the margin of the foramen ovale (4.2%) had a tubercle, protruding from the margin of the foramen ovale (2.8%) had a double foramen ovale (24.0%) had deficient foramen ovale.

Summary

Out of 100 sides in 50 adult human skulls mean length and width of foramen ovale was 7.27 ± 1.41 mm and 3.18 ± 1.02 mm on right and 7.46 ± 1.41 mm and 3.21 ± 1.02 mm on the left side. Shape of the foramen ovale was typically oval in 68 sides (38 on right side and 30 on left side). Almond shape in 31 (14 on right side and 16 on left side). Bilateral oval foramen was observed in 15 cases out of the 100 sides in 50 adult skulls. In 2 cases (1 left side) had spine on the margin of foramen ovale and 1 plate on right side. In 1 case had spine on both sides. In 1 case left side had tubercle protruding from the marginal along with D-shape foramen ovale. In 2 cases (1 left) showed bony plate protruding from the margin of foramen ovale and 1 spine on the right side. In 1 case (right side) showed double foramen ovale. In 1 case showed deficient posterior margin on both side of the foramen ovale. In 1 case showed spine on right side with the almond shape.

Conclusion

From the present study the variant foramen ovale was found was in (24.0%) of the cases in the form of spine, tubercle and bony plate which may seriously hamper the diagnostic and the therapeutic procedures through the foramen ovale. The variant foramen ovale signified over ossification during developmental process. This study is of clinical and anatomical significance to medical practitioners in cases of trigeminal neuralgia and in diagnostic detection of tumour and abnormal bony outgrowth that may lead to ischemia, necrosis and possible paralysis of the parts of the body being supply drained or innervated by the contents of these foramina.

REFERENCES

- Barakos JA and Dillon WP (1992).** Lesions of the foramen ovale: CT-guided fine-needle aspiration. *Radiology* **182** 573-575.
- Błasczyk B, Kaszuba A and Kochanowski J (1980).** Atypical foramina of the base of the skull. *Folia Morphologica* **93** 201-209.
- Dresel SH, Mackey JK and Lufkin RB (1991).** Meckel cave lesions: Percutaneous fine needle-aspiration biopsy cytology. *Radiology* **179** 579-582.
- Gerber AM (1994).** Improved visualization of the foramen ovale for percutaneous approaches to the gasserian ganglion: Technical note. *Journal of Neurosurgery* **80** 156-159.

Research Article

Gusmao S, Oliveira M, Tazinaffo U and Honey CR (2003). Percutaneous trigeminal nerve radiofrequency rhizotomy guided by computerized tomography fluoroscopy: Technical note. *Journal of Neurosurgery* **99** 785–786.

James TM, Presley R and Steel FL (1980). The foramen ovale and sphenoidal angle in man. *Anatomy and Embryology* **160** 93-104.

Kapur E, Dilberović F, Redzepagić S and Berhamović E (2000). Variation in the lateral plate of the pterygoid process and the lateral subzygomatic approach to the mandibular nerve. *Medical Archives* **54** 133–137.

Lang J (1983). Clinical Anatomy of Head Neurocranium, Orbit and Cranio cervical Region, Springer Verlag Berlin.

Lang J, Maier R and Schafhauser O (1984). Postnatal enlargement of the foramina rotundum, ovale et spinosum and their topographical changes. *Anatomischer Anzeiger* **156**(5) 351-387.

Reymond J, Charuta A and Wysocki J (2005). The morphology and morphometry of the foramina of the greater wing of the humansphenoid bone. *Folia Morphologica* **64**(3) 188-193.

Reymond J, Charuta A and Wysocki J (2005). The morphology and morphometry of the foramina of the greater wing of the human sphenoid bone. *Folia Morphologica* **64**(3) 188-193.

Sindou M, Chavez JM and Saint PG (1997). Percutaneous biopsy of cavernous sinus tumours through the foramen ovale. *Journal of Neurosurgery* **40** 106-111.

Bilodi AKS (2006). Some observations of the Foramen ovale and Foramen Spinosum of Human Sphenoid bone, *Journal of Institute of Medicine* **28**(2) 52-56.

Somesh MS, Sridevi HB, Latha V Prabhu, Gangadhara Swamy MS, Ashwin Krishna Murthy, Muralimanju BV, Ganesh Kumar Chettiar (2011). A Morphometric study of Foramen Ovale, *Turkish Neurosurgery* **21**(3) 378-383.

Standring S (2006). The Anatomical Basis of Clinical Practice, Gray's Anatomy, 39th edition. Elsevier Limited 460-462.

Wieser HG and Siegel AM (1991). Analysis of foramen ovale electrode recorded seizures and correlation with outcome following amygdalohippocampectomy. *Epilepsia* **32** 838-850.

Yanagi S (1987). Developmental study of foramen Rotundum, foramen ovale, and foramen Spinosum of the human sphenoid bone. *The Hakkaido Journal of Medical Sciences* **62**(3) 485-496.