

Case Report

RHINOORBITAL MUCORMYCOSIS: A CASE REPORT

Dnyaneshwari P. Ghadage, *Rupali J. Mali, Archana B. Wankhade and Arvind V. Bhore

Department of Microbiology, Smt. Kashibai Navale Medical College and General Hospital,
Narhe (Ambegaon), Pune

*Author for Correspondence

ABSTRACT

In immunocompromised and debilitated patient zygomycosis is the most acute and fulminate fungal infection known. For effective treatment and reduction of morbidity and mortality rate early diagnosis is of utmost importance. Here we report a case of rhinoorbital mucormycosis caused by *Rhizopus oryzae* in 55 year old diabetic housewife. Microbiological and radiological examination established the diagnosis of rhinoorbital mucormycosis ruling out other differential diagnosis like cavernous sinus thrombosis.

Keywords: Rhinoorbital Mucormycosis, *Rhizopus Oryzae*

CASES

A 55 year old housewife with 7 years history of diabetes mellitus which was poorly controlled was transferred to our institute from peripheral hospital. Provisional diagnosis was cavernous sinus thrombosis with diabetes mellitus. She gave history of right sided headache since three months. Right sided facial swelling which gradually increased. She was complaining of pain in right eye, difficulty in opening affected eye since two days.

On examination patient was having right sided facial swelling, proptosis, and ptosis with lid oedema. Right sided eyeball movements were restricted. Corneal sensation was absent, conjunctival chemosis present. Right eye vision was restricted to finger counting. On fundus examination disc edema, retinal edema with haemorrhages was seen. Right maxillary and frontal sinus tenderness was present. Culture of eye discharge was negative. TLC was 24,900. Random blood sugar level was 368mg/dl. In urine examination no abnormality detected. Patient was negative for HIV antibodies. CT PNS Showed small air fluid levels in bilateral maxillary sinuses. Bony walls of sinuses were normal. Right ostio-meatal unit blocked. Bilateral fronto-ethmoidal recesses blocked. Mildly enhancing soft tissue density lesion was seen in superomedial aspect of right orbit with extension in intraconal and extraconal compartments adjacent to lamina papyracea (2.4 x 1 cm) Optic nerve appeared bulky. Bilateral cavernous sinus was normal. The subcutaneous soft tissue of medial supraorbital region was swollen. No intracranial extensions were observed in CT scan. On diagnostic nasal endoscopy left nasal cavity was normal. Right side showed black colored mass which was hard and adhered to lateral wall of nose with pus discharge. Material was curetted (Figure 1) and sent for KOH and fungal culture studies. KOH mount showed broad, nonseptate fungal hyphae with right angled branching. Sporangia were also seen (Figure 2). Culture was done on two sets of Sabouraud's dextrose agar with and without antibiotic one incubated at room temperature and other at 37°C. Within 48 hour cottony white growth was seen. On further incubation colour of colony changed from brownish grey to blackish grey. Lactophenol cotton blue (LPCB) mount showed smooth walled, broad aseptate, fungal hyphae. Branched sporangiophores with globose sporangia containing sporangiospores were seen. Rootlike rhizoids opposite to sporangiophores were seen (Figure 3). For species identification colonies were subcultured and incubated at 40°C and 45°C. No growth at 45°C and good growth at 40°C were observed. Cultural characteristic and morphological features suggested that the isolate is of *Rhizopus oryzae*. Patient was put on antidiabetics and blood sugar level was regularized. Systemic Amphotericin B therapy was given. Patient did not deteriorate further and responded well to treatment.

Case Report

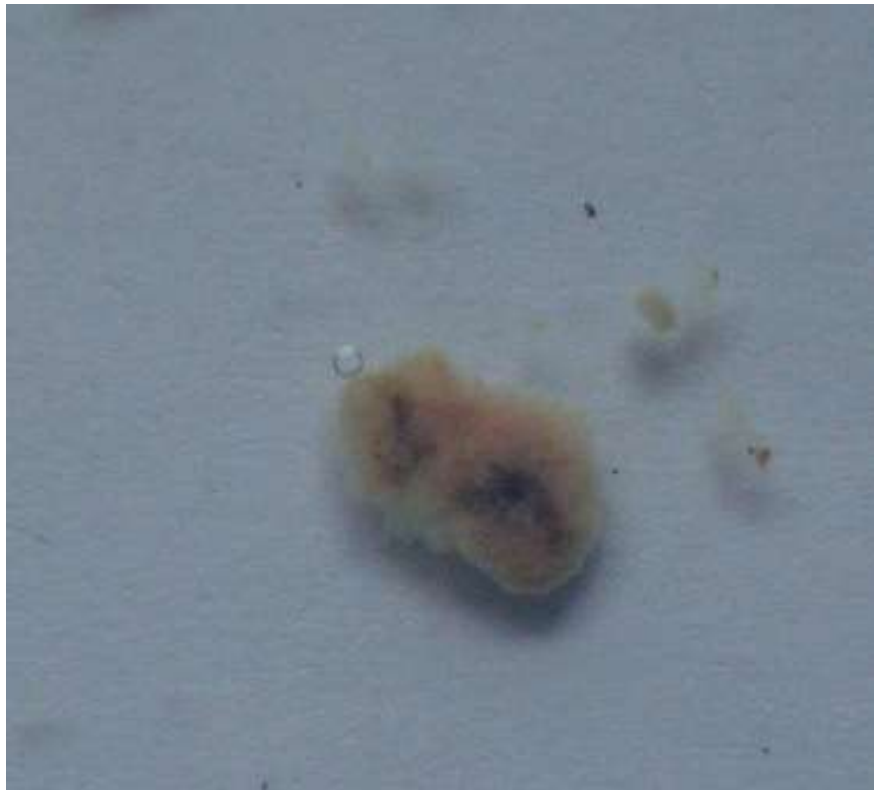


Figure 1: Cured Tissue specimen

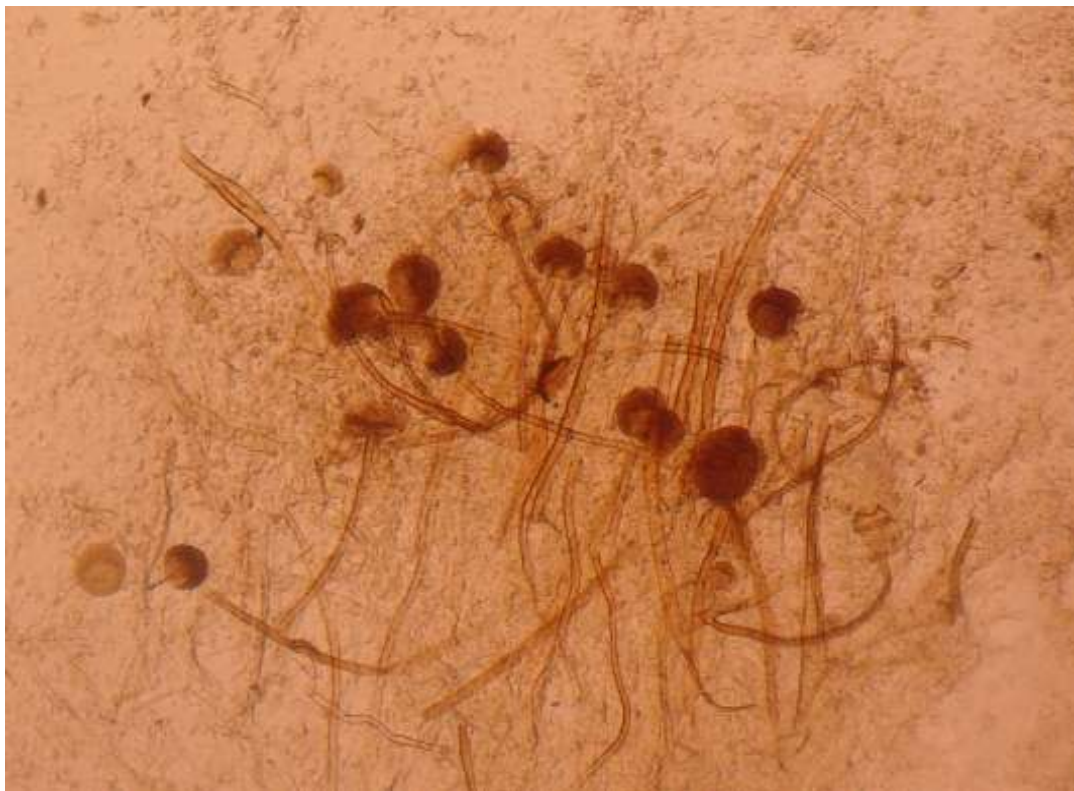

Figure 2: Fungal hyphae and sporangia in KOH mount from specimen

Case Report



Figure 3: Lactophenol cotton blue mount showing rhizoids and sporangia

RESULTS AND DISCUSSION

Filamentous fungi from order mucorales which are ubiquitous in environment can cause angioinvasive infection in patients with diabetes mellitus, chronic renal failure, hematological malignancies and other immunocompromised conditions. Incidence is increasing and mucormycosis ranked third among opportunistic deep fungal infection, after candidiasis and aspergillosis. *Rhizopus* is the most pathogenic species of the family, Mucoraceae. *Rhizopus oryzae* is the predominant pathogen which accounts for 60% of all the forms and 90% of the rhinocerebral cases (Lamia *et al.*, 2008).

In developing countries, like India, mainly in patients with uncontrolled diabetes or trauma such cases are increasingly reported (Petrikkos *et al.*, 2012). Rhino-Orbital Mucormycosis (ROM) is a rare disease with an overall prevalence in 0.15% of the diabetics (Hayat *et al.*, 2011).

Acidosis, hyperglycaemia, decreased ability of neutrophils to phagocytose and adhere to the endothelial walls, marked diabetic patients more prone to mucormycosis (Mathebula 2006). In our case also patient was known diabetic was not compliant for taking antidiabetic drugs.

Early diagnosis and treatment drastically changes the outcome in patients with rhinoorbital mucormycosis. Infection is acquired by inhalation of fungal spores. In paranasal sinuses fungi colonizes and cause disease and spread to adjacent vital organs either by direct or by angioinvasion (Petrikkos *et al.*, 2012).

Like in our case many patients presents with nonspecific signs like facial pain, facial edema, impaired vision, ptosis proptoses, conjunctiva chemosis. Nasal obstruction, discharge, epistaxis, cranial nerve involvement may occur in some patients. Nasal endoscopy provides effective method of examination (Ya-Chun *et al.*, 2002).

CT scan of paranasal sinuses is essential in determining the extent of spread to adjacent vital organs. CT scan will always provide differential diagnosis, but confirmation is done by microbiological and histopathological examination of debrided material (Ghafoor *et al.*, 2005).

Case Report

The principles of management are correction of underlying medical cause, systemic amphotericin B (Greenberg *et al.*, 2006). In our case patient's blood sugar levels were well under control. Patient responded well to treatment with systemic amphotericin B.

In mucormycosis patients nonspecific subtle symptoms may mislead diagnosis, resulting in delayed diagnosis. Radiologic diagnosis though useful, high index of suspicion is necessary, which will in turn direct clinician to perform necessary investigations. This will lead to early and accurate diagnosis with better prognosis.

REFERENCES

Ammari Lamia, Kilani Badreddine and Tiouiri Hanene *et al.*, (2008). Mucormycose: Apropos de quatre observations. *La Tunisie Medicale* **86**(2) 165–68.

Greenberg RN *et al.*, (2006). Posaconazole as salvage therapy for zygomycosis. *Antimicrobial Agents and Chemotherapy* **50** 126.

Hayat Mohd, Mushtak Syed, Saba Sameena and Saif Riyaz (2011). Rhino-orbital-mucormycosis as presenting manifestation of gestational diabetes mellitus. *Indian Journal of Endocrinology and Metabolism* **15**(supplement 1) 65–66.

Mathebula SD (2006). Case report: Rhino-orbital mucormycosis. *The South African Optometrist* **65**(2) 78–81.

Petrikkos G, Skiada A and Lortholary O *et al.*, (2012). Epidemiology and clinical manifestations of mucormycosis. *Clinical Infectious Diseases* **54**(Suppl 1) S23-34.

Tariq Ghafoor, Amer Majeed, Sher Muhammad, Shahid Mahmud and Arshad Mahmood (2005). Rhinocerebral mucormycosis. *Journal of the Pakistan Medical Association* **54**(12) 632-4

Ya-Chun Hsiao, Kun-Wu Tsan and Tao-Yeuan Wang (2002). Rhinocerebral Mucormycosis in Diabetes: A Case Report. *Journal of Internal Medicine of Taiwan* **13** 160-164.