

Case Report

**A RARE CASE OF A SMALL BOWEL PERFORATIONS WITH
MULTIPLE GI FOREIGN BODIES DUE TO DELIBERATE INGESTION
OF INJURIOUS FOREIGN BODIES**

***R. Alagar Samy and R. Purushothaman**

ESIC Medical college and Hospital, Coimbatore, Tamilnadu, India

**Author for Correspondence*

ABSTRACT

Ingestion of foreign bodies (FBs) is a relatively common problem in the United States and India with an estimated incidence of 120 per 1 million population (Ayantunde and Oke, 2006), and is the cause of almost 1500 deaths each year. FB ingestion is a common clinical problem in both adults and children. Swallowed objects may be true FBs such as coins, plastic toys, bones, pins, disc batteries and food bolus that impact in the esophagus (Ayantunde and Oke, 2006). Toddlers are the most affected. Although ingested FBs usually pass through the gastrointestinal tract without any problem, intestinal obstruction and, in less than 1%, perforation may occur (Cossavella *et al.*, 1998). A 64 yr old male presented with hematemesis and melena on and off for 15 days duration. No H/o known psychiatric illness in the past. On evaluation chest x ray and Abdominal x ray erect abdomen revealed multiple foreign bodies from stomach to rectum. The FB are of open safety pins, nail, safety pin head. There is no air under diaphragm in x ray Abdomen erect. Laparotomy and removal of FB done by means of gastrotomy and multiple enterotomies. For sealed perforations with mass of FB at distal jejunum limited resection and anastomosis done. Around 150 FB were removed from the GIT. Post op uneventful. The case is being presented for its rarity.

Keywords: Foreign Body, Safety Pin, Gastrotomy, Resection

INTRODUCTION

The ingestion of foreign bodies is a global problem, affecting a major population and may be associated with a significant morbidity and mortality (Ayantunde and Oke, 2006). The commonest being the food products such as fish bones (Ayantunde and Oke, 2006) and more frequently tooth picks are also reported to be ingested (Cossavella *et al.*, 1998). Although rare in conscious and stable adults, it is fairly a common problem in psychiatric patients (Goh *et al.*, 2006). The morbidity and outcome depends upon the size, shape and nature of the ingested material. The consequences may range from un-noticed passage per rectum to severe peritonitis following bowel perforation and there may be acute bowel obstruction. The perforation of stomach, duodenum or large bowel tends to have a delayed and innocuous presentation compared to the perforation of jejunum and ileum (Karamarkovic *et al.*, 2007).

CASES

A 64 year old male came to surgical emergency ward with the complaints of unique abdominal distension of minimum of 2 days duration with dull aching type of diffuse abdominal pain of the same duration. There was an episode of blood stained vomiting of two to three episodes and melena too. There was no history of altered bladder habits. There was a stunning history from the patient after 4 hours of admission that he had the habit of ingestion hooks, needle, safety pin, nail deliberately over the period of one week. There was a history of passage of hooks and needle while passing stools. He was not a known psychiatric patient. There was no co morbid illness. On per abdominal examination only mild lower abdominal distension with sluggish bowel sounds (Figure 1.1). So we did all the basic investigations which were within normal limits. The chest x ray and abdominal x ray erect revealed the surprise in the form multiple foreign bodies in the gastric region and throughout the abdomen (Figure 1.2). There was no air under diaphragm or fluid levels in the above x rays. Within this short period we performed OGD scopy where by multiple FB noted in the stomach but not able to deliver it out. Hence after adequate hydration and

Case Report

naso gastric tube & Foley’s catheter in situ we took him for an emergency surgery. Under GA/ET, aseptic precautions in a supine position through midline incision abdomen opened in layers. The following are noted as the intra op findings. A) Multiple FB’s in the gastric and distal ileum & sealed perforation of distal ileum (Figure 1.3 and 1.4). Hence we performed removal of FB’s by gastrotomy, multiple enterotomies, 4cm of distal ileum resection and anastomosis (side –side). After perfect hemostasis DT kept and wound closed in layers. Dressing done. The postoperative periods were uneventful and discharged from the ward. Before discharge to prevent future complications psychiatric counselling was given.

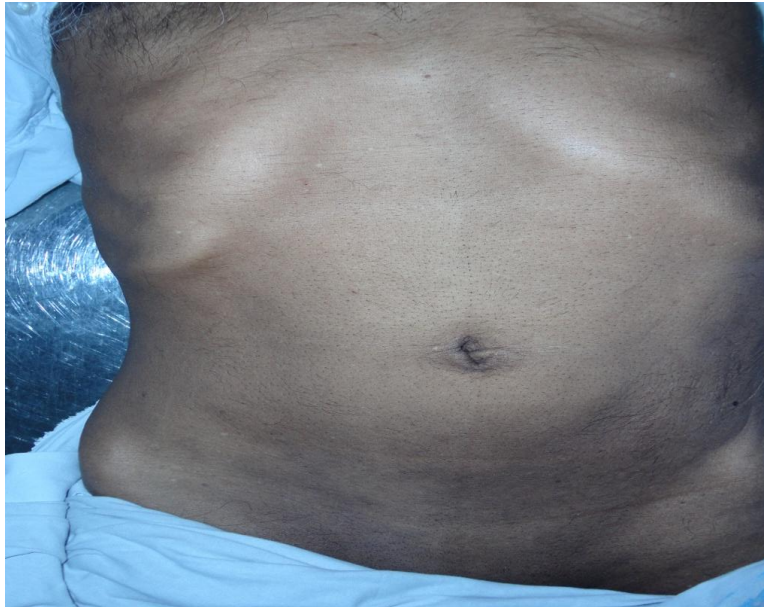

Figure 1.1: Shows preoperative image of the abdomen

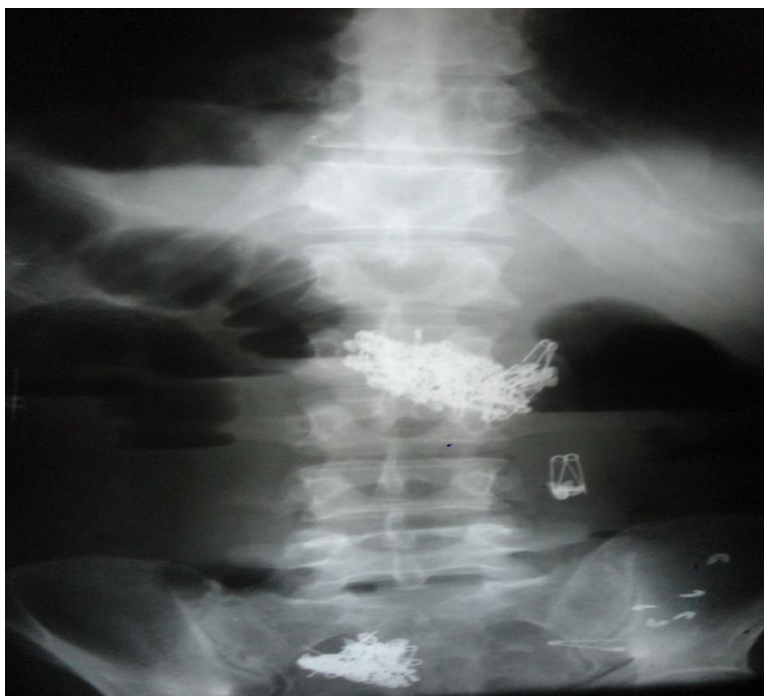

Figure 1.2: Shows x ray abdomen erect with multiple FB in the GIT

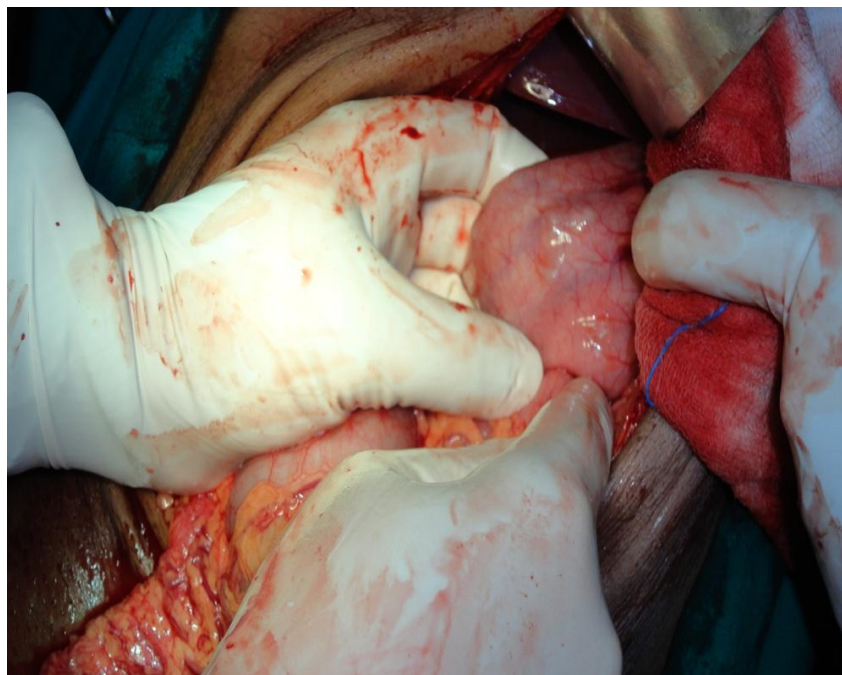


Figure 1.3: Shows the intra operative image of stomach with multiple FB



Figure 1.4: Shows FB's with the excised terminal ileum

DISCUSSION

Deliberate ingestion of foreign bodies constitutes a relatively rare problem in mentally healthy adults (Pintero *et al.*, 2000). However, it is common among children and the commonest ingested foreign body is a coin. The objects with regular and smooth contour may pass easily through GIT without causing any harmful effects. On the contrary sharp and pointed objects may lead to perforation of the bowel with consequent peritonitis and sometimes acute bowel obstruction. Karamarkovic *et al.*, (2007) have reported hepatic abscess secondary to gastric perforation and migration of a rosemary twig into liver. Stomach and duodenum are the commonest site of perforation by the ingested foreign bodies. This is contrary to our report where most of the perforations were found in the terminal ileum, a finding consistent with the

Case Report

reports of Madrona *et al.*, (Pinero *et al.*, 2000; Nagaraj and Sunil, 2005; Velitchkov *et al.*, 1996). Patients who ingest deliberately are usually psychiatric patients, drug abusers, alcoholics, and mentally retarded people (American society for gastrointestinal Endoscopy, 2002) and need a psychiatric evaluation (Weissbeg, 1991). Review of literature reveals a number of such reports in our own country indicating the gravity of the problem (Khan and Ali, 2006; Ali and Khan, 2007). Plain x-ray abdomen is the most accurate diagnostic tool for metallic objects. A detailed history about dietary habits, mental state and personal habits of the patient should be explored in addition to other investigations as needed to reach to a conclusive pre-operative diagnosis. Foreign bodies such as dentures, fish bones, chicken bones, toothpicks and cocktail sticks have been known to cause bowel perforation (Nagaraj and Sunil, 2005). Perforation commonly occurs at the point of acute angulation and narrowing (Velitchkov *et al.*, 1996; American society for gastrointestinal Endoscopy, 2002). The risk of perforation is related to the length and the sharpness of the object (Weissbeg, 1991). The length of the foreign body is also a risk factor for obstruction, particularly in children under 2 years of age because they have considerable difficulty in passing objects longer than 5 cm through the duodenal loop into the jejunum. In infants, foreign bodies 2 or 3 cm in length may also become impacted in the duodenum (Khan and Ali, 2006). The most common sites of perforation are the ileo-cecal junction and sigmoid colon. Other potential sites are the duodeno-jejunal flexure, appendix, colonic flexure, diverticulae and the anal sphincter (Goh *et al.*, 2006). Colonic diverticulitis or previously unsuspected colon carcinoma have been reported as secondary findings in cases of sigmoid perforation caused by chicken bones (Ali and Khan, 2007; Kimbrell *et al.*, 1975). Even colovesical or colorectal fistulas have been reported as being caused by ingested chicken bones (Eldridge, 1961; Cleator and Christie, 1973). The predisposing factors for ingestion and subsequent impaction are dentures causing defective tactile sensation of the palate, sensory defects due to cerebro-vascular accident, previous gastric surgery facilitating the passage of foreign bodies, achlorhydria where the foreign body passes unaltered from the stomach, previous bowel surgery causing stenosis and adhesions and diverticula predisposing to impaction (Goh *et al.*, 2006). Overeating, rapid eating, or a voracious appetite may be contributing factors for ingesting chicken bones. The mean time from ingestion to perforation is 10.4 days (Nandi and Ong, 1978). In cases when objects fail to pass the tract in 3 to 4 weeks, reactive fibrinous exudates due to the foreign body may cause adherence to the mucosa, and objects may migrate outside the intestinal lumen to unusual locations such as the hip joint, bladder, liver, and peritoneal cavity (Nandi and Ong, 1978). The length of time between ingestion and presentation may vary from hours to months and in unusual cases to years, as in the case reported by Yamamoto of an 18 cm chopstick removed from the duodenum of a 71-year-old man, 60 years after ingestion (Nandi and Ong, 1978). Significantly more likely to be febrile with chronic symptoms with a normal total white blood cell count compared to those with foreign body perforations in the jejunum and ileum. Plain radiographs of neck and chest in both antero posterior and lateral views are required in all cases of suspect foreign body ingestion and perforations in addition to abdominal films. CT scans are more informative especially if radiographs are inconclusive (Khan and Ali, 2006). Computerised tomography (CT) scanning and ultrasonography can recognise radiolucent foreign bodies. An ultrasound scan can directly visualize foreign bodies and abscesses due to perforation. The ability to detect a foreign body depends on its constituent materials, dimensions, shape and position (Ali and Khan, 2007). Contrast studies with Gastrograffin may be required in excluding or locating the site of impaction of the foreign body as well as determining the level of a perforation. Using contrast is important in identifying and locating foreign bodies if intrinsically non-radiopaque substances, such as wooden checkers or fish and chicken bones are ingested. The high performance of computed tomography (CT) or multi-detector-row computed tomography (MDCT) scan of the abdomen in identifying intestinal perforation caused by foreign bodies has been well described by Coulier *et al.*, (Kimbrell *et al.*, 1975) Although, in some cases imaging findings can be nonspecific, however, the identification of a foreign body with an associated mass or extraluminal collection of gas in patients with clinical signs of peritonitis, mechanical bowel obstruction, or pneumoperitoneum strongly suggests the diagnosis (American society for gastrointestinal Endoscopy, 2002; Khan and Ali, 2006). Finally, endoscopic examination, especially in the upper gastrointestinal tract,

Case Report

can be useful in diagnosis and management of ingested foreign bodies. Whenever a diagnosis of peritonitis subsequent to foreign body ingestion is made, an exploratory laparotomy is performed. However, laparoscopically assisted, or complete, laparoscopic approaches have been reported (Eldridge, 1961). The treatment usually involves resection of the bowel, although occasionally repair has been described (American society for gastrointestinal Endoscopy, 2002). The most common treatment was simple suture of the defect (Cleator and Christie, 1973). Once the foreign body passes the esophagogastric junction into the stomach, it will usually pass through the pylorus (Nandi and Ong, 1978); however, surgical removal is indicated if the foreign body has sharp points or if it remains in one location for more than 4 to 5 days especially in the presence of symptoms. A decision should be based on the nature of the foreign body in those cases, as to whether a corrosive or toxic metal is ingested (Nagaraj and Sunil, 2005). Occasionally, objects that reach the colon may be expelled after enema administration. However, stool softeners, cathartics and special diets are of no proven benefit in the management of foreign bodies (Velitchkov *et al.*, 1996).

Conclusion

We recommend that the patient's history must be taken precisely to find the cause of acute abdominal pain, and it has considerable impact on the type of management. Foreign body ingestion should be included in the differential diagnosis of abdominal pain and to prevent recurrence patient needs to be counseled and must be under surveillance.

REFERENCES

- Ali W and Khan M (2007)**. Intestinal perforation due to an ingested foreign body. *Journal of the College of Physicians and Surgeons Pakistan* **17**(4) 234.
- American society for gastrointestinal Endoscopy (2002)**. Guidelines for ingested foreign bodies. *Gastrointestinal Endoscopy* **55** 802-6.
- Ayantunde AA and Oke T (2006)**. A review of gastrointestinal foreign goodies. *International Journal of Clinical Practice* **60**(6) 735-9.
- Cleator IG and Christie J (1973)**. An unusual case of swallowed dental plate and perforation of the sigmoid colon. *British Journal of Surgery* **60**(2) 163-5.
- Cossavella D, Clerico G, Paino O and Pozzo M (1998)**. Trompetto M. Intestinal perforation caused by tooth picks. *Minerva Chirurgica* **53**(3) 219-22.
- Eldridge WW Jr (1961)**. Foreign bodies in the gastrointestinal tract. *JAMA* **178** 665-7.
- Goh BK, Chow PK, Quah HM, Ong HS, Eu KW, Ooi LL and Wong WK (2006)**. Perforation of gastro-intestinal tract secondary to ingestion of foreign bodies. *World Journal of Surgery* **30**(3) 372-7.
- Karamarkovic AR, Djuranovic SP, Popovic NP, Bumbasirevic VD, Sijaki AD and Ivan V (2007)**. Hepatic abscess secondary to a rosemary twig migrating from stomach into liver. *World Journal of Gastroenterology* **13**(4) 5530-32.
- Khan AS and Ali U (2006)**. Ingestion of metallic rods and needles. *Journal of the College of Physicians and Surgeons Pakistan* **16**(4) 305-6.
- Kimbrell FT Jr, Tepas JJ and Mullen JT (1975)**. Chicken bone perforation of the sigmoid colon: a report of three cases. *The American Surgeon* **41**(12) 814-7
- Nagaraj HS and Sunil I (2005)**. Multiple foreign body ingestion and ileal perforation. *Pediatric Surgery International* **21**(9) 718-20.
- Nandi P and Ong GB (1978)**. Foreign body in oesophagus: review of 2394 cases. *British Journal of Surgery* **65** 5-9.
- Pinero Madrona A, Fernandez Hernandez JA, Carasco Prats M, Riqueleme J and Parrila Paricio P (2000)**. Intestinal perforations by foreign bodies. *European Journal of Surgery* **166** 307-9.
- Velitchkov NG, Grigorov GI, Losanoff JE and Kjossev KT (1996)**. Ingested foreign bodies of the gastrointestinal tract: retrospective analysis of 542 cases. *World Journal of Surgery* **20**(8) 1001-5.
- Weissbeg D (1991)**. Foreign bodies in the gastro-intestinal tract. *South African Journal of Surgery* **29**(4) 150-3.