

Case Report

A RARE CASE OF COLORECTAL INJURY WITH COMPRESSED AIR

***R. Purushothaman and R. Alagar Samy**

ESIC Medical college and Hospital, Coimbatore, Tamilnadu, India

**Author for Correspondence*

ABSTRACT

Colorectal injuries from implement on solid objects are infrequent but not rare. In the same category are injuries caused by non solid objects. Barotrauma from compressed air and liquid is less frequently encountered. In our opinion it is a unique cause of colonic injury for about 150 cases of colon rupture by compressed air have been described so far. We report a case of 51 years old male presented with the history of insertion of compressed air tube into the anus by his friends for a practical joke. The patient had severe abdominal pain with the frequent desire to defecate since the incident. On examination there was a distension involving the lower abdomen with the diffuse tenderness. His vitals were unstable. Chest x ray and x ray abdomen erect revealed pneumoperitoneum. So we did laparotomy and repair of seromuscular tear at recto sigmoid part of colon. The postoperative period was uneventful and on regular follow up. It is being presented for its rarity.

Keywords: *Colorectal Injury, Compressed Air, Pneumoperitoneum, Barotrauma*

INTRODUCTION

The high pressure air compressor found widespread use, as a result of industrialization, except for the purpose of abuse has been lead to devastating consequences (Zunzunegui *et al.*, 2002; Stone, 1904). Whether it is used as a purpose of sexual assault or practical jokes, exposing to high air pressure through the anus may cause perforation especially in rectum and sigmoid colon or any part of the colon. Colorectal injuries from implement on solid objects are infrequent but not rare. In the same category are injuries caused by non-solid objects. Barotrauma from compressed air and liquid is less frequently encountered (Zunzunegui *et al.*, 2002). We are presenting a case of barotrauma to the colon from compressed air and discuss diagnosis, injury patterns and treatment of this type of injury.

CASES

A 51-year old male came to Surgical Emergency department with history of compressed air tube insertion by his friends for a practical jokes while working in a workshop since he is an industrial worker for more than 25 years. The patient complained of lower abdominal pain and frequent desire to pass stools since the time of incident. No history of vomiting, nausea, respiratory difficulty or difficulty in passing urine. There was no history co-morbid illness. On general examination the patient was uncomfortable, mild dehydration with unstable vitals (tachycardia pulse rate- 100 per minute, Blood pressure – 100/60 mmHg, Respiratory rate – 22 per minute). Per abdominal examination revealed lower abdominal distension with a diffuse tenderness and sluggish bowel sounds. Per rectal examination was normal. All basic blood investigations were normal. The chest x ray and abdominal x ray erect revealed pneumoperitoneum (Figure 1.1).

Since he had been referred from nearby city, came with plain CT abdomen and pelvis with the impression of suspected rectal perforation (Figure 1.2). After adequate resuscitation with intravenous fluids and nasogastric tube insertion, Foleys catheter insertion patient had taken up for emergency laparotomy and proceed. Under regional anaesthesia with all aseptic precautions in a supine position through midline abdominal incision, the abdomen opened in layers. The following findings were noted. 1) While opening the abdomen good amount of air escaped from the abdomen. 2) There were three areas of seromuscular tear of recto-sigmoid part of colon in a longitudinal direction (Figure 1.3 and 1.4). 3) Rest of large and small bowels were normal. 4) There was no peritoneal contamination. 5) The entire bowel were flappy

Case Report

and without any peristalsis. So we did double layer repair of the tear of the above area. After perfect hemostasis wound was closed in layers. Dressing applied over the wound. The postoperative period were uneventful and discharged on 12 th post operative day. Now the patient is on regular follow up.

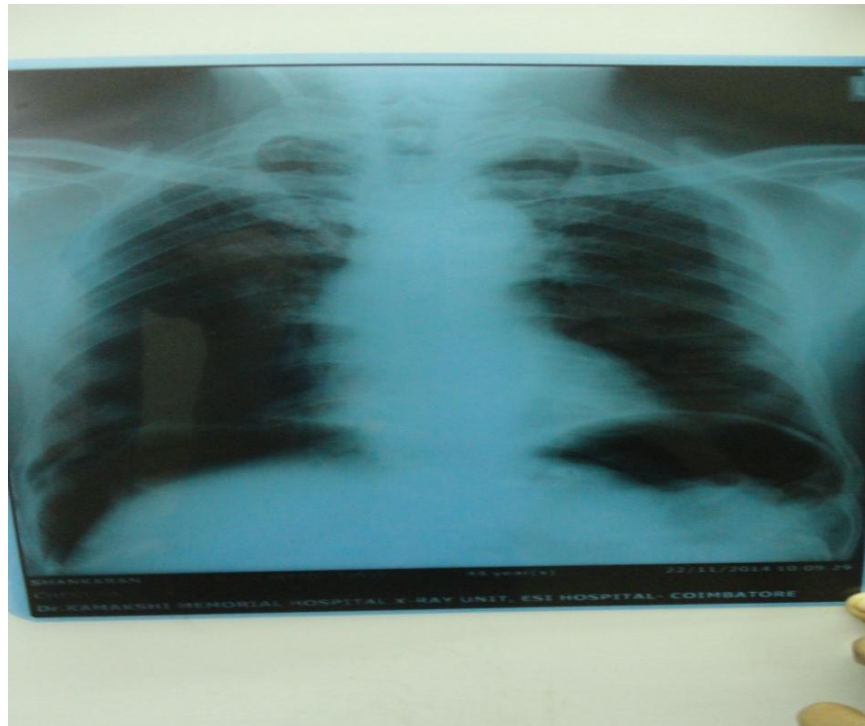


Figure 1.1: Shows the pneumoperitoneum in the chest x ray

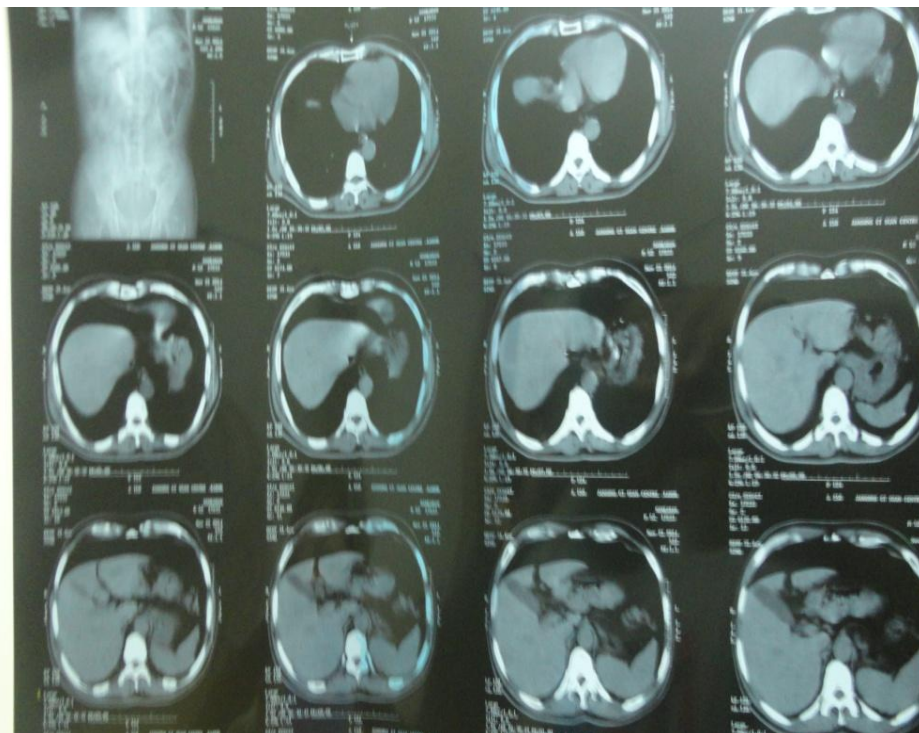


Figure 1.2: Shows plain CT images shows gas dilated large bowel, rectum and Descending colon

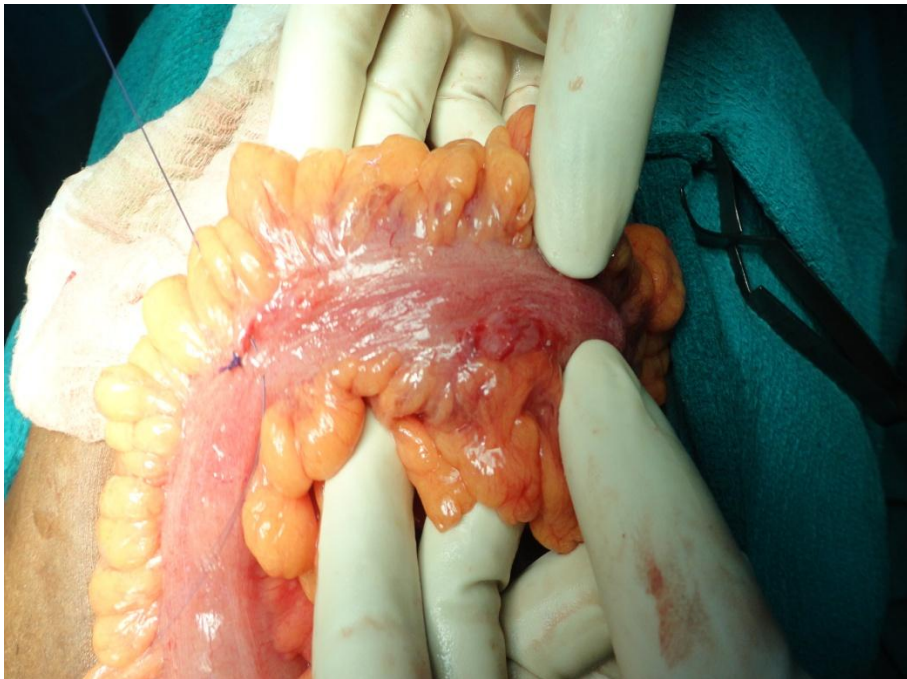


Figure 1.3: Intraoperative image shows the longitudinal seromuscular tear of sigmoid colon

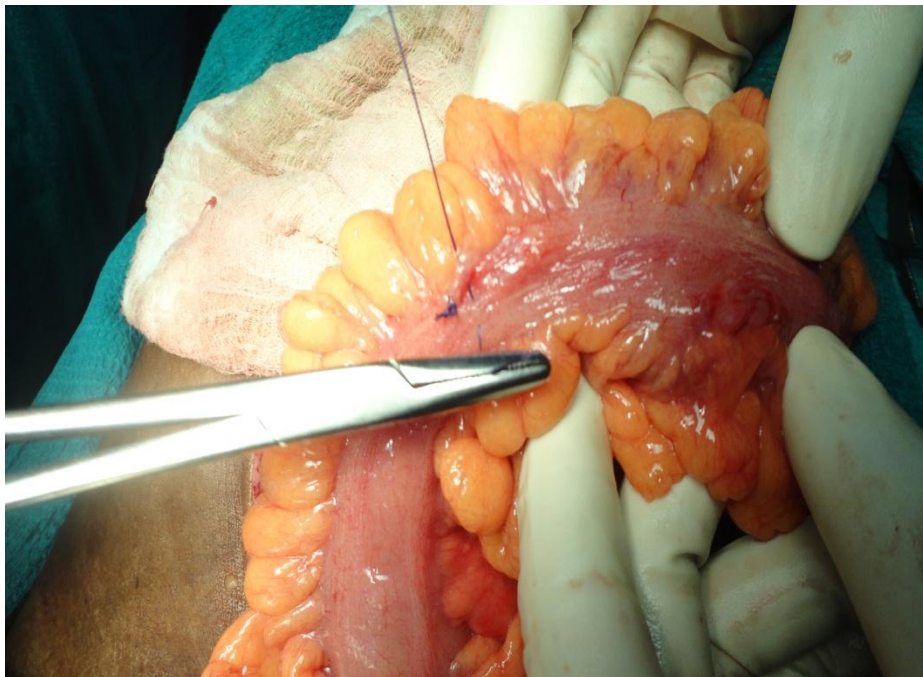


Figure 1.4: Intraoperative image shows the longitudinal seromuscular tear of sigmoid colon

DISCUSSION

Review of the literature reveals a similar case report in 1904 from a British surgeon in London (Stone, 1904). Case analysis of pressurized-air injuries often reveal a misguided coworker and unwise behaviour. Those cases not involving misbehaviour usually occurred when employees used an air hose to dust off their clothing. It is important to realize that this injury can occur without inserting the air hose into the anus (Zunzunegui *et al.*, 2002; Stone, 1904). In several cases reported in the literature the air hose was

Case Report

“fired” through clothes at a distance from the anus (Zunzunegui *et al.*, 2002; Stone, 1904; Andrews, 1911; Suh *et al.*, 1996). The injury caused by pressure effects is called barotrauma. Most of colonic barotrauma are iatrogenic and occurred during a colonoscopy procedure (Zunzunegui *et al.*, 2002). The incidence was reported as 0.058% to 0.5% (Andrews, 1911; Suh *et al.*, 1996; Weber *et al.*, 2011). However colonic injuries with high pressure air compressor which was mostly used in industry sectors are extremely rare (Avallone *et al.*, 2010; Millar, 1988) and was reported especially among the workers around industrial fields as a result of practical joke of colleagues of workers. The first case has been reported by Stone in 1904 (Avallone *et al.*, 2010; Millar, 1988; Chan *et al.*, 1996). Barotrauma cause superficial abrasions like cat scratch in the colon mucosa or perforation that result with serious morbidity and mortality (Brown and Dwinelle, 1942; Choi *et al.*, 2013; Suh *et al.*, 1996). According to Laplace's law, wall tension is directly proportional to the intramural pressure and colon diameter. Therefore colonoscopic barotrauma injuries occurring most commonly in the cecum as a result of its largest diameter (Orsoni *et al.*, 1997). Kozarek and Sanowski showed that the cecum perforated occur at lower pressures (mean, 120 mm Hg) compared to the sigmoid colon (mean, 202 mm Hg) on the cadaver by colonoscopy (Marwah *et al.*, 2002). Reported colon injuries caused by the air compressor in the literature are in different regions but mostly in the recto-sigmoid junction (Zunzunegui *et al.*, 2002; Stone, 1904). This situation is contrary to the law of Laplace. This is because the rectosigmoid junction sensitized with the high air pressure and so perforation in this area will reduce the air passing through proximal of the colon or decrease in the pressure. The rectosigmoid junction is the first part of colon that cannot stand higher pressure while anus, distal rectum are supported with pelvic structures. Intraluminal pressure is not the only reason of intestinal injury, but a sudden and high flow velocity of air at the same time is important (Zunzunegui *et al.*, 2002; Stone, 1904). In the case of delay in diagnose or a sectional colon perforation caused by barotrauma colostomy is recommended. However, in young patients without any signs of peritonitis, resection anastomosis or primary repair may be preferred if no delay in diagnose (Stone, 1904; Andrews, 1911; Brown and Dwinelle, 1942). Although the air pressure can vary in different situations, it takes only 1 or 2 seconds to deliver enough pressurized air to cause major damage. The rupture usually occurs in a longitudinal direction along the muscle fibers with full thickness perforation or with stripping of the serosa and muscularis. The most common injury location is the anti-mesenteric surface of the sigmoid colon (Zunzunegui *et al.*, 2002). Some patients may withhold information, trying to protect the guilty party or due to embarrassment. In such cases, the general symptoms are abdominal pain, abdominal distension, rectorrhagia, tachycardia, tachypnoea. Tension pneumoperitoneum is a characteristic presentation (Zunzunegui *et al.*, 2002; Weber *et al.*, 2011; Avallone *et al.*, 2010). Death can depend on acute air embolism, acute fat embolism, acute respiratory insufficiency due to enhanced intra-abdominal pressure and chest compression, acute heart failure due to insufficient preload and peritoneal shock (Weber *et al.*, 2011). Percutaneous decompression of the tension pneumoperitoneum can be accomplished by inserting a cannula or a Veress needle into the abdomen for relief of the pressure (Millar, 1988). Sixteen-gauge angiocath was inserted percutaneously in the right upper quadrant of the abdomen for decompression with alleviation of respiratory and hemodynamic problems (Chan *et al.*, 1996). The overall mortality of pneumatic rupture of the bowel was 65%. If the acute shock was not immediately fatal, the survival was depending from further treatment. Surgery reduced mortality to 42% ⁹.

Conclusion

Compressed air related colorectal injuries are rare conditions admitted to emergency departments. Although taking history sometimes is not possible due to factors related with patients' condition, physical and radiological findings related with tension pneumoperitoneum can make physician diagnose injury and etiology. Consequently, colonic injuries occur with a high pressure air compressor are reported especially in the industrial zones. If a patient who worked in this business segment is presented with abdominal distension and pain, perforation of colon by barotrauma should be considered in the differential diagnosis of peritonitis. Though it has high morbidity and mortality rates, surgery reduce the mortality, so operation decision must be made as quickly as possible. Resection-anastomosis will be appropriate treatment in the early period of perforation in young patients.

Case Report

REFERENCES

- Andrews EW (1911)**. Pneumatic rupture of the intestine: a new type of industrial accident surgery. *Gynecology and Obstetrics* **12** 63–64.
- Avallone S, La Torre M and Meurette G (1988)**. Rectal injury by compressed air. *The Journal of Trauma* **68**(1) 248.
- Brown RK and Dwinelle JH (1942 and 1994)**. Rupture of the Colon by Compressed Air: Report of Three Cases. *Annals of Surgery* **115**(1) 13-20, **37**(5) 496-502.
- Chan SY, Kirsch CM, Jensen WA and Sherck J (1996)**. Tension pneumoperitoneum. *The Western Journal of Medicine* **165**(1-2) 61-64.
- Jin Yi Choi et al., (2013)**. 'Colon Barotrauma Caused by Compressed Air. *Intestinal Research* **11**(3) 213-216.
- Marwah S, Gupta R, Singh I and Marwah N (2002)**. Compressed air injury of the colon-delayed presentation. *Indian Journal of Gastroenterology* **21** 206-207.
- Millar DM (1988)**. Tension pneumoperitoneum: a simple solution. *British Journal of Hospital Medicine* **40**(2) 149.
- Orsoni P, Berdah S and Verrier C et al., (1997)**. Colonic perforation due to colonoscopy: a retrospective study of 48 cases. *Endoscopy* **29** 160-164.
- Stone GW (1904)**. Rupture of the bowel caused by compressed air. *Lancet* **2** 216.
- Suh HH, Kim YJ and Kim SK (1996)**. Colorectal injury by compressed air--a report of 2 cases. *Journal of Korean Medical Science* **11**(2) 179-182.
- Tulchinsky H et al., (2006)**. Incidence and management of colonoscopic perforations: 8 years' experience. *The World Journal of Gastroenterology* **12**(26) 4211-4213.
- Weber M, Kolbus F, Dressler J and Lessig R (2011)**. Survived ileocecal blowout from compressed air. *International Journal of Legal Medicine* **125**(2) 283-287.
- Zunzunegui RG, Werner AM, Gamblin TC, Stephens JL and Ashley DW (2002)**. Colorectal blowout from compressed air: case report. *The Journal of Trauma* **52**(4) 793-795.