

Case Report

A SURPRISE IN THE CIRCUMCISED ADULT FOR ACQUIRED PHIMOSIS

*Alagar Samy R.

ESIC Medical College and Hospital, Coimbatore, Tamilnadu, India

*Author for Correspondence

ABSTRACT

Penile verrucous carcinoma is a rare, low-grade penile squamous cell carcinoma (SCC) exhibiting slow invasive growth. Regional lymph node metastasis is rare and distant metastasis has yet not been reported (Stankiewicz *et al.*, 2009). Penile verrucous carcinoma accounts for 5 to 24% of all penile malignancies and represents 5 to 16% of all penile SCC (Noel *et al.*, 1992). A 75 year old male presented with complaints of swelling in the groin on both side for two years duration with difficulty in retracting his foreskin for the same period. On basic investigations nothing abnormal except newly detected diabetes on treatment. Then the patient underwent bilateral Lichensteins tension free mesh repair with circumcision by dorsal slit method. The circumcised specimen sent for histopathological examination which came as Verrucous type of squamous cell carcinoma. The post operative period was uneventful and discharged on sixth post operative period. It is being presented for its rarity.

Keywords: Penis, Surgery, Verrucous Carcinoma, Hernia

INTRODUCTION

Penile verrucous carcinoma is a rare, low-grade penile squamous cell carcinoma (SCC) exhibiting slow invasive growth. Regional lymph node metastasis is rare and distant metastasis has yet not been reported (Stankiewicz *et al.*, 2009). Penile verrucous carcinoma accounts for 5 to 24% of all penile malignancies and represents 5 to 16% of all penile SCCs (Noel *et al.*, 1992). The novel knowledge and experience of the treatment of penile verrucous carcinoma will be a useful clinical guide for surgeons in the future.

CASES

A 75-year-old male came to surgical outpatient department with a occasional painful reducible swelling in both groin of two years duration. The patient had the swelling in both groin of two years duration which was started as a small one gradually increased over a period of two years. Initially it was not painful but for the past two months it was painful. Over a period of two years there was difficulty in retracting his foreskin. No symptoms suggestive of obstruction of bowels like constipation, vomiting. No history of difficulty in passing urine or stools. There was no history of burning micturition. He was a newly diagnosed diabetic on treatment. On General Examination a single spherical shaped swelling of about 7x6 cms sized on both side of inguinal region. The swelling was soft in consistency with expansile cough impulse on both side.

The skin over the swelling was not warm and no discoloration. The bowel sounds were normal. On external genitalia examination there was phimosis without any palpable growth. All the basic blood investigations were normal except high blood sugar for which started treatment. So we took up for elective surgery after proper correction of blood sugar under regional anaesthesia. Through right inguinal incision skin, subcutaneous layers incised.

Right inguinal canal opened and separated the sac from right sided cord structures. The sac was pushed inside of the abdomen since it was a direct sac. The posterior wall of inguinal canal repaired with 6x11 cms prolene mesh. After perfect hemostasis wound was closed in layers. The similar procedure done in left side too. Then circumcision done by dorsal slit method and the specimen of prepuce sent for HPE. Dressing done with scrotal bandage (Figure 1.1).

Post operative period was uneventful and the patient discharged on sixth post operative day and doing fine. The surprise came in the form of HPE report and reported as verrucous type of squamous cell carcinoma with negative margins and without any lymphovascular invasion. Then we did the contrast

Case Report

enhanced CT to rule out any inguinal lymphode metastasis but nothing was found. At present patient doing fine and on regular follow up (Figure 1.2).

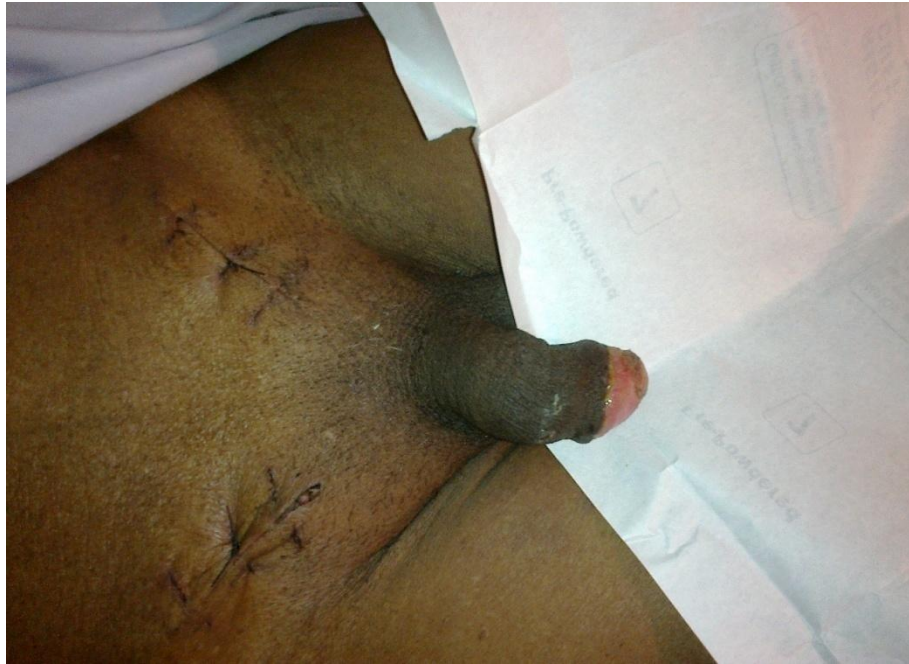

Figure 1.1: Post op image of the wound

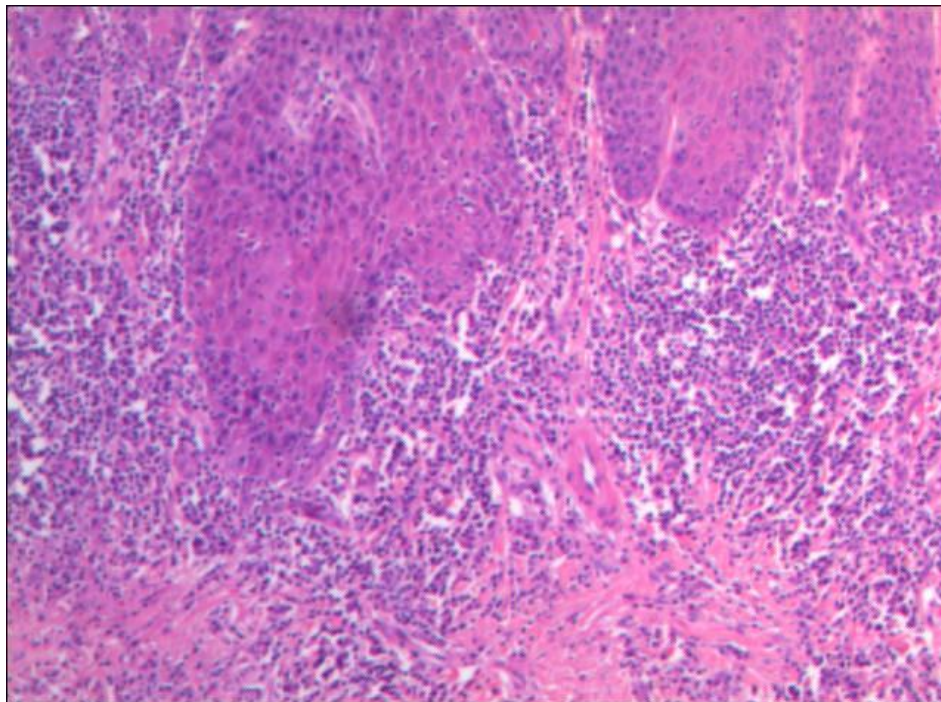


Figure 1.2: HPE slide shows verrucous carcinoma of penis

DISCUSSION

Verrucous carcinoma is an uncommon, exophytic, low-grade and well-differentiated variant of SCC with slow invasive growth and without any distant metastasis. Its presence was first described in 1948 by

Case Report

Ackerman in the oral cavity (Ackerman, 1948). Since then it has been also described at other sites, including the anus, female genitalia, penis, soles and at any location on the skin (Schwartz, 1995). Verrucous carcinoma is also known by several other names, e.g., giant condyloma acuminatum or Buschke-Lowenstein tumor (Rinker *et al.*, 2001). However, some researchers consider giant condyloma acuminatum or Buschke Loewenstein tumor as a distinct disease which only represents an intermediate condition between condyloma acuminatum and verrucous carcinoma (Antony *et al.*, 2003; Gross and Pfister, 2004). Currently, the common opinion is that both the lesions are similar and should not be separated into two different entities (Hatzichristou *et al.*, 2001).

The specific etiologic factors of penile verrucous carcinoma remain unclear. Predisposing factors include lack of circumcision, poor hygiene, phimosis, tight prepuce and chronic infection. However, no systematic case series have been studied so far (Sheen *et al.*, 2003). It has been reported that penile SCC can arise in males circumcised at birth. Thus, the preventive effect of newborn circumcision on the development of penile SCC is still unclear (Micali *et al.*, 2006). Kanik *et al.*, (1997) once described penile verrucous carcinoma in a 37-year-old white man who had been circumcised in infancy without any predisposing penile anatomic abnormalities. Additionally, as per the earlier studies, human papillomavirus (HPV) infection, especially the low-risk types, HPV-6 and HPV-11, play a vital role in the pathogenesis of the tumor (Majewski and Jablonska, 1997). However, other studies have not found a significant association between penile verrucous carcinoma and HPV (Stankiewicz *et al.*, 2009; Schwartz, 1995; Pilotti *et al.*, 1993).

Clinically, penile verrucous carcinoma arises anywhere on the penis, mostly on the glans or foreskin as a gradually enlarging, exophytic, papillary, cauliflower-like or verrucous mass which may be foul smelling and sometimes ulcerated, with fistulae that release a purulent discharge. Shaft involvement is less frequent in such a condition. In rare cases, it may resemble a penile horn. Microscopic histopathologic appearance should be carefully identified so as to differentiate penile verrucous carcinoma from condyloma acuminatum and penile SCC. Microscopically, penile verrucous carcinoma is a very well differentiated papillary neoplasm with acanthosis and hyperkeratosis. It is classified as Ta stage according to the TNM staging system (Eble *et al.*, 2004). Surgical excision, sparing as much of the penis as possible is the usual treatment for penile verrucous carcinoma.

Local excision and partial penectomy are most commonly used (Wein *et al.*, 2007). Hatzichristou *et al.*, (2001) suggested that glanssectomy is an appropriate treatment for patients with penile verrucous carcinoma confined exclusively to the glans penis and that more radical techniques (e.g., partial or total penectomy) are reserved as second-line treatments for cases of local recurrence. Regardless of any operative strategies, the negative surgical margins must be ensured. The presence and the extent of metastasis to the inguinal region are the most important prognostic factors for survival in patients with squamous penile cancer (Wein *et al.*, 2007). Additionally, lymphadenectomy was found to be associated with a significant risk of morbidity. This section summarizes the choices available according to the stage of the cancer.

Stage 0

Stage 0 includes 2 types of tumors: carcinoma in situ and verrucous carcinoma. They are treated differently. Patients with carcinoma in situ that is only in the foreskin can often be treated with circumcision. If the tumor developed in the glans and does not affect other tissues, it may be possible to treat it with topical therapy (such as 5-FU cream or imiquimod) or Mohs (microscopically directed) surgery. Laser treatment, cryotherapy, and radiation therapy are also possible options. Penectomy is not often needed. Verrucous carcinoma can often be treated with laser therapy, cryotherapy, or Mohs surgery. Only rarely will penectomy be needed. Radiation is not used for this type of tumor, because it can make it more likely to spread.

Stage I

These tumors have grown below the skin of the penis but not into deeper layers. Options for treatment may include circumcision (for tumors confined to the foreskin), surgical removal of part of the penis (partial penectomy), radiation therapy and Mohs surgery. Laser surgery may also be an option.

Case Report

Stage II

Stage II penile cancer includes tumors that have grown into the tissues of the penis (such as the corpus spongiosum or cavernosum) or the urethra, but have not spread to nearby lymph nodes. These cancers are usually treated with a **partial or total penectomy**, with or without **radiation therapy**. A less common approach is to use radiation therapy as the first treatment with surgery remaining as an option if the cancer is not completely destroyed by the radiation. Radiation may also be used as the main treatment in men who cannot have surgery due to severe medical problems.

Some doctors recommend checking groin lymph nodes, even if they are not enlarged. This may be done with a **sentinel lymph node biopsy** or with a more extensive lymph node dissection. If the lymph nodes show cancer spread, then the cancer is not really a stage II. It is a stage III or IV.

Stage III

Stage III penile cancers include T1, T2, and T3 tumors that have spread to nearby lymph nodes (N1 or N2). Stage III includes tumors that have grown into the corpus spongiosum, corpus cavernosum, or urethra, but not tumors that have grown into nearby structures like the bladder or prostate. Stage III cancers are treated with a **partial or total penectomy**. In a few cases, **chemotherapy** (chemo) or chemo plus **radiation** may be used first to shrink the tumor so that it can be more easily removed with surgery. These cancers require an inguinal lymphadenectomy to remove lymph nodes in the groin. Radiation therapy to the groin may be used as well, either after surgery or instead of surgery in selected cases. These tumors can be hard to treat, so men may want to consider taking part in **clinical trials** of new treatments.

Stage IV

Stage IV penile cancer includes cancers that have spread to nearby tissues, like the prostate, bladder, scrotum, or abdominal wall (T4). Treatment may include **surgery** to remove the main tumor, such as penectomy. If the tumor is in the scrotum or parts of the abdominal wall, it may also be necessary to remove the testicles and/or the scrotum. A new opening can be made in the abdomen or the perineum to allow urination. If the tumor has grown into the prostate or bladder, these may need to be removed, as well. **Chemo** (sometimes with **radiation**) may be given before surgery (this is called *neoadjuvant* treatment) to try to shrink the tumor and make it easier to remove. The inguinal (groin) lymph nodes on both sides will be removed as well. This area may also be treated with radiation after surgery (unless it was given before surgery). Stage IV also includes smaller cancers with more extensive spread to the lymph nodes (N3), such as cancer in groin lymph nodes that has grown through the lymph nodes' outer covering and into surrounding tissue or cancer spread to lymph nodes inside the pelvis. This stage is treated with surgery to remove the main tumor in the penis, such as penectomy. The lymph nodes in both groins are also removed. The lymph nodes inside the pelvis is also removed if they are thought to contain cancer spread (if they are enlarged, for example). After the lymph nodes are removed, those areas are often treated with radiation to try to kill any cancer cells that may have left behind (but are too small to see). Penile cancer that has spread to distant organs and tissues is also considered stage IV. This is usually not considered curable by current methods. Treatment is designed to try to keep the cancer in check and to prevent or relieve symptoms to the best extent possible. Choices to treat the penile tumor usually include wide local excision, penectomy, or radiation therapy. Surgery or radiation therapy may also be considered to treat nearby lymph nodes. Radiation may also be used to treat areas of cancer spread in the bones or in the brain or spinal cord. Chemo may be used to treat cancer that has spread to other areas, like the lungs or liver. Studies are under way to determine the value of chemotherapy combined with surgery or radiation therapy.

Stage IV cancers are hard to treat, so men may want to think about taking part in clinical trials of new treatments.

Recurrent Cancer

The treatment of recurrent cancer depends on where the cancer comes back and what treatments were used before. If penectomy was not done before, a recurrent penile cancer may be treated with surgical removal of the penis. **Radiation therapy** may also be an option. **Surgery** and/or radiation may also be options for some cancers that recur in the lymph nodes. **Chemotherapy** may be helpful in treating more

Case Report

advanced recurrent penile cancers. These tumors can be hard to treat, so men may want to think about taking part in a clinical trial of a newer treatment.

Conclusion

Verrucous carcinoma is a rare, locally aggressive tumor. Surgical complete excision of VC is advised. Other treatment modalities such as chemotherapy or radiotherapy could be used rarely to avoid mutilating surgical interventions. After complete surgical excision with negative margin with regular follow up is mandatory in all cases of verrucous carcinomas. We present this case for its rarity and underlying the importance of sending the specimen of prepuce after circumcision in the male patients of the middle age group.

REFERENCES

- Ackerman LV (1948).** Verrucous carcinoma of the oral cavity. *Surgery* **23** 670–678.
- Antony FC, Ardern-Jones M, Evans AV, Rosenbaum T and Russell-Jones R (2003).** Giant condyloma of Buschke-Loewenstein in association with erythroderma. *Clinical and Experimental Dermatology* **28** 46–49.
- Eble JN, Sauter G, Epstein JI and Sesterhenn IA (2004).** *World Health Organization Classification of Tumours: Pathology and Genetics of Tumours of the Urinary System and Male Genital Organs* (Lyon: IARC Press).
- Gross G and Pfister H (2004).** Role of human papillomavirus in penile cancer, penile intraepithelial squamous cell neoplasias and in genital warts. *Medical Microbiology and Immunology* **193** 35–44.
- Hatzichristou DG, Apostolidis A, Tzortzis V, Hatzimouratidis K, Ioannides E and Yannakoyorgos K (2001).** Glanslectomy: an alternative surgical treatment for Buschke-Löwenstein tumors of the penis. *Urology* **57** 966–969.
- Kanik AB, Lee J, Wax F and Bhawan J (1997).** Penile verrucous carcinoma in a 37-year-old circumcised man. *Journal of the American Academy of Dermatology* **37** 329–331.
- Majewski S and Jablonska S (1997).** Human papillomavirus-associated tumors of the skin and mucosa. *Journal of the American Academy of Dermatology* **36** 659–685.
- Micali G, Nasca MR, Innocenzi D and Schwartz RA (2006).** Penile cancer. *Journal of the American Academy of Dermatology* **54** 369–391.
- Noel JC, Vandenbossche M, Peny MO, Sassine A, de Dobbeleer G and Schulman CC et al., (1992).** Verrucous carcinoma of the penis: importance of human papillomavirus typing for diagnosis and therapeutic decision. *European Urology* **22** 83–85.
- Pilotti S, Donghi R, D'Amato L, Giarola M, Longoni A and Della Torre G et al., (1993).** HPV detection and p53 alteration in squamous cell verrucous malignancies of the lower genital tract. *Diagnostic Molecular Pathology* **2** 248–256.
- Rinker MH, Fenske NA, Scalf LA and Glass LF (2001).** Histologic variants of squamous cell carcinoma of the skin. *Cancer Control* **8** 354–363.
- Schwartz RA (1995).** Verrucous carcinoma of the skin and mucosa. *Journal of the American Academy of Dermatology* **32** 1–21.
- Sheen MC, Sheu HM, Huang CH, Wang YW, Chai CY and Wu CF (2003).** Penile verrucous carcinoma successfully treated by intraaortic infusion with methotrexate. *Urology* **61** 1216–1220.
- Stankiewicz E, Kudahetti SC, Prowse DM, Ktori E, Cuzick J and Ambroisine L et al., (2009).** HPV infection and immunochemical detection of cell-cycle markers in verrucous carcinoma of the penis. *Modern Pathology* **22** 1160–1168.
- Wein AJ, Kavoussi LR, Novick AC, Partin AW and Peters CA (2007).** *Campbell-Walsh Urology*, 9th edition (Philadelphia: Saunders Elsevier).