

## Case Report

# VANISHING BONE DISEASE, A RARE CASE REPORT AND REVIEW OF LITERATURE

Dipti Rani Samanta<sup>1</sup>, Tapan Kumar Sahoo<sup>2</sup>, \*Saroj Kumar Das<sup>2</sup>, Preetam C.<sup>3</sup> and Surendra Nath Senapati<sup>4</sup>

<sup>1</sup>Department of Medical Oncology, Acharya Harihara Regional Cancer Centre, Cuttack, Odisha

<sup>2</sup>Department of Radiation Oncology, All India Institute of Medical Sciences, Bhubaneswar, Odisha

<sup>3</sup>Department of Otorhinolaryngology and Head & Neck surgery, All India Institute of Medical Sciences, Bhubaneswar, Odisha

<sup>4</sup>Department of Radiation Oncology, Acharya Harihara Regional Cancer Centre, Cuttack, Odisha

\*Author for Correspondence

## ABSTRACT

Vanishing bone disease (Gorham-Stout syndrome) is an extremely rare entity, with spontaneous and progressive resorption and disappearance of osseous structures which is replaced by vascular connective tissue. Etiology is unknown and few cases of idiopathic osteolysis have been reported. Children and adolescents are most commonly affected. Its clinical presentation is variable and depends upon the site of skeletal involvement. The disease has highly variable prognosis. It can cause minimum disability and death due to possibility of critical structure involvement. We reported a case of vanishing bone disease in a 28 year-old female.

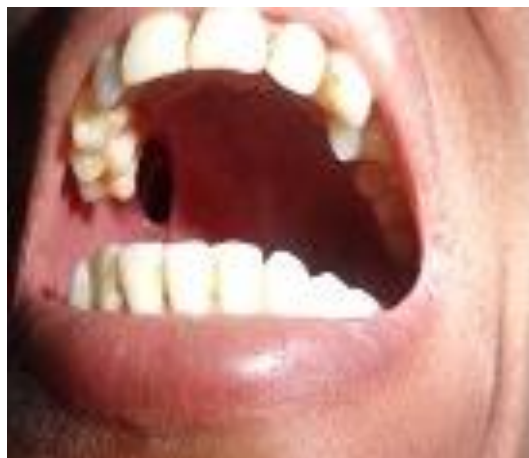**Keywords:** Gorham-Stout Syndrome, Osteolysis, Vanishing Bone Disease

## INTRODUCTION

Vanishing bone disease (VBD) is a rare idiopathic entity with extensive loss of bony matrix, which is replaced by proliferating thin-walled vascular channels and fibrous tissue (Vinee *et al.*, 1994). Most of the cases occurred in children or adults within 40 years of age group (Motamedi *et al.*, 2003). But, the diseases were previously described in as young as one month to as old as 75 years (Motamedi *et al.*, 2003). We report a case of VBD in a 26-year female.

## CASES

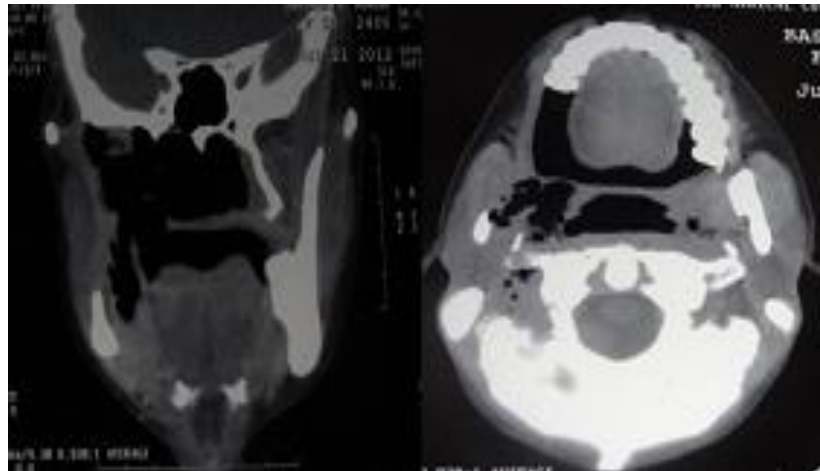
A 26-Year old female initially presented with chief complains of difficulty in chewing food, hole in upper hard palate, and loss of hearing in right ear for last 6 months. Patient had past history of right upper molar tooth extraction 6months back.



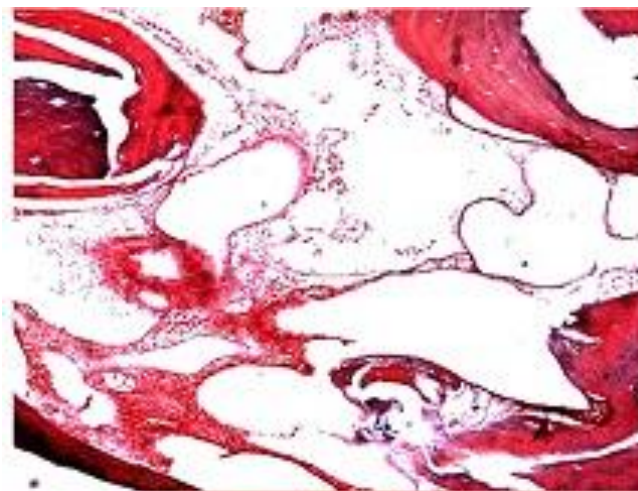
**Figure 1:** The figure shows absence of upper molar teeth on right side and a oro-antral fistulous tract present on right side of oral cavity near retromolar trigone area

### Case Report

Physical examination of oral cavity showed trismus and a fistula in right upper hard palate and retromolar trigone area with absence of upper molar and premolar and lower molar tooth (figure-1). Examination of other system did not reveal any abnormality. Contrast enhanced CT scan evaluation of face and neck revealed erosion of right occipital condyle, occipital bone and petrous apex with rarefaction or erosion of anterior arch of atlas seen on right side and oro-antral communication with air density in right masticator and para pharyngeal space (figure-2). Biopsy was taken from oro-antral fistulous tract revealed features of VBD (figure-3). The patient was received radiation therapy of 40Gy to right side face.



**Figure 2: Coronal and Sagittal CT scan image showing complete absence of maxilla and part of body and Ramus of mandible with adjacent molar and premolar tooth**



**Figure 3: H & E, 100X- Microsection shows thickened lamellar bone without marrow cavities next to fibrous tissue, with few fibroblasts and a proliferation of vascular channels**

### DISCUSSION

VBD is characterized by spontaneous or post-traumatic progressive resorption of bone. The disease was first described in 1838 (Huvos, 1991). Different names for this disease are phantom bone, massive osteolysis, and disappearing or VBD, acute spontaneous absorption of bone, hemangiomas, and lymphangiomatosis.

The bones of the upper extremity and the maxillofacial region are the common locations for the disease. The disease has male predominance and 60% cases are seen in men (Huvos, 1991). Disease can be

## Case Report

monostatic or polyostatic, but multicentricity is unusual (Velez *et al.*, 1993). The disease may often extend to adjacent bones and soft tissues. Endocrine and metabolic abnormalities are not associated with the disease (Johnson and McClure, 1958). There is no clear evidence regarding malignant, neuropathic and infectious factors in the causation of this disease. The mechanisms of bone destruction and resorption are unknown (Joseph and Barta, 1987). In general etiology is unknown. Incidence may be related to history of trauma, but half of the patients are without history of trauma (Velez *et al.*, 1993). VBD has highly variable prognosis ranging from minimum disability to death, due to involvement of critical structures (Jackson, 2000). The disease course is insidious due to painless nature of osteolytic process allowing normal activity while bone destruction occurs, which may cause pathological fractures (Jackson, 2000). The diagnosis of the disease is based on clinical examination, radiologic finding, and histopathologic examination. Dull aching, weakness in the affected site, swelling, and skeletal deformities are common symptoms (Moller *et al.*, 1999). Laboratory findings are not related in the diagnostic procedure. Alkaline phosphatase level may be elevated if bony fracture may occur. Over expression of interleukin-6 may be a potential mediator of increased osteoclast activity (Devlin *et al.*, 1996).

In suspected cases of VBD, a variety of imaging techniques are used like plain radiographs, radioisotope scans, computed tomography, scintigraphy and MRI (Malik *et al.*, 2008). Computed tomography finds the involvement and extent of bony and soft tissue component and facilitate biopsy of the affected bone (Assoun *et al.*, 1994). Conventional angiography, scintigraphy, and MRI are not reliable imaging procedures in VBD. Radiographs act as the best tools for detecting the disease (Naden, 1995). The radiographic findings act as diagnostic of VBD in case of unilateral partial or total disappearance of contiguous bones, tapering of bony remnants, and absence of a sclerosing or osteoblastic reaction are present. Complications depend on the affected bone. Histopathological findings of VBD depend on the phase of the disease at the time of diagnosed.

Two phases of the histopathological findings have been described in the literature (Heffez *et al.*, 1983). The first phase is increased vascular concentration in the bone-displacing fibrous tissue part and in the second phase only fibrous tissue is found. The presence and number of osteoclasts vary in VBD. However, there is no consensus data regarding definitive treatment. Surgical intervention may be a method of choice (Giraudet-Le *et al.*, 1995).

Surgery involves local resection of the affected bone, with or without replacement prostheses or bone grafts (Giraudet-Le *et al.*, 1995). Bone grafting have poor results, and with a high incidence of bone graft resorption. Radiation therapy has equivocal results, although in a few cases, apparent arrest has been occurred (Handl-Zeller and Hohenberg, 1990).

Radiation therapy in early course of the disease appears to be the only accepted form of treatment with a increased chance of success. Radiotherapy causes accelerating sclerosis of the proliferating blood vessels and prevents regrowth. The total dose of 30 to 45 Gy has been reported to be effective (Handl-Zeller and Hohenberg, 1990). Chemotherapy also has been reported to be successful in some patients. Treatment of VBD should include surgery, radiotherapy, and various medications, either alone or combined. The prognosis varies from slight disability to death. Severe disability results due to involvement of the pelvis, thorax, and cervical spine. However, the disease usually remains localized and undergoes eventual spontaneous arrest.

## Conclusion

VBD is a rare vascular proliferating disease. There is no standard treatment guideline for the disease due to its rarity. Proper evaluation should be necessary in case of multiple hypoplasia of bones to rule out such situation. Critical structures should be properly evaluated radiologically to rule out the involvement in case of VBD. Large number of case studies is necessary to draw a standard treatment guideline for the disease.

## REFERENCES

Assoun J, Richardi G and Railhac JJ *et al.*, (1994). CT and MRI of massive osteolysis of Gorham. *Journal of Computer Assisted Tomography* **18** 81-984.

### Case Report

**Devlin RD, Bone HG and Roodman GD (1996).** Interleukin-6: a potential mediator of the massive osteolysis in patient with Gorham-Stout disease. *Journal of Clinical Endocrinology and Metabolism* **81** 1893-1897.

**Giraudet-Le Quintrec JS, Peyrache MD, Courpied JP, Menkes CJ and Kerboull M (1995).** Idiopathic massive osteolysis of the femur: syndrome called Gorham-Stout syndrome [in French]. *La Presse Médicale* **24** 719-721.

**Handl-Zeller L and Hohenberg G (1990).** Radiotherapy of Morbus Gorham-Stout: the biological value of low irradiation dose. *British Journal of Radiology* **63** 206-208.

**Heffez L, Doku HC, Carter BL and Feeney JE (1983).** Perspectives of massive osteolysis: report of a case and review of the literature. *Oral Surgery, Oral Medicine, Oral Pathology and Oral Radiology* **55** 331-343.

**Huvos AG (1991).** *Bone Tumors, Diagnosis, Treatment and Prognosis*, 2nd edition (Philadelphia, PA: WB Saunders).

**Jackson JBS (2000).** A boneless arm. *Boston Medical and Surgical Journal* **18** 368-369.

**Johnson PM and McClure JG (1958).** Observations on massive osteolysis: a review of the literature and report of a case. *Radiology* **71** 28-42.

**Joseph J and Bartal E (1987).** Disappearing bone disease: a case report and review of the literature. *Journal of Pediatric Orthopaedics* **7** 584-588.

**Malik R, Malik R, Tandon S and Tandon P (2008).** Skeletal angiomatosis –rare cause of bone destruction: A case report with review of literature. *Indian Journal of Pathology and Microbiology* **1** 515-518.

**Moller G, Priemel M, Amling M, Werner M, Kuhlmeier AS and Delling G (1999).** The Gorham-Stout syndrome (Gorham's massive osteolysis): a report of six cases with histopathological findings. *Journal of Bone and Joint Surgery British Volume* **81** 501-506.

**Motamedi MH, Homauni SM and Behnia H (2003).** Massive osteolysis of the mandible: a case report. *Journal of Oral and Maxillofacial Surgery* **61** 957-963.

**Naden BA (1995).** When bone disappears. *RN* **58** 26-29.

**Velez A, Herrera M, Del Rio E and Ruiz-Maldonado R (1993).** Gorham's syndrome. *International Journal of Dermatology* **32** 884-887.

**Vinee P, Tanyu MO, Hauenstein KH, Sigmund G, Stover B and Adler CP (1994).** CT and MRI of Gorham syndrome. *Journal of Computer Assisted Tomography* **18** 985-989.