

Case Report

DOUBLE AORTIC ARCH SURGERY

*Suraj Wasudeo Nagre¹ and Dwarkanath V. Kulkarni²

¹Department of C.V.T.S., Grant Medical College, Mumbai

²Department of C.V.T.S., G.S. Medical College, Mumbai

*Author for Correspondence

ABSTRACT

Four year male child admitted with history of difficulty in swallowing, failure to thrive and recurrent respiratory tract infection. On investigating cardiac ct s/o double aortic arch and virtual bronchoscopy s/o tracheomalacia. After ligating the nondominant part of double aortic arch, the child get relieved symptomatically.

Keywords: Double Aortic Arch, Patent Ductous Arterious, Tracheomalacia

INTRODUCTION

Double Aortic Arch (DAA) is a relatively rare congenital cardiovascular malformation but the most common of the complete vascular rings, causing tracheo-esophageal compression.

This is a case report of a double aortic arch with balanced aortic arches, presenting with extrinsic tracheobronchial obstruction.

DAA is an anomaly of the aortic arch in which two aortic arches form a complete vascular ring that can compress the trachea and/or oesophagus.

The symptoms are related to the compression of the trachea, oesophagus or both by the complete vascular ring.

Treatment is surgical and is indicated in all symptomatic patients.

In the current era the risk of mortality or significant morbidity after surgical division of the lesser arch is low.

However, the preoperative degree of tracheomalacia has an important impact on postoperative recovery. In certain patients it may take several months (up to 1–2 years) for the obstructive respiratory symptoms (wheezing) to disappear.

CASES

4 year 6 kg male child admitted with chief complaints of noisy breathing, persistant dry cough, difficulty in swallowing with regurgitation, failure to thrive and recurrent respiratory tract infection requiring admission twice. Patient relatives consent has been taken for case report.

Investigations

Chest xray showed no perceptible indentation of the tracheal shadow. Echocardiographic evaluation showed normal cardiac anatomy and a right aortic arch.

Aberrant course of the left subclavian artery was suspected. Cardiac CT [figure 1] s/o double aortic arch compressing trachea and oesophagus.

Right aortic arch is dominant 11mm size giving origin to right common carotid and rt subclavin artery. Left aortic arch is nondominant 6 mm size giving origin to left CCA & left subclavian artery [figure 1]. Virtual bronchoscopy [figure 2] s/o lower one third of tracheal compression with only 5mm tracheal lumen and possibility of tracheomalacia [figure 2].

Case Report

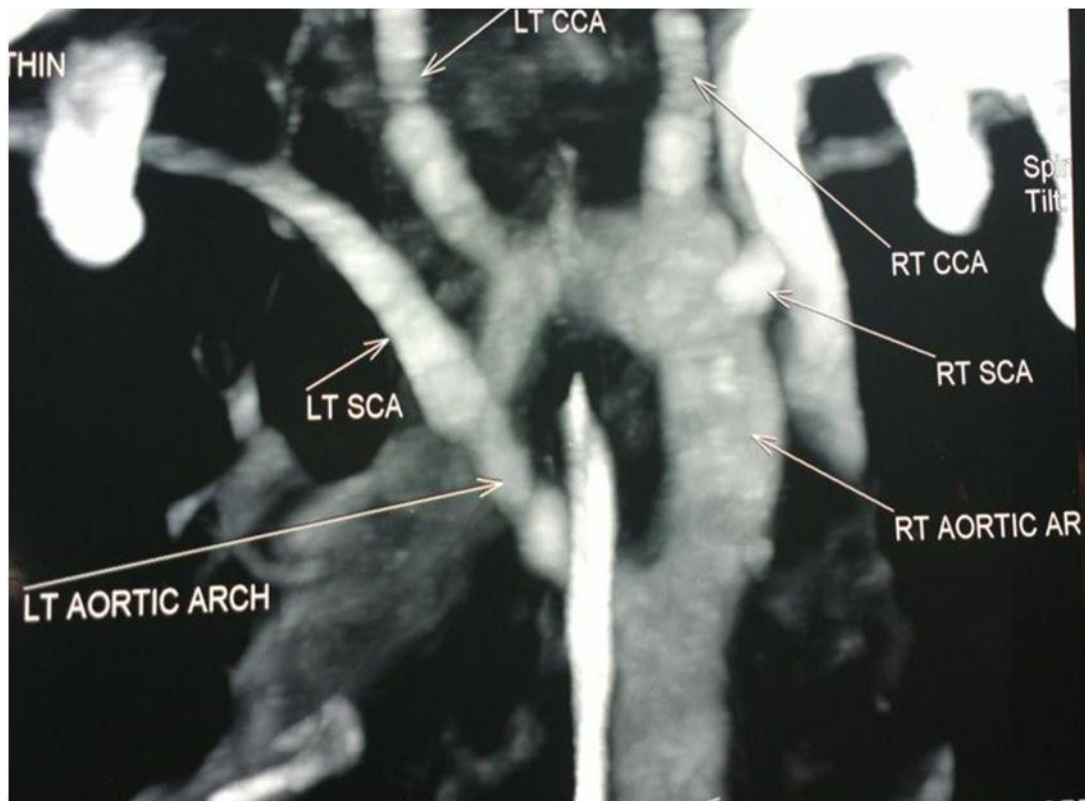


Figure 1: Cardiac CT showing double aortic arch

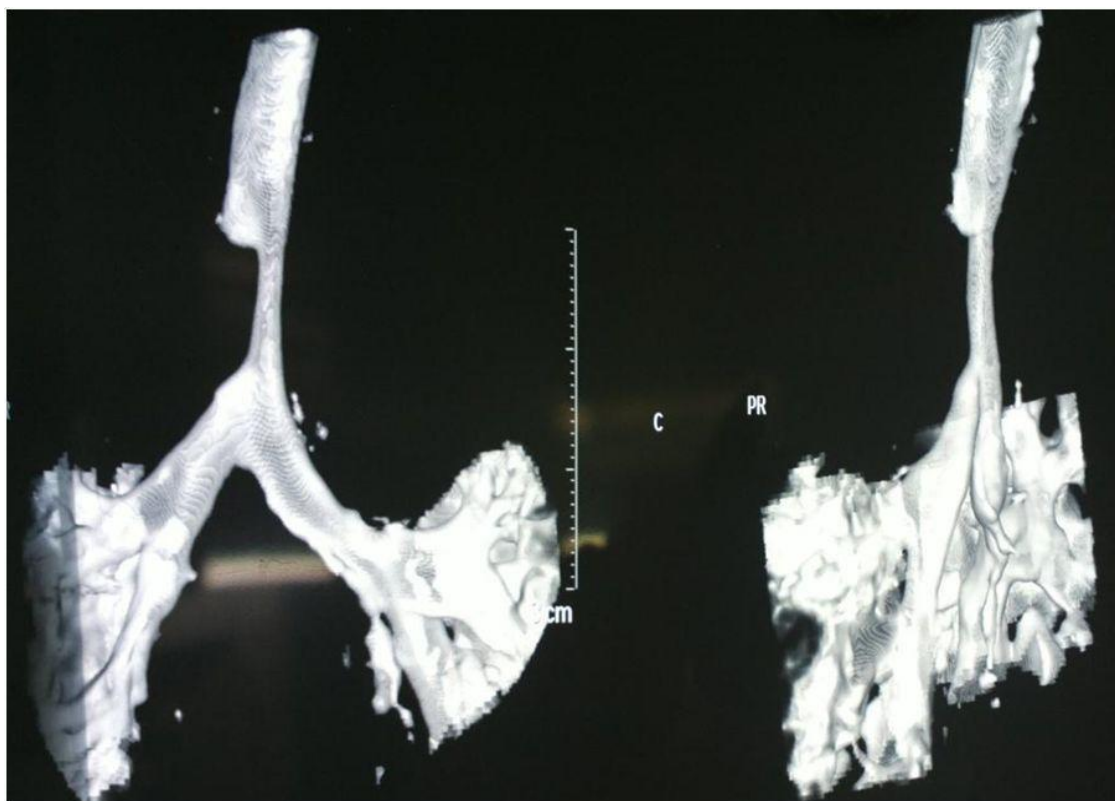

Figure 2: Virtual bronchoscopy showing tracheomalacia

Case Report

Operative Procedure

The patient underwent division of the left aortic arch through a left posterolateral thoracotomy (3rd intercostal space) approach. The right aortic arch was posterior, giving rise to the right common carotid and subclavian arteries. The left aortic arch was anterior, giving rise to the left common carotid and left subclavian arteries [figure 3]. The patent ductus arteriosus an accidental finding was divided [figure 4].

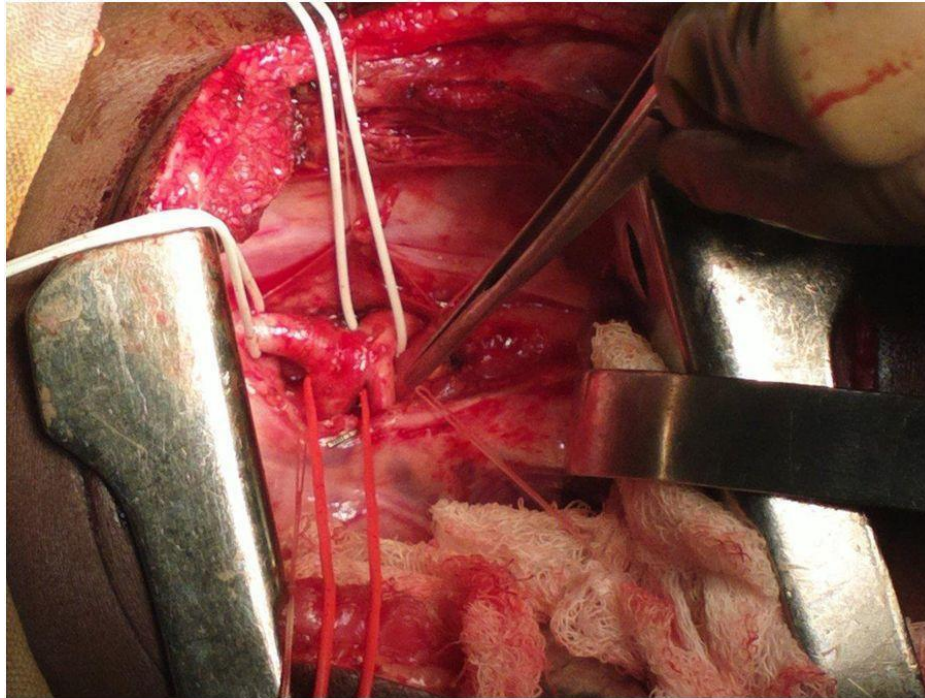


Figure 3: Nondominant left aortic arch, dominant right aortic arch, accidental finding-PDA

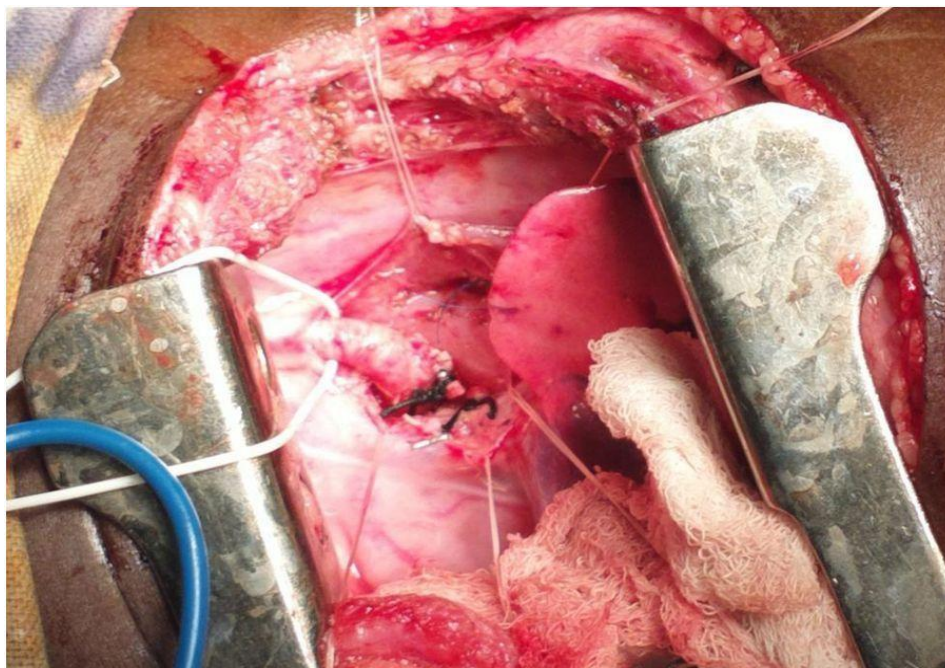


Figure 4: Accidental finding - PDA Ligated and PDA and nondominant left aortic arch both ligated and divided

Case Report

The anterior left aortic arch was clamped just proximal to its junction with the descending aorta. There was no decrease in femoral arterial blood pressure, no gradient between the left radial and the femoral arterial blood pressures, and both radial and carotid pulses were palpable. The anterior left aortic arch was divided at its junction with the descending aorta and the cut edges were oversewn. The mediastinal tissue around the aortic arches was dissected, allowing the right aortic arch to retract behind the esophagus. Strands of tissue around the trachea and esophagus were divided to relieve any potential residual compression or fibrosis.

The child was extubated on the first postoperative day. The child was stable and comfortable without any clinical evidence of respiratory obstruction or tracheobronchomalacia. He was transferred to the ward on the second postoperative day. The remaining postoperative recovery was uneventful, with no respiratory or feeding problems.

Post Procedure CT Aortogram

Diameter of rt. Aortic arch – 10.5

Diameter of trachea -4.4x7.1 mm

The patient continues to be free of respiratory compromise and feeding problems at follow-up of one year, and ECHO evaluation revealing a peak gradient of 8 mm Hg at the junction of the left aortic arch with the descending aorta.

DISCUSSION

Complete vascular rings are aortic arch anomalies in which the trachea and esophagus are compressed by the aortic arches and their derivatives. Double aortic arch, first reported in 1737 by Hommel, is due to the presence of right and left aortic arches encircling and compressing the trachea and the esophagus. Robert Gross performed the first successful surgical division of a vascular ring in 1945 at Boston Children's Hospital through a left antero-lateral chest approach (Wolman, 1939). He further elucidated the surgical principles involved in the division of vascular rings (Gross, 1945).

Embryologically, the ventral and dorsal aortas are connected by aortic arches which persist or involute to give rise to the normal aortic arch, its branches and minor arteries of the head. The right fourth aortic arch normally involutes at about 36 to 38 days in the 16-mm embryo and the left fourth aortic arch persists to give rise to the normal left aortic arch (Gross, 1955).

A schematic depiction with double aortic arches and double ductus arteriosi was described by Edwards to explain the various aortic arch anomalies due to the abnormal persistence or regression of various segments in this hypothetical double aortic arch model (Congdon, 1922). The persistence of both the right and left fourth aortic arches leads to a double aortic arch.

Anatomically, the ascending aorta arises normally and, as it exits the pericardium, it divides into two – right and left aortic arches which encircle the trachea and the esophagus and reunite posteriorly to form the descending aorta. Hypoplasia of one of the aortic arches is common with one arch, more commonly the right aortic arch, being dominant.

Atresia can be uncommonly present in any of the segments of either of the aortic arches, resulting in various subtypes of double aortic arch with atresia (Edwards, 1948). The posterior descending aorta formed by the union of the two aortic arches can be on the left or on the right of the thoracic vertebrae. A right dominant double aortic arch has been more commonly observed with left descending aorta and vice versa.

The descending aorta has a tendency to be more midline than normal. This abnormal position can cause compression of the airway between the pulmonary artery and the descending aorta postoperatively, leading to persistence of symptoms following surgery (Backer and Mavroudis, 2000). The ductus or ligamentum arteriosum, which is not a part of the vascular ring, runs between the left pulmonary artery, inferior to the junction between the left aortic arch and the descending aorta (Fleck *et al.*, 2002). The aortic arches give rise to the ipsilateral common carotid and subclavian arteries and the innominate artery is absent.

A contemporary review of the literature regarding double aortic arches is presented in Table 1.

Case Report

Table 1

	Backer <i>et al., (8)</i>	AlsenaidiChunn <i>et al., (9)</i>	Shanmugam <i>et al., (10)</i>	<i>et al., (11)</i>
No. Of Patients	113	81	11	29
Age	1.4 □ 2.4y	6 m	7m*	-
Sex (M:F)	1.3:1	67: 33	19:20	17:12
Presenting complaint				
Respiratory	Most common	91%	95%*	Most common
GI	15%	40%	35%*	8 (27.5%)
Associated cardiac defect	7%	17%		7(24%)
Surgical approach - Left Thoracotomy	108 (95.5)	72 (92%)	34 (87%)*	25(86.2%)
Dominant arch				
Right	75%	71%	64%	86.2%
Left	18%	20%		6.9%
Balanced	7%	9%		6.9%
Operative mortality	None	2	2*	None
Postoperative complications			33%*	
Respiratory	Most common: Tracheomalacia Bronchomalacia			
Chylothorax		9%	4*	3(7.6%)
Follow up period		1.8y	12.5m*	7.1y
Residual respiratory symptoms		54%	47%	24.1%

*39 congenital aortic arch anomalies including 11 with double aortic arches

Patients with double aortic arch can be asymptomatic or present with symptoms ranging from nonspecific complaints to life threatening respiratory distress. The symptoms of stridorous breathing, dysphagia, a “barky” chronic cough, susceptibility to bronchopneumonia, head retraction, malnutrition, onset during early infancy, and an increase of respiratory distress during feeding were described by Wolman (1939). An esophageal foreign body at the site of compression by the vascular ring is rarely the presenting feature of double aortic arch. Life threatening episodes of respiratory arrest and apnea have also been described (Alsenaidi *et al.*, 2006).

Conventional chest x-ray may show indentation of tracheal shadow, retro tracheal opacity, and anterior tracheal bowing. Specific radiological signs have been described for barium esophagography (Lowe *et al.*, 1991). These include bilateral persistent extrinsic compressions of esophagus in AP view, with the dominant arch causing a deeper and superior indentation and a deep posterior indentation in lateral and oblique views. Barium swallow is diagnostic in the majority of cases. However, MDCT and MRI have become increasingly utilized in the diagnosis and evaluation of aortic arch anomalies, including double aortic arch (Backer *et al.*, 2005). The assessment of the arch dominance and surrounding tissues in the mediastinum has improved with these radiological modalities, especially when the barium swallow is negative, there is innominate artery compression, or in complex cases. The four-vessel sign in the superior mediastinum can be seen due to the presence of separate subclavian and common carotid arteries on both sides. Presently angiography is rarely indicated or necessary for adequate evaluation of aortic arch anomalies. Echocardiography is recommended to rule out associated congenital cardiac defects (Backer *et al.*, 2005; Alsenaidi *et al.*, 2006; Shanmugam *et al.*, 2005; Woods *et al.*, 2001).

Repair is achieved through a left posterolateral thoracotomy approach, especially those with a dominant right aortic arch (Backer *et al.*, 2005; Alsenaidi *et al.*, 2006; Chun *et al.*, 1992; Shanmugam *et al.*, 2005). The Mayo Clinic recommends a right posterolateral thoracotomy approach in patients with left aortic arch, right-sided descending thoracic aorta, and right ductus or ligamentum arteriosum; a double arch with

Case Report

atresia of the right posterior segment; or when anastomosis of an aberrant right subclavian artery to the ascending aorta is performed (Son *et al.*, 1993). Backer and Mavroudis (1997) recommend that innominate artery compression be approached from the right side, with suspension of the innominate artery to the sternum. Repair through a median sternotomy is recommended when concomitant repair of intracardiac defects is performed (Woods *et al.*, 2001; Son *et al.*, 1993).

The principles of surgery are essentially the same as described by Gross (1955). The surgical repair includes adequate dissection of the aortic arches and descending aorta, division of the non-dominant aortic arch, division of the ductus or ligamentum arteriosum, and the dissection and division of the mediastinal adventitial bands that may compress the trachea or esophagus.

Post-operative complications include bleeding, vocal cord paralysis, pneumonia, pneumothorax, chylothorax, feeding difficulties, and residual respiratory obstruction. Residual respiratory complaints have been noted in up to 54% of patients (Alsenaidi *et al.*, 2006; Chun *et al.*, 1992; Shanmugam *et al.*, 2005). While the residual respiratory symptoms are usually due to tracheobronchomalacia, anatomic compression of the trachea by the postoperative arch and the anterior remnant of the divided arch, or by midline descending aorta, can be present (Fleck *et al.*, 2002). Due to the presence of the dual-sidedness of the balanced aortic arches, these patients have a more midline descending aorta. This results in abnormal stacking of the structures anterior to the spine and leads to extrinsic compression of the left main bronchus between the midline descending aorta posteriorly and the pulmonary artery anteriorly.

Conclusion

Double aortic arch surgery seems to be simple and safe even in unexperienced hand if operating surgeon has proper understanding of anatomy. Symptomatic recovery was fast and very good after surgery. Early diagnosis and surgery was key factor for better symptomatic recovery. Vascular rings, more commonly the double aortic arch, are an important cause of tracheo-esophageal compression, the clinical suspicion and diagnosis of which can lead to early surgical intervention and relief or avoidance of immediate or long term respiratory complications.

REFERENCES

- Alsenaidi K, Gurofsky R, Karamlou T, Williams WG and McCrindle BW (2006). Management and outcomes of double aortic arch in 81 patients. *Pediatrics* **118** e1336-41.
- Backer CL and Mavroudis C (1997). Surgical approach to vascular rings. In: *Advances in Cardiac Surgery-Volume 9*, edited by Karp RB, Laks H and Wechsler AS (St. Louis: Mosby- Year Book) 29-64.
- Backer CL and Mavroudis C (2000). Congenital Heart Surgery Nomenclature and Database Project. Vascular rings, tracheal stenosis, and pectus excavatum. *Annals of Thoracic Surgery* **69**(suppl) S308-18.
- Backer CL, Mavroudis C, Rigsby CK and Holinger LD (2005). Trends in vascular ring surgery. *Journal of Thoracic and Cardiovascular Surgery* **129** 1339-47.
- Chun K, Colombani PM, Dudgeon DL and Haller JA Jr (1992). Diagnosis and management of congenital vascular rings: a 22-year experience. *Annals of Thoracic Surgery* **53** 597-602.
- Congdon ED (1922). Transformation of the aortic arch system during the development of the human embryo. *Contributions to Embryology* **14** 47-110.
- Edwards JE (1948). Anomalies of derivatives of aortic arch system. *Medical Clinics of North America* **32** 925-49.
- Fleck RJ, Pacharn P, Fricke BL, Ziegler MA, Cotton RT and Donnelly LF (2002). Imaging findings in pediatric patients with persistent airway symptoms after surgery for double aortic arch. *AJR* **178** 1275-79.
- Gross RE (1945). Surgical relief for tracheal obstruction from a vascular ring. *New England Journal of Medicine* **233** 586-90.
- Gross RE (1955). Arterial malformations which cause compression of the trachea or esophagus. *Circulation* **11** 124-34.
- Lowe GM, Donaldson JS and Backer CL (1991). Vascular rings: 10-year review of imaging. *Radiology RadioGraphics* **11** 637-46.

Case Report

Noguchi K, Hori D, Nomura Y and Tanaka H (2012). Double aortic arch in an adult. *Interactive CardioVascular and Thoracic Surgery*.

Shanmugam G, Macarthur K and Pollock J (2005). Surgical repair of double aortic arch: 16-year experience. *Asian Cardiovascular and Thoracic Annals* **13** 4-10.

Umegaki T, Sumi C, Nishi K, Ikeda S and Shingu K (2010). Airway management in an infant with double aortic arch. *Journal of Anesthesia* **24**(1) 117-20.

Van Son JAM, Julsrud PR and Hagler DJ et al., (1993). Surgical treatment of vascular rings: the Mayo Clinic experience. *Mayo Clinic Proceedings* **68** 1056-63.

Wolman IJ (1939). Syndrome of constricting double aortic arch in infancy: report of a case. *Journal of Pediatrics* **14** 527-33.

Woods RK, Sharp RJ and Holcomb GW et al., (2001). Vascular anomalies and tracheoesophageal compression: a single institution's 25-year experience. *Annals of Thoracic Surgery* **72** 434-39.