

Case Report

IMPACTED RING PESSARY IN PELVIC ORGAN PROLAPSE

***Dhadke V., Bansode S. and Vaidya S.**

Department of Obstetrics and Gynaecology, SRTR Govt. Medical College, Ambajogai

**Author for Correspondence*

ABSTRACT

Ring pessary may be used as stop gap arrangement in treatment of prolapse. Forgotten pessaries produce many complications even to the extent of rectovaginal fistula. But these complications are common in long standing (> 10years) pessaries and they are common above the age of 60 years. We present a 30 year old patient with pessary since 3 years. Patient presented with pain in pelvic region since 6 months with difficulty during defecation. Patient's HIV status was positive and she was a diagnosed case of pulmonary tuberculosis on ART and AKT since 1 year. This is probably the youngest case of pessary complication with minimal duration of pessary use.

Keywords: *Impacted Pessary, Ring Pessary Complications*

INTRODUCTION

Human immunodeficiency virus infection and acquired immune deficiency syndrome (HIV/AIDS) is a spectrum of conditions caused by infection with the single stranded rna virus. Following initial infection, a person may experience a brief period of influenza-like illness. This is typically followed by a prolonged period without symptoms. As the infection progresses, it interferes more and more with the immune system, making the person much more susceptible to common infections like tuberculosis, as well as opportunistic infections and tumors that do not usually affect people who have working immune systems. The late symptoms of the infection are referred to as AIDS. This stage is often complicated by an infection of the lung known as pneumocystis pneumonia, severe weight loss, a type of cancer known as Kaposi's sarcoma, or other AIDS-defining conditions.

CASES

A 30 year old female came with complain of pain in pelvic region. Patient had history of ring pessary introduced 3 years back for conservative management of prolapse. Past history revealed her positive HIV status and pulmonary tuberculosis. She was receiving ART & AKT since 1 year. Her obstetric history revealed one FTND female child of 4 years with positive HIV status.

Per/Speculum: Examination revealed a ring pessary in vagina which could not be pulled out. During manipulation of the pessary, patient had sharp pain. Vaginal mucosa with tissue seemed to be grown over the pessary, impacted at 4 o'clock & 8 o'clock position.

Decision of removal of ring pessary was taken. Under IV sedation and local anaesthesia, a small incision was given with scalpel at 4 o'clock & 8 o'clock position. Pessary pulled through the stretched mucosa from impacted position. The defect sutured in single layer.

DISCUSSION

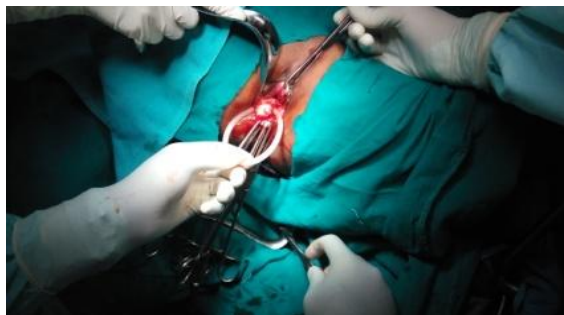

Figure 1: Examination under anaesthesia

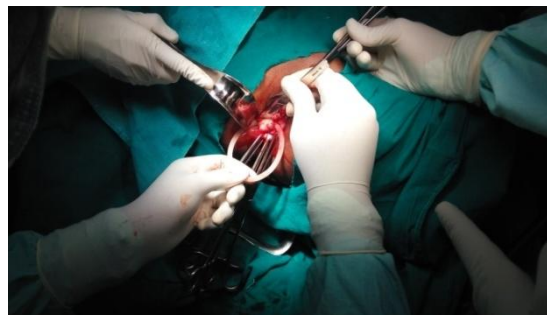


Figure 2: Incision and removal

Case Report

Complications of ring pessaries are common in geriatric patients. Impacted pessary is commonly found in forgotten pessary cases. In our case both findings were absent; instead our patient was a young female with knowledge of pessary in situ.

The peculiarity in this case is her HIV positive status and she was suffering from pulmonary tuberculosis. The pessary was impacted at 4'o clock and 8'o clock position and was causing pain in the pelvic region and discomfort during defecation, so for relief of her symptoms removal was necessary. There was a band like over growth from the posterior vaginal wall which has to be cut and resutured.

REFERENCES

- Biswas A and Das HS (2002).** An unusual foreign body in the vagina producing vesicovaginal fistula. *Indian Medical Association* **100**(4) 257-59.
- Hanavadi S, Durham- Hall A, Oke T and Aston N (2004).** Forgotten vaginal pessary eroding into rectum. *Annals of The Royal College of Surgeons of England* **86**(6) 18-19.
- Ott R, Richter H, Behr J and Scheele J (1993).** Small bowel prolapse and incarceration caused by vaginal ring. *British Journal of Surgery* **80** 1157.
- Roberge J, Kellaer C and Garfinkel M (2001).** Vaginal pessary-induced mechanical bowel obstruction. *Journal of Emergency Medicine* **20** 367-70.
- Sangita P, Chaudhari V, Singh RK, Kumari Nutan and Sumit Kumar (2013).** Forgotten vaginal pessary case report. *Journal of Medical Sciences* **38** 7312-15.
- Zeitlin MP and Lebher TB (1992).** Pessaries in geriatric patient. *Journal of the American Geriatrics Society* **40** 635-39.