

Case Report

RECURRENT HEMORRHAGIC BULLOUS DIABETICORUM – A RARE CASE REPORT

***Vijaya Kumar S., Sandeep Z.U., Prasad P.V.S. and Kaviarasan P.K.**

*Department of Dermatology, Venereology & Leprosy, Rajah Muthiah Medical College,
Chidambaram, Tamilnadu, India*

**Author for Correspondence*

ABSTRACT

The abrupt onset of haemorrhagic blister involving lower extremities without specific underlying etiology is a rare skin manifestation of diabetes. The real importance of this disorder is that of correct diagnosis, because several of the blistering disorders have a high rate of morbidity & requires potentially toxic systemic medications. We report a rare case of recurrent hemorrhagic bullous eruption over lower limbs in a patient newly diagnosed with type 2 diabetes mellitus. Bullous diabeticorum in our case was not associated with microangiopathic complications such as retinopathy, neuropathy & nephropathy and the lesions responded to good glyceemic control.

Keywords: Bullous Diabeticorum, Diabetes, Hemorrhagic Bullae

INTRODUCTION

Bullous diabeticorum (BD) is a noninflammatory blistering disease occurring spontaneously in diabetic patients (Wilson *et al.*, 2012). In 1930, Kramer first reported bullous-like lesions in diabetic patients. It is also termed as bullous disease of diabetes and diabetic bullae (Kramer, 1932; Lipsky *et al.*, 2000). Larsen *et al.*, (2008) reported a yearly incidence of 0.16%. Bullous disease of diabetes tends to arise in long-standing diabetes in conjunction with multiple complications (Huntley and Davis, 1982) and recurrences are common (Huntley and Davis, 1982).

The cause of bullae formation was yet to be established (Wilson *et al.*, 2012). Only few studies related bulla formation with high glucose levels (Wilson *et al.*, 2012).

CASES

A 48 year old man presented with multiple, recurrent, painless, hemorrhagic blisters over the shin of both legs. Lesions appeared suddenly without preceding history of insect bite, trauma, drug intake, oral ulcers, photosensitivity, burns or history suggestive of autoimmune blistering diseases. He gave history of similar lesions twice over the same site over the past 4 months and he habitually ruptured the lesions.

On examination, patient showed multiple, discrete, tense hemorrhagic bullae of size ranging from 0.5 to 2.5 cm in diameter over the shin of both legs with a ruptured bulla. One of the bullae was ruptured and it showed peripheral hemorrhagic crusting around it.

There was no sign of inflammation around the bullae. Older lesions resolved with atrophic scarring and pigmentation. Nikolsky sign was negative & there was no involvement of mucous membrane & skin over other areas. There was no regional lymphadenopathy.

Systemic examination did not show any abnormalities. Sensory and motor functions were normal. Nerve conduction study was normal. Direct ophthalmoscopic examination revealed no evidence of diabetic retinopathy.

Investigations done (renal function tests, liver function tests, electrolytes, lipid profile, antinuclear antibodies) were found to be normal. He was tested negative for HIV and HbsAg. Random blood sugar was 208 mg/dl & glycosylated haemoglobin (HbA1c) was 7.5. Urine routine showed 1 + glucose with no proteinuria. Gram stain from the vesicular fluid did not show any organisms.

Skin Biopsy specimen taken from the bulla showed an atrophic epidermis with a thinned out basement membrane zone. There was an intraepidermal blister with red blood cells and inflammatory infiltrate predominantly of neutrophils. No acantholytic cells were seen.

Case Report

The lesions resolved with insulin therapy alone in a span of 2 weeks, leaving behind areas of post inflammatory pigmentation. Patient was followed up for a period of 6 months. There was no recurrence during this period and the patient had good glycemic control (HbA1c value of 6.5).

DISCUSSION

Cutaneous signs of diabetes can be an early indicator of undiagnosed diabetes (Huntley and Davis, 1982). They can be either the manifestation of the disease per se or due to therapy (Huntley and Davis, 1982). Skin diseases having strong association with diabetes are bacterial and fungal infections, necrobiosis lipoidica diabetorum, diabetic dermopathy, sclerema of diabetes, waxy skin, diabetic bullae, yellow skin, eruptive xanthomas & disseminated granuloma annulare (Wilson *et al.*, 2012; Huntley and Davis, 1982).

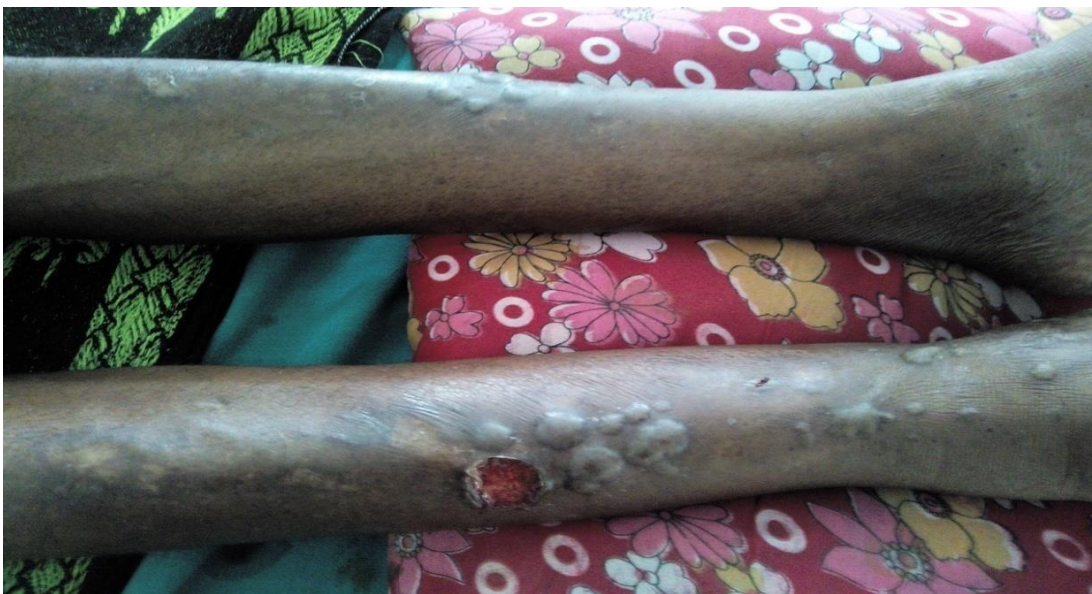Diabetic Bullae commonly affects men aged 40 to 75 years (Kramer, 1932; Lipsky *et al.*, 2000). This eruption has been observed most frequently in Diabetics with neuropathy, retinopathy, nephropathy and end stage renal failure (Bernstein *et al.*, 1979).

Diabetic Bullae vary in size ranging from 0.5 to 10 cm (Lipsky *et al.*, 2000; Toonstra, 1985). They are tense, non tender, arising from normal skin, containing clear fluid, commonly seen in acral region and rarely on the trunk (Wilson *et al.*, 2012; Huntley and Davis, 1982). Onset is overnight and they heal spontaneously in 2 to 6 weeks without scarring (Wilson *et al.*, 2012; Kramer, 1932; Lipsky *et al.*, 2000; Huntley and Davis, 1982). Recurrences are common (Lipsky *et al.*, 2000; Toonstra, 1985). Secondary infection may occur and recurrent lesions may leads to ulceration (Larsen *et al.*, 2008). There have also been reports of amputation due to infection (Lipsky *et al.*, 2000).

Various hypothesis have been proposed such as reduced threshold to suction blistering (Bernstein *et al.*, 1983), microangiopathy (Kramer, 1932), trauma (Bello *et al.*, 2012), ultraviolet light exposure (Bello *et al.*, 2012), alteration in carbohydrate imbalance, immunoglobulin mediated vasculitis and ischemic cationic imbalance due to nephropathy (Kramer, 1932; Toonstra, 1985; Bernstein *et al.*, 1979).

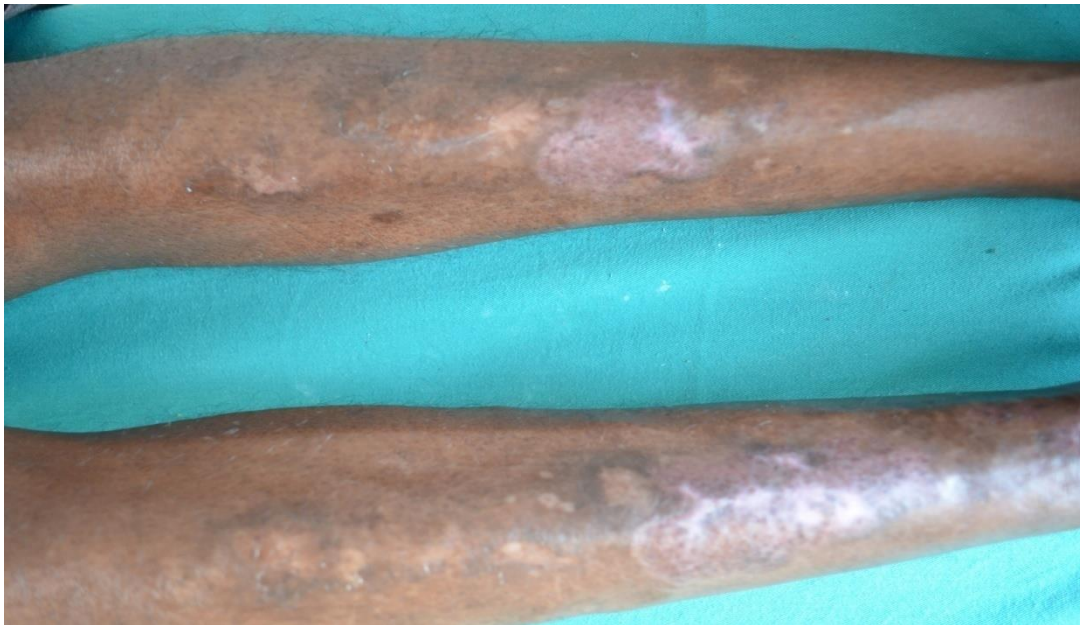Larsen *et al.*, suggested poor regulation of blood glucose as a cause of bullae formation (Larsen *et al.*, 2008). Wilson *et al.*, recorded blood glucose level on 50 occasions of bullae occurrence and 50 occasions when bullae were not present in his patient over a 11 year period. Poor blood glucose was evident at the time of new bulla formation.

Lesions at the Time of Presentation



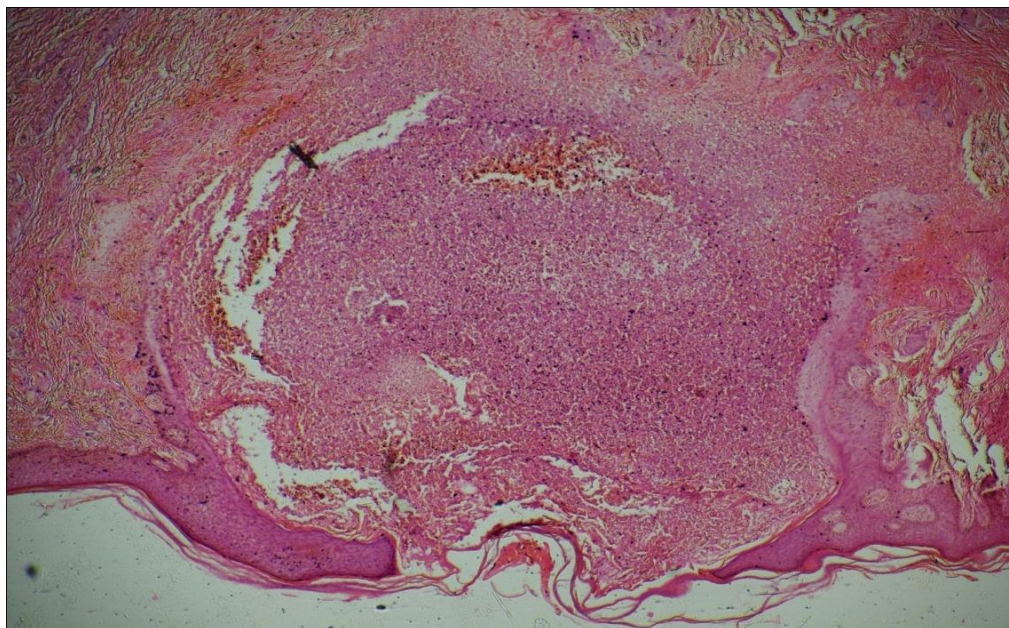
A) Multiple, discrete, tense hemorrhagic bullae of size ranging from 0.5 to 2.5 cm in diameter over the shin of both legs

Case Report



B) Lesions after 2 Weeks

Lesions healed leaving post inflammatory pigmentation.



Histopathology

C) Picture showing intraepidermal blister. Blister cavity contains red blood cells and neutrophils.

Bullous diabeticorum should be differentiated from other immunobullous and metabolic disorders like bullous pemphigoid, pemphigus vulgaris, epidermolysis bullosa acquisita, drug induced bullous disorders, dermatitis herpetiformis, porphyria cutanea tarda and pseudoporphyria (Wilson *et al.*, 2012; Kramer, 1932; Bello *et al.*, 2012).

Histologically, many of the reported cases described a intraepidermal separation without acantholysis (Huntley and Davis, 1982). The blister plane may appear in a subcorneal, intraepidermal, or subepidermal location (Bello *et al.*, 2012; Toonstra, 1985). Anchoring fibrils and hemidesmosomes are absent or

Case Report

decreased in early blisters (Bello *et al.*, 2012). Acantholytic cells have been reported in few cases (Bernstein *et al.*, 1983; Tilak *et al.*, 2014).

Specific treatment of bullous disease of diabetes is not necessary (Bello *et al.*, 2012; Tilak *et al.*, 2014). The blister should be left intact to serve as a sterile dressing and to avoid secondary bacterial infection (Bello *et al.*, 2012).

Conclusion

Hemorrhagic bullous lesions of bullous diabeticorum have not been well documented. In our case, lesions subsided spontaneously with glycemic control alone. No recurrence of bulla was noted over a follow up period of 6 months as the patient was under good glycemic control.

Majority of the characteristic cutaneous manifestations of diabetes have been under reported. Studies are needed in large scale with periodic follow up to correlate dermatological manifestations with other complications of diabetes and glycemic control.

REFERENCES

- Bello F, Samaila M, Labal Y and Nkoro UK (2012).** 2 Cases of bullosis diabeticorum following long-distance journeys by road: A report of 2 cases. *Case Reports in Endocrinology* 367218.
- Bernstein JE, Levine LE and Medenica MM (1983).** Reduced threshold to suction-induced blister formation in insulin-dependent diabetics. *JAAD* 8 790-1.
- Bernstein JE, Medenica M, Soltani K and Griem SF (1979).** Bullous eruption of diabetes mellitus. *Archives of Dermatology* 115 324-5.
- Huntley CA and Davis CA (1982).** The cutaneous manifestations of diabetes mellitus. *JAAD* 7 427-55.
- Kramer DW (1932).** Early or warning signs of impending gangrene in diabetes. *Journal of Medical Record* 132 338-42.
- Larsen K, Jensen T, Karlsmark T and Holstein PE (2008).** Incidence of bullosis diabeticorum - a controversial cause of chronic foot ulceration. *International Wound Journal* 5 591-6.
- Lipsky BA, Baker PD and Ahroni JH (2000).** Diabetic bullae 12 cases of a purportedly rare cutaneous disorder. *International Journal of Dermatology* 39 196-200.
- Tilak Raj R, Kumar P and Palsingh S (2014).** Bullosis diabeticorum involving an unusual site – A diagnostic dilemma; managed successfully with antidiabetic drugs: A case report. *Dermatology Online Journal* 5 294-6.
- Toonstra J (1985).** Bullosis diabeticorum, Report of a case with a review of the literature. *JAAD* 13 799–805.
- Wilson TC, Snyder RJ and Southerland CC (2012).** Bullosis Diabeticorum: Is there a correlation between hyperglycemia and this symptomatology? *Wounds* 24(12) 350-55.