

## TOTAL HIP ARTHROPLASTY FOR ANKYLOSED HIP

**Sahaya Jose R.**

*Department of Orthopaedics, Sree Mookambika Institute of Medical Sciences,  
Kanyakumari District, TN, India*

*\*Author for Correspondence*

### ABSTRACT

Biomechanics secondary to hip ankylosis is often altered resulting in degeneration of lumbar spine, ipsilateral knee and contralateral hip and knee. Symptoms in these joints may be reduced with total hip arthroplasty (THA) of the ankylosed hip. THA in the ankylosed hip is a technically challenging procedure and the overall clinical outcome is generally less satisfactory than routine THA performed for osteoarthritis and other aetiologies. Functional integrity of the hip abductor muscles is the most important predictor of walking ability following THA. Risk Factors include bilateral sacro-ilitis, ankylosis of the vertebral column and high incidence of Leucocyte antigen B27. A stable mobile hip with good functional result was obtained at twelve months follow up (Harris Hip Score-84).

**Keywords:** Total Hip Arthroplasty (THA), Ankylosing Spondylitis (AS), Harris Hip Score (HHS)

### INTRODUCTION

Hip ankylosis is a rare entity. In the past an arthrodesis was performed for symptomatic patients but numerous studies have however proven that the outcome of THA in ankylosis is favourable. Ankylosis of hip is very difficult to treat surgically, should only be attempted by an experienced surgeon together with comprehensive pre- operative planning. It is further more important to inform the patient the possible complications of this procedure like nerve palsy, infection, dislocation and heterotopic ossification.

### CASES

A fifty six year old male, an office attendant by occupation, presented to us with complaints of pain in both hips more on left hip than right since fifteen years, aggravated for past three months. He presented to us with a painful (HHS-36) hip affecting his activities of daily living (ADL). On examination, his left hip had scarpa's triangle tenderness; vascular sign of Narath was negative. He had fixed flexion deformity of twenty degree, he had range of motion abduction of 5 degrees, and adduction of 15 degrees and both internal and external rotation of left hip were 10 degrees. He had a painful left hip with jog of movements, where as his right hip was completely fused in 20 degrees of fixed flexion deformity and the movements were absolutely nil. Clinically his cervical spine and dorso- lumbar spine movements were also reduced. Clinically he had features of fibrous ankylosis of left hip and bony ankylosis of the right hip which was later confirmed radiologically. He also had HLA-B27 positive and his spine X- rays showed bamboo spine suggestive of classical case of AS of both hip and spine. His chest expansion was also reduced. He also had diabetes and hypertension which added the risk of surgery. He had left knee flexion of about 80 degrees with X-rays showing osteoarthritis changes. Spinal/Epidural anaesthesia was deferred by anesthetist due to bamboo spine. Fibre optic scope general anaesthesia was planned for THA after getting high risk consent and after controlling his diabetes and hypertension.

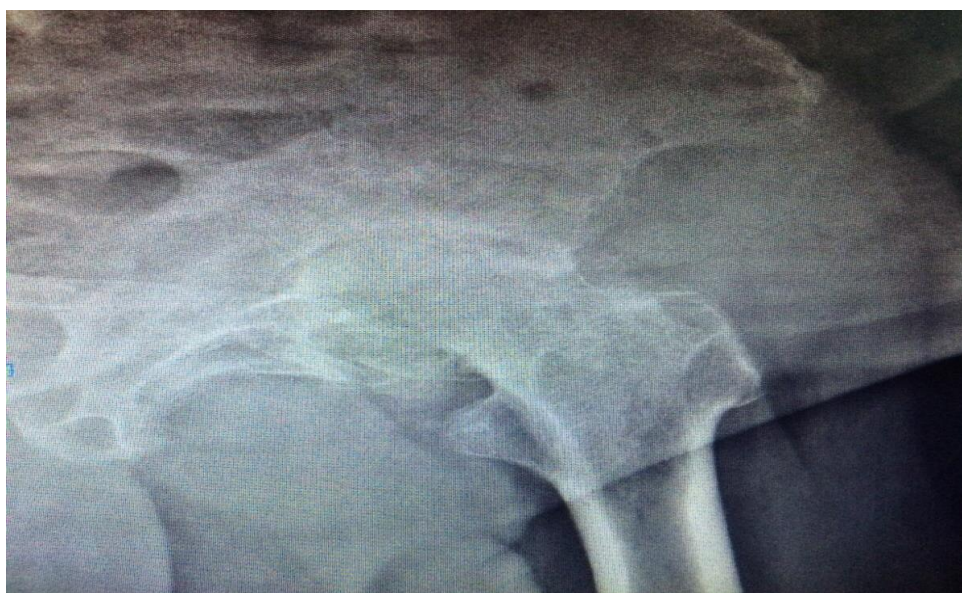Under general anaesthesia patient in right lateral position, using posterior approach gluteus maximus was cut, iliotibial band was split, using little rotatory movements available the short external rotators were cut at femoral attachment. Capsule incised in 'T' shaped fashion. Since dislocation of head was difficult, neck of femur osteotomised using an oscillating saw. Then we had difficulty in extracting the remaining head lying in the acetabulum, which was removed piece-meal after sequential reaming using acetabular reamers, constantly checked under C arm. Then acetabulum was exposed properly. After sequential reaming appropriate size acetabular component was fixed with one screw. Femoral segment was then prepared and adequate size femoral component was used after trial. Reduction of hip done. Intra-operative movements were found satisfactory. Wound closed in layers. Surgical time was two hours and forty five

### **Case Report**

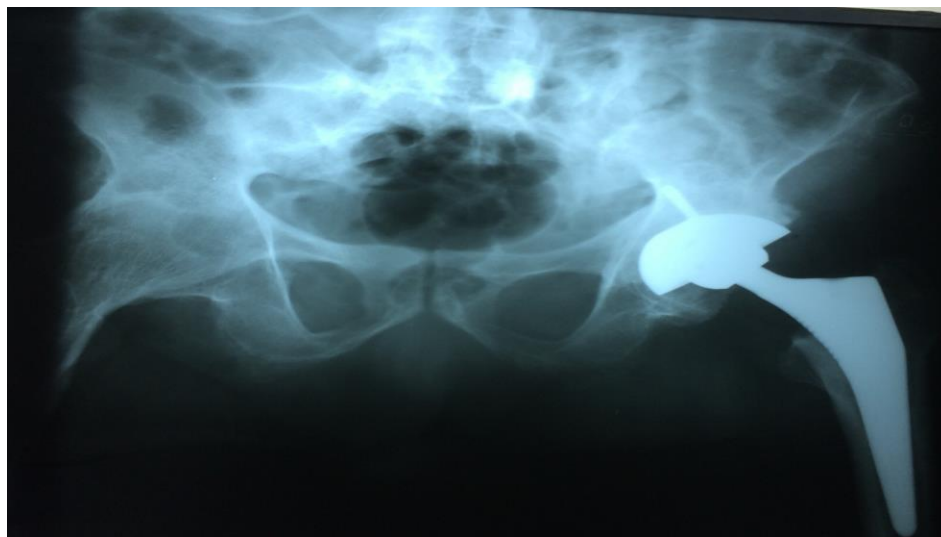
minutes. Drain removed on third post operative day. Thereafter patient mobilised full weight bearing with walker support. There were no issues with wound healing nor did we encounter any neurovascular complications. At twelve months follow up his HHS was 84. He had good range of motion of left hip and X-rays showed good implant position without radiolucencies or signs of loosening.

### **DISCUSSION**

In this study, patient's functional outcome was assessed by HHS. This score has three parts. First part is as follows: questions related to pain, distance travelled while walking, limping, wearing socks and shoes, climbing stairs, sitting and using public transportation. In the second part differences in limb length and joint movements are assessed. In the third part flexion, abduction, adduction and external rotation of the hip joint are examined. The final score is the sum of the score allocated for each part. In this study HHS survey after surgery compared with before surgery showed considerable progress in joint function, so that HHS of 36 was elevated to 84 after one year.

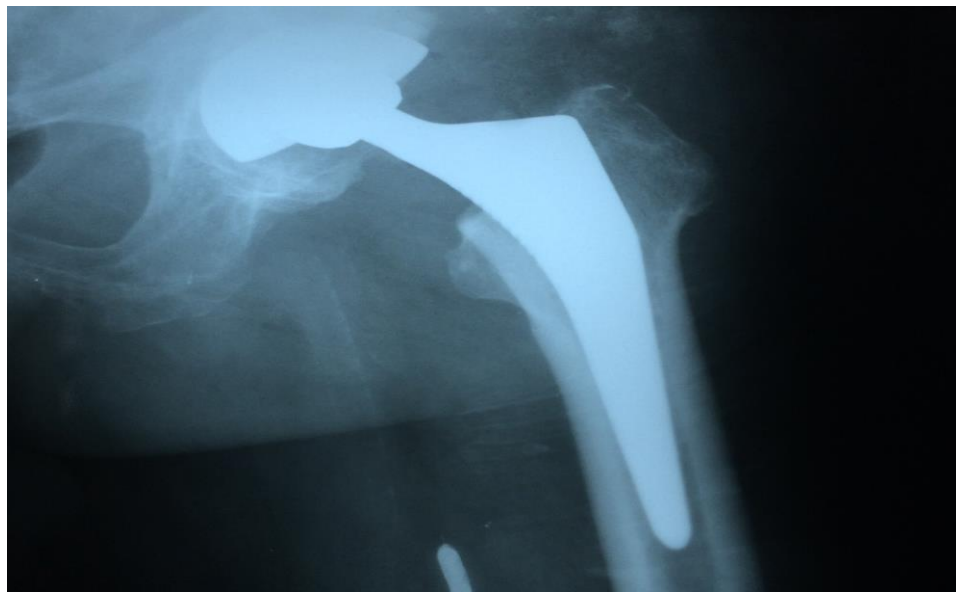

**X-ray 1: Pre-OP**



**Xray 2: Immediate Post-OP**

### Case Report



**X-ray 3: Follow-up at 12 months**

Kim *et al.*'s study in three year follow up of patients with bilateral hip ankylosis who underwent joint replacement surgery reported that HHS mean of 55.4 reached 82.3 which were similar to this study. Also in the survey conducted by He *et al.*, the HHS of 15-21 before surgery increased to 86.25 just like our study. In our study we used posterior approach as the surgical modality.

Intra and post operative complications can affect treatment results. In our present study of twelve months follow up we did not have any complications of the surgery. There is a probability of complications in any surgery but the frequency of these complications is different according to the type of surgery, its complexity and surgeon's skill level. Moreover prevention of surgical complications or prosthesis failure can contribute to improved treatment outcomes and consequently improve patient and physician satisfaction.

Engh's criteria were used to assess the radiological evaluation of uncemented femoral component. Radiological evaluation of loosening for uncemented acetabular component was done using Andrew Whaley and Daniel *et al.*, criteria. It was found at the end of twelve months both acetabular component position and femoral component position were stable and in acceptable position, in our study.

### Conclusion

THA is a promising option for treatment of long term hip ankylosis sequelae, providing better functional outcome especially in painful fibrous ankylosis of hip is a worthwhile and rewarding salvage procedure

### REFERENCES

- Amstutz HC and Sakai DN (1975).** Total joint replacement for ankylosed hips, Indications, technique and preliminary results. *Journal of Bone and Joint Surgery (American Volume)* **57** 619-25.
- Andrew Whaley and Daniel (2001).** Criteria for loosening of uncemented acetabular component. *JBJS* **83A**.
- Bangjian H and Peijian TJUL (2012).** Bilateral synchronous total hip arthroplasty for ankylosed hips. *International Orthopaedics* **36**(4) 697-701.
- Campbell's Operative Orthopaedics (No Date).** *International Edition*, 11<sup>th</sup> edition.
- Charnley-THR (1970).** Low friction arthroplasty clinical orthop.
- Engh's Criteria (1990).** For loosening of uncemented femoral component. *Clinics in Orthopedic Surgery* 257.
- Hamadouche M, Kerboull L and Meunier A (2001).** THA for treatment of ankylosed hips: A 5 year to 21 year follow up study. *Journal of Bone and Joint Surgery (American Volume)* **83-A**(7) 992-8.

### **Case Report**

**Hardinge K, Williams D, Etienne A, MacKenzie D and Charnley J (1977).** Conversion of fused hips to low friction arthroplasty. *Journal of Bone and Joint Surgery (British Volume)* **59**(4) 385-92.

**Hoppenfeld Stanley and De Boer PIET (No Date).** *Surgical Exposures in Orthopaedics*, 4<sup>th</sup> edition.

**Joshi AB, Markovic L, Hardinge K and Murphy JC (2002).** Total hip arthroplasty in ankylosing spondylitis; an analysis of 181 hips. *Journal of Arthroplasty* **17**(4) 427-33.

**Kilgus DJ, Amstutz HC, Wolgin MA and Dorey FJ (1990).** Joint replacement for ankylosed hips. *Journal of Bone and Joint Surgery (American Volume)* **72** 45-54.

**Kim YL, Shin S, Nam KW, Yoo JJ, Kim YM and Kim HJ (2007).** Total Hip Arthroplasty for bilaterally ankylosed hips. *Journal of Arthroplasty* **22**(7) 1037-41.

**Lubahn JD, Evarts CM and Feltner JB (1980).** Conversion of ankylosed hips to total hip arthroplasty. *Clinics in Orthopedic Surgery* **153** 146-52.

**Strathy GM and Fitzgerald RJ(1988).** Total hip arthroplasty in the ankylosed hip. A ten year follow up. *Journal of Bone and Joint Surgery (American Volume)* **70** 963-6.