

Case Report

RARE OCCURRENCE OF PRIMARY SQUAMOUS CELL CARCINOMA OF THE OVARY IN MUCINOUS CYSTADENOMA: A CASE REPORT & REVIEW OF LITERATURE

*Reema Agrawal, Ishita Gupta, Nag B.P. and Narayani Joshi

Department of Pathology, Mahatama Gandhi Medical College, Jaipur

*Author for Correspondence

ABSTRACT

Primary squamous cell carcinoma of the ovary is rare. We studied a 55-year-old lady in whom a squamous cell carcinoma of the ovary had arisen from a mucinous cystadenoma of ovary. The mucinous columnar epithelium was largely benign. The prognosis for primary ovarian squamous cell carcinoma is worse than that of other ovarian epithelial cancers of all histological types. Due to the rarity of the tumour, the effective treatments have not been established.

Keywords: Squamous Cell Carcinoma, Mucinous Cystadenoma, Ovary

INTRODUCTION

Primary squamous cell carcinomas of the ovaries are uncommon. Primary SCC in ovaries was usually reported in association with dermoids, pre-existing Brenner's tumours or endometriosis (Pins *et al.*, 1996). Primary squamous cell carcinoma of ovary arising from mucinous cystadenoma of ovary was scarcely reported (D'Angelo *et al.*, 2010). Here we present another case of primary invasive squamous cell carcinoma arising from a mucinous cystadenoma of the ovary and the review of literature.

CASES

A 55 year old post menopausal lady presented with the chief complaints of lump and pain in abdomen since 8 months. The patient was known hypertensive and diabetic and took ATT 12 years back. Her medical history was otherwise unremarkable.

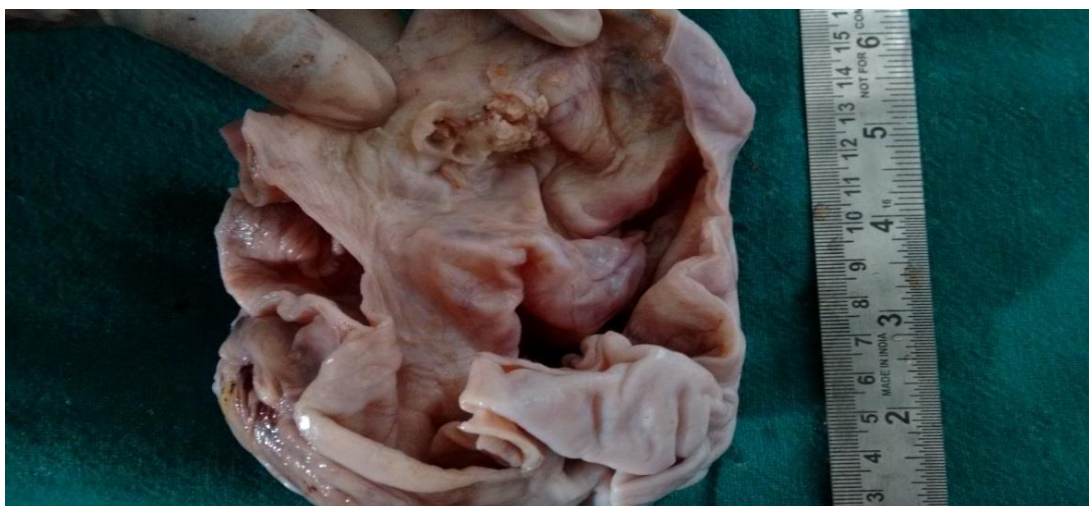

Figure 1: Gross specimen showing a solid mural nodule in the wall of ovarian cyst

Her USG abdomen showed large well defined cystic lesion measuring 20x10x10 cm with multiple septations arising from the pelvic cavity, along with findings suggestive of chronic cholecystitis and cholelithiasis, no evidence of ascites was seen. No obvious abnormality was detected on her chest X-ray. Cervical cytology was normal. She underwent exploratory laparotomy, right salpingo-oophrectomy along

Case Report

with cholecystectomy. The patient was considered to have a stage IA1 disease (FIGO) as uterus, left ovary, other abdominal organs and lymph nodes were not involved.

Pathologic Findings

Right ovarian tumour was 700g, 13cm in diameter, grey white, smooth intra-cystic mass. Cyst wall was intact and there was no evidence of surface involvement. On sectioning, cyst was multilocular and filled with clear fluid. A grey white solid mural nodule measuring 1 cm in diameter was seen on the inner side of the cyst wall (Figure 1). Typical macroscopic features of dermoid cyst such as hair and greasy debris were not seen. The right fallopian tube was unremarkable.

Microscopically, solid sheets of large squamous cells including keratin pearls, in a diffusely infiltrative pattern were seen. Nuclei were pleomorphic, hyperchromatic with scattered, sometimes abnormal mitotic figures (Figure 2). A transition between squamous cell carcinoma and benign mucinous cystadenoma of the ovary was identified (Figure 3). The mullerian type mucinous epithelium composed of columnar mucin secreting cells was identified. Final pathological diagnosis of mural nodule of squamous cell carcinoma arising in mucinous cystadenoma of the ovary was made.

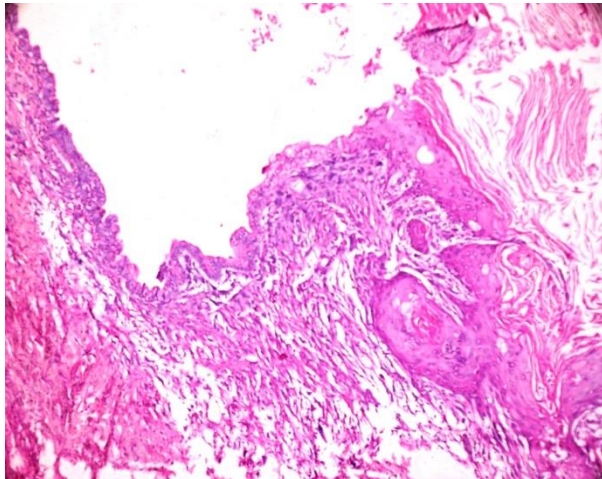


Figure 2: Haematoxylin and eosin stained section showing pleomorphic, hyperchromatic nuclei of squamous cell carcinoma

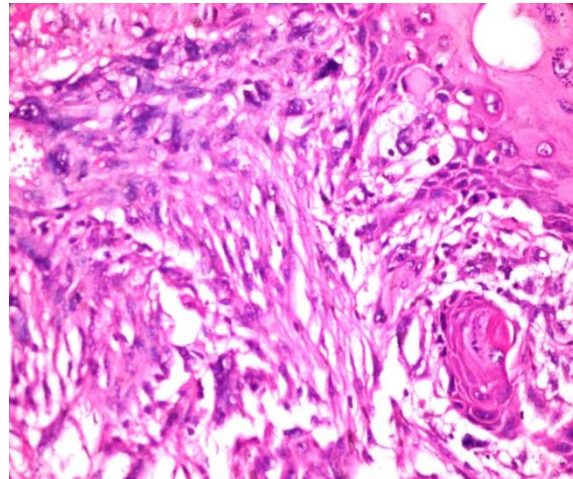


Figure 3: Haematoxylin and eosin stained section showing a transition between squamous cell carcinoma and benign mucinous cystadenoma of the ovary

DISCUSSION

Primary ovarian squamous cell carcinoma is rare, with the majority of cases preceded by dermoid cysts. Few cases of primary ovarian squamous cell carcinoma associated with Brenner's tumour and endometriosis had also been reported by (Pins *et al.*, 1996). Nearly 2% of cases of primary ovarian squamous cell carcinoma originate from the malignant transformation of a dermoid cyst (Peterson *et al.*, 1957). Squamous cell carcinomas constitute 2.5% of metastatic ovarian tumours and majority of cases are due to direct extension from the uterine cervix (D'Angelo *et al.*, 2010). Various types of benign and malignant tumours were reported to arise from mucinous cystadenoma of ovary. However, rare isolated case reports of primary squamous cell carcinoma arising from mucinous cystadenoma of ovary could be found. The exact pathogenesis of malignant nodule in an otherwise benign cystadenoma of the ovary is not well established. However proposed hypothesis of dedifferentiation or a collision tumour could explain the occurrence of primary SCC in mucinous cystadenoma in this case (Desouki *et al.*, 2015). In the female genital tract, dedifferentiation is most well recognized in dedifferentiated endometrioid carcinomas and dedifferentiated leiomyosarcomas (Silva *et al.*, 2006; Rawish and Fadare, 2012). Prat and Scully proposed the concept of collision tumour, which is the result of a collision between two neoplasms that have arisen in adjacent areas (Prat *et al.*, 1982).

Case Report

On account of the fact that SCC is the more common histological type of malignancy in other female genital organs (like cervix, vagina, vulva) and other organs like lungs, head neck etc., thorough evaluation, including the local physical examination, cytological tests, and imaging of these anatomic sites is mandatory in these patients, to rule out the possibility of secondary SCC (Park *et al.*, 2010)

The overall gross appearance and microscopic findings in both the mucinous cystadenoma and squamous cell carcinoma are classic; we feel that immunohistochemical or special studies are not necessary for the definitive diagnosis.

Standard management for epithelial ovarian tumours includes the comprehensive surgical staging and maximum debulking surgery followed by adjuvant chemotherapy or radiotherapy (Mills *et al.*, 2004).

Pins *et al.*, (1996) in their study of 37 cases found advanced clinical stage and high histological grade as predictors of a poor overall survival. However, the age of the patient at diagnosis, size of the tumour, and the presence or absence of necrosis did not correlate with survival. Same study also concluded that the prognosis for primary ovarian squamous cell carcinomas is graver than that of other ovarian epithelial tumours.

Conclusion

In summary, we have reported an exceedingly rare case of squamous cell carcinoma arising in an ovarian mucinous cystadenoma of the ovary. Careful gross examination and extensive sampling are crucial for the correct diagnosis. Since malignant neoplasm within mural nodules has a significant impact on the prognosis of the patients, pathologists have to be able to identify these mural nodules accurately.

Consent: Patient has given their informed consent for the case report to be published.

Competing Interest: The author(s) declare that they have no competing interests.

REFERENCES

- D'Angelo E, Dadmanesh F, Pecorelli S and Prat J (2010).** Squamous cell carcinoma of the ovary arising from a mucinous cystic tumor of endocervical (müllerian) type. *International Journal of Gynecological Pathology* **29**(6) 529-32.
- Desouki MM, Khabele D, Crispens MA and Fadere O (2015).** Ovarian mucinous tumour with malignant mural nodules: dedifferentiation or collision? *International Journal of Gynecological Pathology* **34**(1) 19-24.
- Mills SE, Carter D, Greenson JK, Oberman HA, Reuter VE and Stoler MH (2004).** *Sternberg's Diagnostic Surgical Pathology*, 4th edition (New York, Lippincott Williams & Wilkins).
- Park JY, Song JS, Choi G, Kim JH and Nam JH (2010).** Pure primary squamous cell carcinoma of the ovary: a report of two cases and review of the literature. *International Journal of Gynecological Pathology* **29** 328-334.
- Peterson WF (1957).** Malignant degeneration of benign cystic teratomas of the ovary; a collective review of the literature. *Obstetrical & Gynecological Survey* **12** 793–830.
- Pins MR, Young RH and Daly WJ et al., (1996).** Primary squamous cell carcinoma of the ovary, Report of 37 cases. *American Journal of Surgical Pathology* **20** 823–33.
- Prat J, Young RH and Scully RE (1982).** Ovarian mucinous tumours with foci of anaplastic carcinoma. *Cancer* **50** 300-4.
- Rawish KR and Fadare O (2012).** Dedifferentiated leiomyosarcoma of the uterus with heterologous elements: a potential diagnostic pitfall. *Case Reports in Obstetrics and Gynecology* 534-634.
- Silva EG, Deavers MT and Bodurka DC et al., (2006).** Association of low grade endometrioid carcinoma of the uterus and ovary with undifferentiated carcinoma: a new type of differentiated carcinoma? *International Journal of Gynecological Pathology* **25** 52-8.