

NESIDIOBLASTOSIS IN AN INFANT RARE CASE REPORT

***Swami R and Lakhe R**

*Department of Pathology, Bharati Vidyapeeth (Deemed to be University) Medical College,
Dhankawadi, Pune- 411043*

**Author for Correspondence: drravimswami@gmail.com*

ABSTRACT

Nesidioblastosis is a major cause of persistent hyperinsulinemic hypoglycemia of infancy and is caused by hypertrophy of the pancreatic endocrine islands. Recognition of this entity becomes important due to the fact that the hypoglycemia is so severe and frequent that it may lead to severe neurological damage in the infant manifesting as mental or psychomotor retardation or life-threatening event if not recognized and treated effectively in time. Here we present a case of 48 days old infant presented to pediatric department of Bharati Hospital with febrile seizures. Investigations showed persistent hypoglycemia with high serum insulin levels. The DOTA scan was suggestive of nesidioblastosis which was confirmed on final histopathology.

Keywords: *Nesidioblastosis and Hypoglycemia*

INTRODUCTION

Nesidioblastosis is a major cause of persistent hyperinsulinemic hypoglycemia of infancy and is caused by hypertrophy of the pancreatic endocrine islands. The disease can be categorized histologically into diffuse and focal forms (Qin *et al.*, 2015). Persistent hyperinsulinemic hypoglycemia (PHH) is a functional disorder caused by aberrant insulin release by pancreatic β cells (Ng, 2010). Nesidioblastosis is the major cause of PHH in infants and children, but in adults it is usually a consequence of a solitary insulinoma. Nesidioblastosis has been reported infrequently in adults (Anlauf *et al.*, 2005, Klöppel *et al.*, 2008). The term nesidioblastoma was derived from the Greek words *nesidion* (islet) and *blastos* (germ) and was proposed for an islet cell adenoma. Brown and Young associated severe infantile hypoglycemia with nesidioblastosis. The term nesidiodyplasia was proposed to signify the overpopulation of the pancreas with the β cells coupled with their maldistribution and malregulated function (Brown and Young 1970).

CASE

A 47 days old male child presented with two days history of seizures. The mother was known case of diabetes mellitus and was on insulin. Later on child developed febrile seizures. Laboratory investigations showed glucose of 27 mg/dl (Normal : 70-140 mg/dl). Previous glucose levels were also between 15 – 20 mg/dl. The serum insulin level was 6.4 uIU/ml (Normal: 2.2-19 mg/dl). The clinical diagnosis was hyperinsulinemic hypoglycemia of newborn. The PET CT was done to rule out insulinoma. The scan showed diffuse radiotracer uptake in the distal body of pancreas 12 x 8 x 0 mm which was persistent on delayed image. Physiological uptake was seen in the uncinata process. No evidence of any focal lymphadenopathy or lung nodules seen. No increased uptake was seen in the skeleton.

The GA 68 -DOTA scan showed diffuse increased octreotide receptor expression in distal body of pancreas suggestive of Nesidioblastoma. The child underwent distal pancreatectomy.

We received a specimen of distal part of pancreas along with tail measuring 3 x 1 x 1 cm. The external surface was smooth, cut surface showed normal pancreatic parenchyma.

Histopathological study showed increase in number of islets of Langerhans in intimate association with ducts and ductules together forming ductuloinsular complexes. At places, focal islet cell hyperplasia is noted. Rest of the exocrine pancreas is unremarkable.

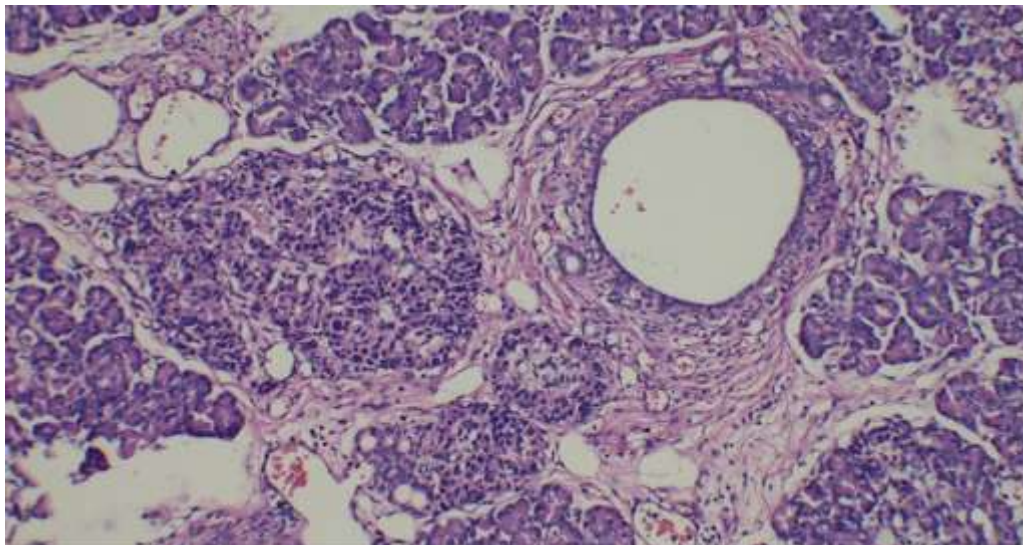


Figure 1: H and E -High power - showing pancreatic ductuloinsular unit.

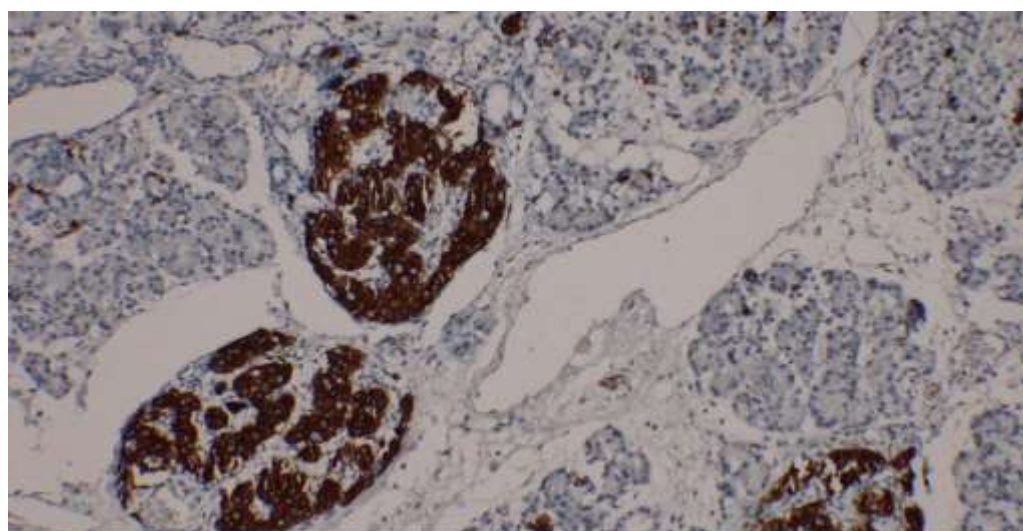


Figure 2: Immunohistochemistry – Synaptophysin – Positive in Islets of Langherhans

DISCUSSION

The clinical presentation, biochemical profile of the patient, and conventional imaging modalities do not show whether the hyperinsulinism is due to a discrete adenoma or to a more diffuse form of nesidioblastosis. The histopathological diagnosis is gold standard for correct final diagnosis. Nesidioblastosis is characterized by the presence of islets in increased numbers throughout the pancreatic lobule in addition to the islets of Langerhans. These islet cells may be present as single cells or in clusters. The histological appearance closely resembles that of third trimester fetal and neonatal pancreas. The histopathology of PHHI is heterogeneous and is hallmarked by the presence of ductoendocrine proliferation, supernumerary small endocrine groups, and large endocrine areas (Goudswaard *et al.*, 1986). The most widely accepted hypothesis for the development of PHHI is the presence of dysfunction of the ATP-dependent potassium channels in the β cells of the pancreas. Focal PHHI is associated with hemizygoty or homozygoty of a paternally inherited mutation of the *SUR* gene or the inwardly rectifying potassium channel genes and loss of the maternal allele in the hyperplastic islets (Lindley *et al.*, 1996; and Aynsley-Green *et al.*, 1998).

Case Report

Conclusion

Nesidioblastosis is a rare disorder affecting children as well as adults resending as life threatening hypoglycemia, hence correct clinical and timely histopathological diagnosis will be lifesaving for the patient.

REFERENCES

- Anlauf M, Wieben D, Perren A et al., (2005).** Persistent hyperinsulinemic hypoglycemia in 15 adults with diffuse nesidioblastosis: Diagnostic criteria, incidence and characterization of beta-cell changes. *American Journal of Surgical Pathology* **29** 524-533.
- Aynsley-Green A, Dune MJ, James RF, Lindley KJ (1998)** Ions and genes in persistent hyperinsulinemic hypoglycemia in infancy: A commentary on the implications for tailoring treatment to disease pathogenesis. *Journal of Pediatric Endocrinology and Metabolism* **11** 121–9.
- Brown RE, Young RB (1970).** A possible role for the exocrine pancreas in the pathogenesis of neonatal leucine-sensitive hypoglycemia. *American Journal of Digestive Diseases.* 15 65–72.
- Goudswaard WB, Houthoff HJ, Koudstaal J, Zwierstra RP (1986).** Nesidioblastosis and endocrine hyperplasia of the pancreas: A secondary phenomenon. *Human Pathology* **17** 46–54.
- Klöppel G, Anlauf M, Raffel A et al. (2008).** Adult diffuse nesidioblastosis: Genetically or environmentally induced? *Human Pathology* **39** 3-8.
- Lindley KJ, Dunne MJ, Kane C, Shepherd RM, Squires PE, James RF et al. (1996)** Ionic control of β cell function in nesidioblastosis. A possible therapeutic role for calcium channel blockade. *Archives of Diseases in Children* **74** 373–8.
- Ng CL (2010).** Hypoglycaemia in nondiabetic patients - an evidence. *Australian Family Physician* **39**, 399-404.
- Qin H, Li Z, Qu L, Liu Y, Gao Y, Li F, Wang G (2015).** A rare case of focal nesidioblastosis causing adult-onset hypoglycemia. *Experimental and Therapeutic Medicine.* Aug 1, **10**(2) 723-6