Indian Journal of Medical Case Reports ISSN: 2319–3832
Online, International Journal, Available at http://www.cibtech.org/jcr.htm
2026 Vol.15, pp. 3-6/Radha and Shilpa
Case Report (Open Access)

DESMOID-TYPE FIBROMATOSIS OF THE BREAST: A DIAGNOSTIC CHALLENGE

***S. Radha, K. Shilpa Madhuri**
Department of Pathology, Arundathi Institute of Medical Sciences
**Author for Correspondence: sistla.radha@gmail.com*

ABSTRACT
Desmoid-type fibromatosis of the breast is a rare, locally aggressive fibroblastic/myofibroblastic neoplasm, accounting for a very small proportion of breast tumours. It represents 0.2% of breast tumors. It was first reported in 1832 and arises from Musculo aponeurotic structures. Although it does not metastasize, it may exhibit infiltrative growth and a tendency for local recurrence. Its clinical and radiological presentation may closely mimic breast carcinoma.

Keywords: *Breast; Desmoid-Type Fibromatosis; Beta-Catenin; Spindle-Cell Lesion; Case Report*

INTRODUCTION
Fibromatosis usually originates from fascia and is common in abdominal wall or shoulder and pelvic girdles. Fibromatosis of breast is unusual and is locally aggressive. It may arise from pectoral muscle or fascia of mammary tissue. It arises from fibroblasts or myofibroblasts of breast parenchyma. It is prone for recurrence.

CASE
We report a case of a 50-year-old woman who presented with a six-month history of a large swelling involving the right breast, associated with dull aching pain. There was no history of previous breast surgery. There was no family history of breast tumors. Clinical examination revealed a large, fixed mass occupying the entire breast, with stretched overlying skin and nipple retraction. Ultrasonography demonstrated a large solid lesion with a few cystic areas, categorized as BI-RADS 5. Fine-needle aspiration cytology was inconclusive due to scant cellularity and was reported as Yokohama Category I (insufficient/inadequate). With a clinical diagnosis of phyllodes tumor, simple mastectomy was performed.

Pathological Findings:

The received simple mastectomy specimen measured 21 × 19.5 × 19.5 cm. The overlying skin was thin and stretched. On cut section, a firm, lobulated, grey-white mass was identified (Fig- 1). Few cystic and mucoid areas were also noted.

Microscopic examination revealed a paucicellular spindle-cell lesion arranged in bundles and fascicles within abundant fibro-myxoid stroma. The cells exhibited bland cytological features, with vesicular chromatin and tapering cytoplasmic processes. Mitotic figures were sparse. There are no areas of necrosis. There was collagen deposition focally. No interspersed glandular elements were identified. Compressed breast tissue is seen at the periphery. (Figure 2. a, b, c). All the resected margins were free of tumor.

Based on the morphological features, the differential diagnoses considered included low-grade fibro myxoid sarcoma, desmoid-type fibromatosis, solitary fibrous tumour and metaplastic carcinoma.

Immunohistochemical evaluation demonstrated diffuse, strong nuclear positivity for beta-catenin (Figure- 2. d) and focal positivity for smooth muscle actin (SMA). The lesional cells were negative for pan cytokeratin (PanCK), MUC4, CD34, BCL2 and STAT6.

Correlating the histomorphological and immunohistochemical findings, a final diagnosis of desmoid-type fibromatosis of the breast was rendered.



Figure 1: Gross specimen photograph showing a grey white lesion measuring 21x19cms. Cut surface is myxoid.

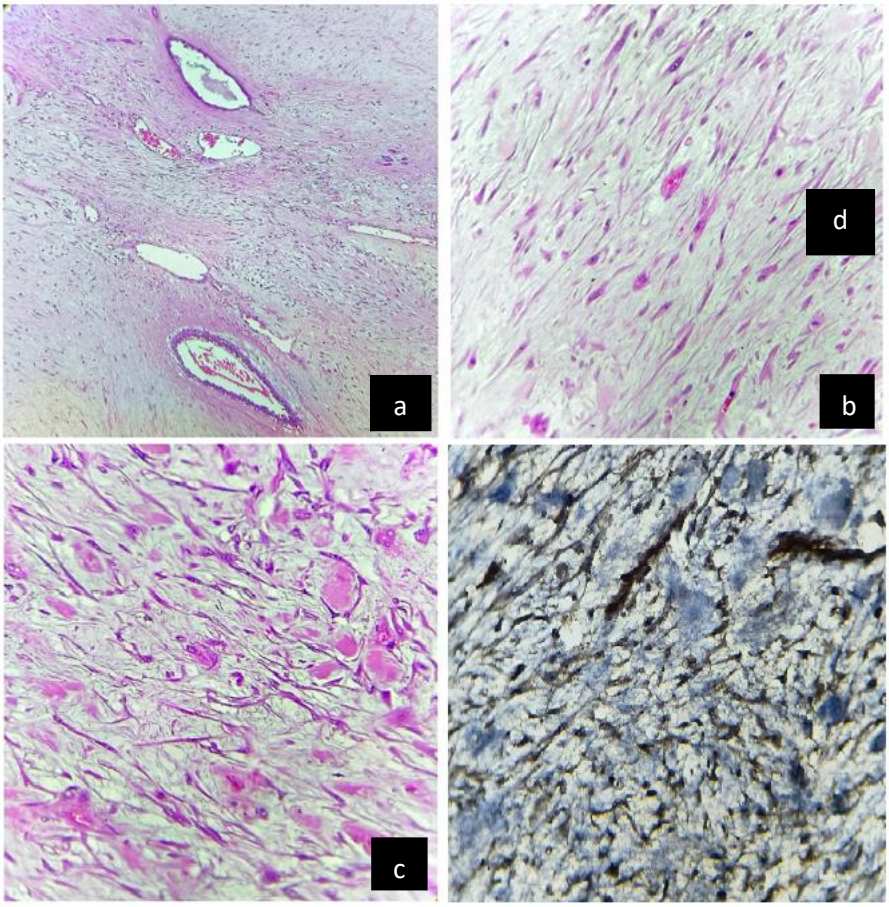

Figure 2: a) Breast tissue with lesion (H&E x40)
b) Pauci cellular spindle cell lesion with extensive myxoid change (H&E x100)
c) Spindle cells with interspersed collagen(H&EX400)
d) Immunohistochemistry showing nuclear Beta catenin positivity(H&EX400)

DISCUSSION

Desmoid-type fibromatosis is a rare mesenchymal neoplasm arising from musculoaponeurotic structures and is also referred to as aggressive fibromatosis (Zhao *et al.,* 2025). Based on anatomical location, it is broadly classified into intra-abdominal, abdominal-wall and extra-abdominal types. Extra-abdominal fibromatosis may occur in the head and neck, chest wall, paraspinal region, shoulder, hip and buttock (Tao *et al.,* 2024).

Breast involvement is exceptionally rare, with an estimated incidence of approximately four to five cases per million women annually. It accounts for less than 0.2% of breast tumours. These lesions are usually unilateral and solitary. Bilateral and multicentric presentations have also been described (Yazidi *et al.,* 2021; Garg *et al.,* 2014).

In the breast, fibromatosis may arise from the pectoral fascia or mammary parenchyma. Mammary fibromatosis is believed to originate from fibroblasts and myofibroblasts within the breast tissue. It commonly presents as a firm, poorly circumscribed mass and may cause skin or nipple retraction, thereby mimicking invasive breast carcinoma.

The pathogenesis of desmoid-type fibromatosis involves alterations in the Wnt/beta-catenin signalling pathway. Sporadic cases are commonly associated with activating mutations in the CTNNB1 gene, whereas cases associated with familial adenomatous polyposis involve mutations in the APC gene. Associations with Gardner syndrome, previous surgical trauma and familial adenomatous polyposis have been described. Breast implants have also been reported as a possible associated factor.

Histologically, desmoid-type fibromatosis is characterized by bland spindle cells arranged in long fascicles within a collagenous or variably myxoid stroma. Nuclear beta-catenin immunoreactivity is an important diagnostic finding and supports the diagnosis in the appropriate morphological context.

In the present case, the large breast mass, skin stretching, and nipple retraction raised a strong clinical suspicion of malignancy. The paucicellular nature of the aspirate resulted in an inconclusive cytological diagnosis. Histopathological examination revealed a bland spindle-cell proliferation with extensive fibro-myxoid stroma. The immunohistochemical profile, particularly diffuse nuclear beta-catenin positivity, supported the diagnosis of desmoid-type fibromatosis.

The absence of pan cytokeratin expression argued against metaplastic carcinoma, while negative CD34 and STAT6 expression did not support solitary fibrous tumour. MUC4 negativity was also useful in the differential diagnosis of low-grade fibro myxoid sarcoma.

Although desmoid-type fibromatosis does not metastasize, it is locally aggressive and may recur following treatment. Therefore, long-term clinical follow-up is important. Treatment should be individualized according to tumour size, anatomical extent, symptoms and surgical considerations.

CONCLUSION

Desmoid-type fibromatosis is an uncommon breast lesion that can mimic malignancy clinically and radiologically. It should be considered in the differential diagnosis of spindle-cell lesions of the breast. Histopathological examination supplemented by immunohistochemistry plays an important role in establishing the diagnosis. The patient is on regular follow up and there is no evidence of recurrence till date.

REFERENCES

Garg P, Chufal SS, Gupta N, Pant P, Thapliyal NC. (2014). Multicentric aggressive mammary fibromatosis with cytological features and review of literature. *Journal of Clinical and Diagnostic Research*, **8**(5): FD01–FD03 *https://doi.org 10.7860/JCDR/2014/6056.4328*

Tao Y, Zeng K, Wan X, Wen W, Chen H, Peng Y. (2024). Rare desmoid-type fibromatosis of the breast in young female patients: a description of three cases and literature analysis. *Quantitative Imaging in Medicine and Surgery*, **14**(4): 3194–3203. *https://doi.org/10.21037/qims-23-158*

Yazidi TA, Aghbari SA, Qassabi BA, Riyami MA. (2021). Breast fibromatosis case series and literature review. *International Journal of Surgery Research and Practice*, **8**(1): 123. *https://doi.org/10.23937/2378-3397/1410123*

Zhao Z, Shang Q, Yang C, Liu J, Liu S, Li X, Kang X, Yue J, Wang X, Wang X. (2025). Desmoid-type fibromatosis of the breast: a case report and literature review. *Frontiers in Oncology*, **15**: 1482024. *https://doi.org/10.3389/fonc.2025.1482024*