

Research Article

EFFECTS OF ALUMINIUM EXPOSURE ON CAUDA EPIDIDYMIS OF WISTAR RATS

Geeta Pandey¹, *G C Jain¹ and Hemant Pareek²

¹Department of Zoology, Centre for Advanced Studies, University of Rajasthan, Jaipur, India

²Department of Zoology, S. K. Government Post-Graduate College, Sikar, India

*Author for Correspondence

ABSTRACT

Aluminium (Al), the most prevalent metal in the earth's crust, is known to induce a broad range of physiological, biochemical and behavioral dysfunctions in laboratory animals and humans. Humans are frequently exposed to Al from various food additives, therapeutic treatments, and the environment. The present study was carried out to evaluate toxic effects induced by aluminum chloride (AlCl₃) on cauda epididymis of rats and also to study the reversibility of the adverse effects. Male Wistar rats were randomly divided into four groups. Group I served as control and received vehicle treatment. Rats of Group II, III and IV were treated with AlCl₃ at different doses (30, 60 and 90 mg/kg b.wt/day, orally) for 60 days. Each Group I, II and III had 8 rats while Group IV had 16 rats. Half of the rats of Group IV were left for recovery for 60 days after treatment withdrawal to observe reversibility of the adverse effects. The results revealed that aluminium chloride (AlCl₃) treatment induced a significant decrease in the contents of protein, glycogen and sialic acid in the cauda epididymis while the levels of total cholesterol significantly increased as compared to control rats. AlCl₃ treatment also enhanced lipid peroxidation (TBARs) significantly and resulted in a significant decline in the activity of superoxide dismutase and the levels of glutathione and ascorbic acid. Administration of AlCl₃ at 30, 60 and 90 mg/kg b.wt /day resulted in a significant decline in the sperm count as well as in the percentage of motile and viable spermatozoa in the cauda epididymis of rats when compared with control rats. The histoarchitecture of the cauda epididymis of rats treated with different doses of AlCl₃ showed dose dependent degenerative and atrophic changes. There was significant reduction in the tubular epithelial cell height and increase in the intertubular connective tissue. The lumen showed presence of sperm debris and scanty spermatozoa. After 60 days of treatment withdrawal, all the biochemical and antioxidant parameters returned towards normal side. Histomorphological picture of the cauda epididymis also showed significant improvement. Based on these results, it can be concluded that AlCl₃ intoxication induced toxic effects on cauda epididymal histoarchitecture and sperm parameters of rats by causing increased oxidative stress and decline in antioxidant defense parameters.

Keywords: Aluminium Chloride, Lipid Peroxidation, Sperm Count & Motility, Cauda Epididymis

INTRODUCTION

Aluminum (Al) is a member of group III A of the periodic table, with atomic number 13 and atomic weight 26.97. Aluminium is released and dispersed in the environment by natural processes as the weathering of rocks and minerals as well as from human activities like the mining and processing of aluminum ores (Verstraeten *et al.*, 2008).

The general population is principally exposed to aluminum through the consumption of food items, through drinking water and inhalation of ambient air (Kumar and Gill, 2009). The major contributors to dietary aluminium intakes are especially corn, yellow cheese, salt, herbs, spices, tea, cosmetics, food additives, aluminium utensils ware and containers.

Aluminum compounds are added during processing of foods, such as: flour, baking powder, coloring agents and anticaking agents (ATSDR, 2008).

Aluminium-containing utensils and wrappings can increase its amount in foods, particularly if the foods are acidic, basic or salty. Use of aluminium salts as coagulants in water treatment may lead to increased concentrations of aluminium in finished water (EFSA, 2008). Other sources of aluminium exposure

Research Article

include pharmaceutical products and a number of topically applied consumer products (Reinke *et al.*, 2003).

In humans and experimental animals, the oral bioavailability of aluminium is approximately 0.3% from drinking water whereas about 0.1% from food and beverages (ATSDR, 2008). Approximately 0.1–0.6% of ingested aluminum is usually absorbed via gastrointestinal tract. This is probably due to the formation of insoluble aluminium phosphate that cannot be absorbed and is subsequently excreted in the faeces (Spencer & Lender, 1979). Once absorbed, it binds to various ligands in the blood and distributes to every organ, with highest concentrations found in bone and lung tissues. It is mainly transported by plasma transferrin in its sites left vacant by iron, and to a much lesser extent by albumin. Greater than 95% of aluminium is eliminated by the kidney and ~ 2% is excreted in bile (Berthon, 1996). The median lethal oral dose of aluminium chloride was found to be 850 mg/kg body weight (Spector, 1956).

Aluminium has been reported as a potential toxicant for the male reproductive system as manifested by reduction in testicular and accessory sex organ weight (Llobet *et al.*, 1995; Trif *et al.*, 2007); decreased epididymal sperm count, viability and motility (Yousef *et al.*, 2005b; Ige and Akhige, 2012) and disrupted steroidogenesis (Guo *et al.*, 2001; Mayyas *et al.*, 2005) in aluminium exposed organisms. In addition, aluminium can also induce oxidative stress and adverse effects on sexual behavior, territorial aggression, fertility and reproduction in males (Pandey and Jain, 2013)

MATERIALS AND METHODS

Aluminium chloride (AlCl₃) was procured from Merck, India Ltd., Mumbai, India. All other chemicals used in the study were of analytical-reagent grade. Adult, healthy, male albino rats (Wistar strain) of proven fertility were initially procured from IVARI Izzatnagar, Bareilly (U.P.), India and from these a colony was established in the animal house facility of the department. The subsequent progeny of these rats were used for experimental purpose. The rats were housed in groups in polypropylene cages measuring 12" X 10" X 8" under standard laboratory condition of light-dark cycle (14hr-10hr) and temperature (22±30C) and provided water and a nutritionally adequate pallet diet (Aashirwad Food Industries, Chandigarh, India) *ad libitum*.

The animal care and handling were done according to the guidelines set by Indian National Science Academy (INSA, 1992 New Delhi, India) for maintenance and use of experimental animals. The study was approved by the Animal Ethical Committee of the Department of Zoology, University of Rajasthan, Jaipur.

Male rats of proven fertility were selected and then randomly divided into four groups each having eight rats except group-IV, which has 16 rats. Group I rats treated with vehicle (distilled water, 0.5 ml/rat/day) for 60 days. Rats of group II, III and IV were treated with aluminium chloride (30, 60 and 90 mg/kg b.wt./day dissolved in distilled water) orally, for 60 days. Reversibility of the adverse effects was also observed after 60 days of the treatment withdrawal in group-IV.

Autopsy Schedule

Twenty four hours after administration of the last dose, all the overnight fasted rats from various treated groups were sacrificed under ether anesthesia. Blood samples were collected by cardiac puncture. The blood sample was allowed to clot at 37⁰C and the serum was separated by centrifugation and stored at -20⁰C for biochemical analysis. Cauda epididymis was fixed in Bouin's fluid for histopathological observations. Remaining half were kept frozen at -20⁰ \-70⁰ C for biochemical estimations.

Sperm Parameters

Sperm Motility and Density

To determine the sperm motility and density (sperm counts), 100 mg of cauda epididymis was minced with a sharp razor blade suspended in 2.0 ml normal saline (0.9% NaCl, 37⁰C). The suspension was passed through a nylon mesh to separate the tissue from the sperm. One drop of the evenly mixed sample was applied to a Neubauer's counting chamber under coverslip. Quantitative motility expressed as percentage was determined by counting both motile and immotile spermatozoa in deferent areas under

Research Article

light microscope at a magnification of X100. Sperm counts were made by the routine procedure and expressed as million/ml of suspension (Prasad *et al.*, 1972).

Sperm Viability

Sperm vitality was assessed by nigrosin-eosin staining method. One drop of the 1% aqueous solution of eosin-y and 10% aqueous solution of nigrosin was placed in a microcentrifuge tube. A drop of well mixed sperm sample was added to it and mixed thoroughly. The mixture was dropped on a glass slide and observed under X 400 magnification. The percentage of alive (without stain) and dead (red) cells were determined by at least counting 200 cells (Bjorndahl *et al.*, 2003).

Biochemical Analysis

Frozen reproductive tract tissues were analyzed for total protein (Lowry *et al.*, 1951), Glycogen (Montgomery, 1957), Sialic acid (Warren, 1959), Total Cholesterol (Zlatkis *et al.*, 1953), Fructose (Mann, 1964), Lipid peroxidation (TBARs, Ohkawa *et al.*, 1979), Superoxide dismutase (Marklund and Marklund, 1974), Glutathione (Moron *et al.*, 1979), Ascorbic acid (Roe and Kuether, 1943).

For all quantitative estimations, tissues obtained from different animals of a treated and control group were pooled to prepare the homogenate. At least seven samples from each group were taken and averaged.

Histology

For histological observation, Bouin's fixed cauda epididymis were washed in water to remove excess of fixative, dehydrated in graded series of alcohol, cleared in xylene, embedded in paraffin wax and sectioned at 5 μ m and counter stained in eosin and hematoxylin. Sections were observed for histopathological effects under light microscope.

RESULTS AND DISCUSSION

There was significant decline in the sperm count, percentage of motile and viable sperms in cauda epididymis of aluminium chloride (30, 60 and 90 mg/kg b.wt./day; respectively) treated rats when compared with control group.

After 60 days of treatment withdrawal in 90 mg/kg b.wt./day dose group, a significant improvement in the sperm parameters was noticed when compared with Group-IV (90 mg/kg b.wt./day). Although, it was still low ($P < 0.01$) when compared with control rats.

There was dose dependent decline in the total protein and sialic acid concentration in epididymis ($P < 0.05$, $P < 0.01$, $P < 0.001$) of rats treated with aluminium chloride (30, 60 and 90 mg/kg b.wt./day; respectively), when compared with control group. However, after 60 days of treatment withdrawal, the total protein and sialic acid concentration was recovered significantly in epididymis when compared with rats of Group-IV (90 mg/kg b.wt./day), but it was still low ($P < 0.01$) in comparison to control group.

There was significant dose dependent increase in the glycogen and total cholesterol concentration in epididymis of rats treated with 30, 60 and 90 mg/kg b.wt./day doses of aluminium chloride, respectively. The glycogen level in epididymis was significantly ($P < 0.01$) recovered after 60 days of treatment withdrawal when compared with Group-IV (90 mg/kg b.wt./day) rats, however, it was still significantly higher in epididymis ($P < 0.01$) when compared to control rats, suggesting partial recovery.

There was a dose dependent increase in lipid peroxidation (TBARs) in epididymis ($P < 0.05$, $P < 0.001$, $P < 0.001$) of rats treated with aluminium chloride (30, 60 and 90 mg/kg b.wt./day; respectively) while a significant ($P < 0.05$, $P < 0.001$, $P < 0.001$) dose dependent decrease in superoxide dismutase (SOD) activity as well as in content of glutathione and ascorbic acid was recorded in epididymis of aluminium chloride (30, 60 and 90 mg/ kg b. wt/day; respectively) treated rats in comparison to control rats.

After 60 days of cessation of aluminium chloride treatment, a significant decrease ($P < 0.01$) in lipid peroxidation (TBARs) while improvement in the content of ascorbic acid, glutathione and activity of superoxide dismutase in epididymis was noticed as compared to rats of Group-IV (90 mg/kg b.wt./day), although its level was still high ($P < 0.01$) in comparison to control.

Research Article

In cauda epididymis of control rats, large compactly packed tubules with little intertubular tissue were observed. The tubules were lined with columnar cells bearing stereocilia at adluminal surface. The lumen is full of spermatozoa (Figure 1, 2).

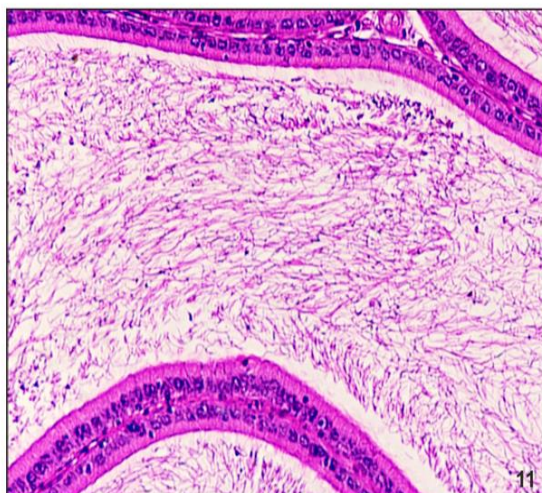


Figure 1: Photomicrograph of the Cross Section of Cauda Epididymis of Control Rat Showing Normal Histoarchitecture (H.E. X 200)

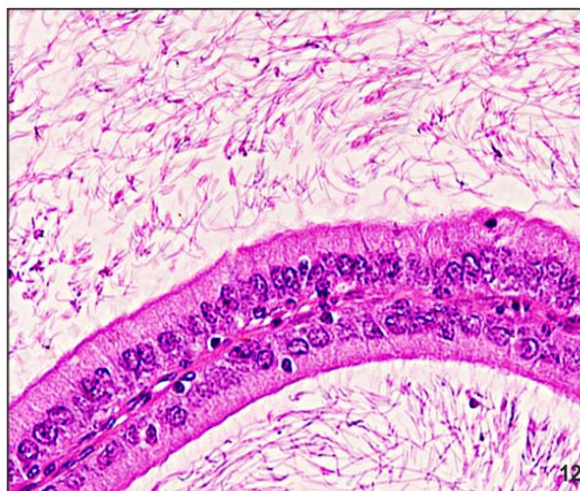


Figure 2: Photomicrograph of the Same at Higher Magnification. Note Closely Packed Tubules Lined with Low Columnar Cells with Prominent Nucleus, Bearing Stereocilia and a Large Number of Densely Packed Spermatozoa in the Lumen (H.E. X 400)

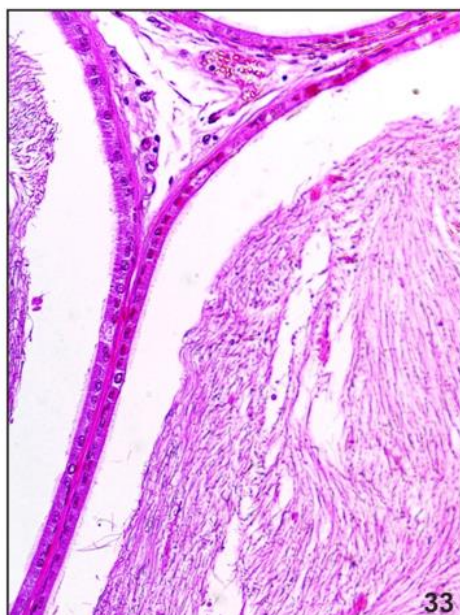


Figure 3: Photomicrograph of the Cross Section of Cauda Epididymis of Aluminium Chloride (30 mg/kg b.wt/day) Treated Rat Showing Degenerative Changes (H.E. X 200)

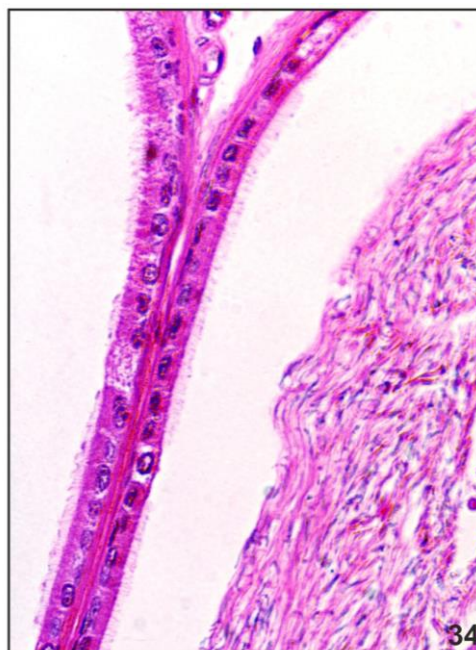


Figure 4: Photomicrograph of the same at Higher Magnification Displaying Reduction in the Epithelial Cell Height, Increase in Intertubular Stroma and Decline in the Number of Spermatozoa in Lumen (H.E. X 400)

Research Article

The histoarchitecture of the cauda epididymis of rats treated with aluminium chloride (30 mg/kg b.wt./day) showed degenerative changes. There was reduction in the tubular size and epithelial cell height ($P < 0.05$) accompanied with slight increase in intertubular connective tissue. The number of spermatozoa was significantly declined in the lumen as compared to control rats (Figure 3, 4).

The incidences and grades of the histological changes in cauda epididymis in rats treated with 60 mg/kg b.wt./day dose were manifested by extensive degenerative changes in epithelial cells of cauda epididymis, reduction in epithelial cell height, degenerative changes and vacuolization in the epithelial cells, short and scanty stereocilia, increase in the intertubular connective tissue, presence of cell debris as well as depletion of spermatozoa count in tubular lumen (Figure 5, 6).

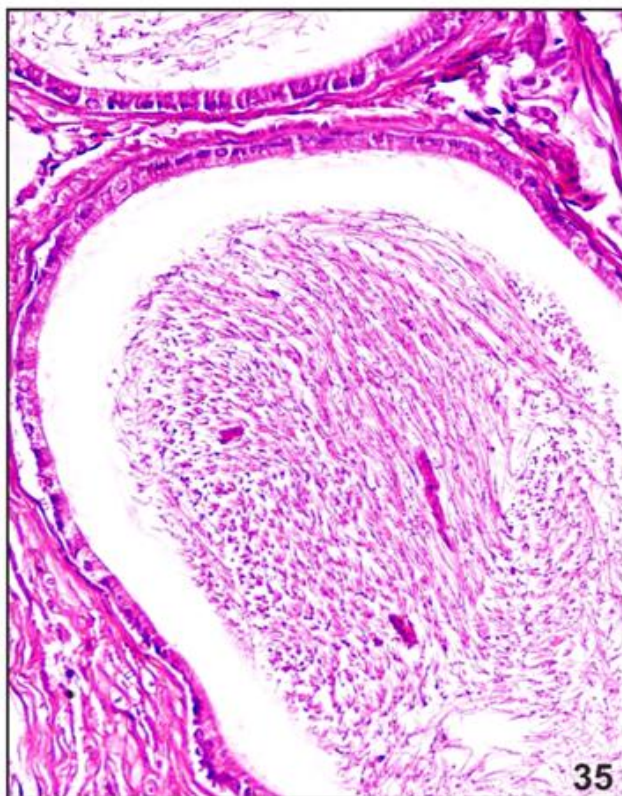


Figure 5: Photomicrograph of the Cross Section of Cauda Epididymis of Aluminium Chloride (60 mg/kg b.wt./day) Treated Rat Showing Marked Degenerative Changes in the Epithelial Cells and Decreased Sperm Density in the Lumen (H.E. X 200)

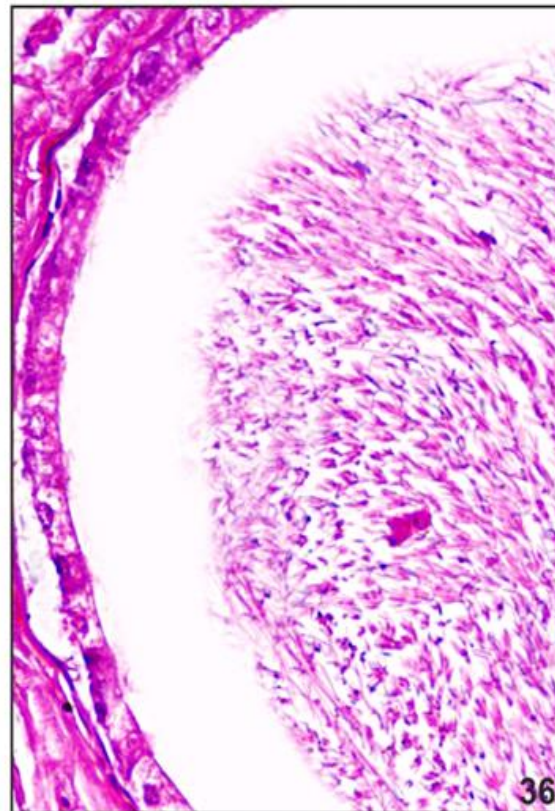


Figure 6: Photomicrograph of the Same at Higher Magnification. Note Reduced Epithelial Cell Height, Absence of Stereocilia and Degenerative Changes in Epithelial Cells. Lumen Contains Lesser Number of Spermatozoa (H.E. X 400)

In 90 mg/kg b.wt./day dose group the luminal epithelium showed extensive marked degeneration and vacuolization in epithelial cells. The epithelial cells lining the lumen were significantly reduced in height and showed almost loss of stereocilia. A relatively large amount of connective tissue was observed between the tubules. Luminal sperms were almost degenerated (Figure 7, 8).

After 60 days of the cessation of treatment (90 mg/kg b.wt./day), the histomorphological observations of the epididymis of rats showed significant recovery of the degenerative effects in tubules. The epididymal epithelial cell height was significantly improved and lumen showed presence of moderate number of spermatozoa (Figure 9, 10).

Research Article

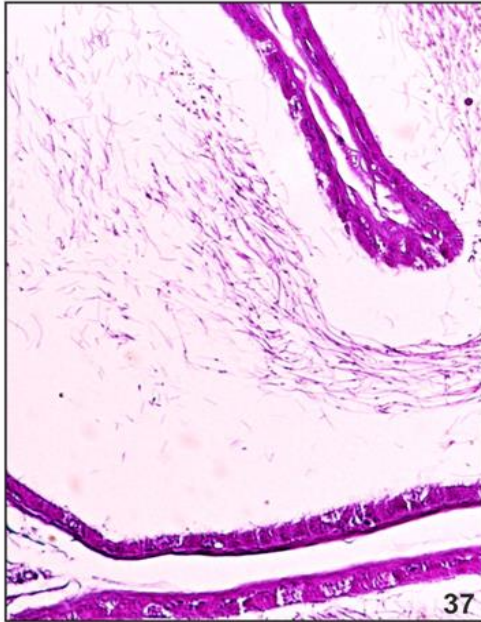


Figure 7: Photomicrograph of the Cross Section of Cauda Epididymis of Aluminium Chloride (90 mg/kg b.wt./day) Treated Rat Showing Marked Degenerative Changes. (H.E. X 200)

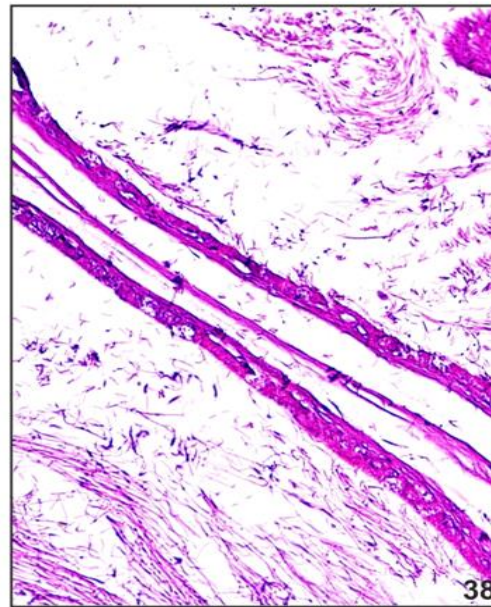


Figure 8: Photomicrograph of the Same at Higher Magnification Showing Degeneration and Vacuolization in Tubular Epithelium Along with Reduction in Tubular Size and Epithelial Cell Height, Disappearance of Stereocilia and Sperm Debris in the Lumen (H.E. X 400)

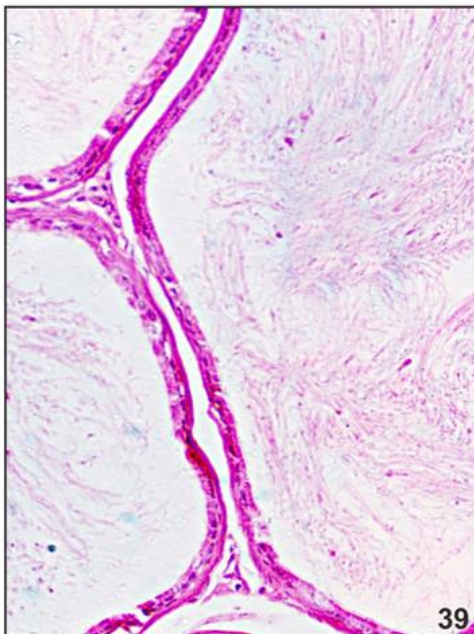


Figure 9: Photomicrograph of the Cross Section of Cauda Epididymis of Rat after 60 Days of Withdrawal of Aluminium Chloride Treatment (90 mg/kg b.wt./day for 60 days) Exhibiting Significant Recovery (H.E. X 200)

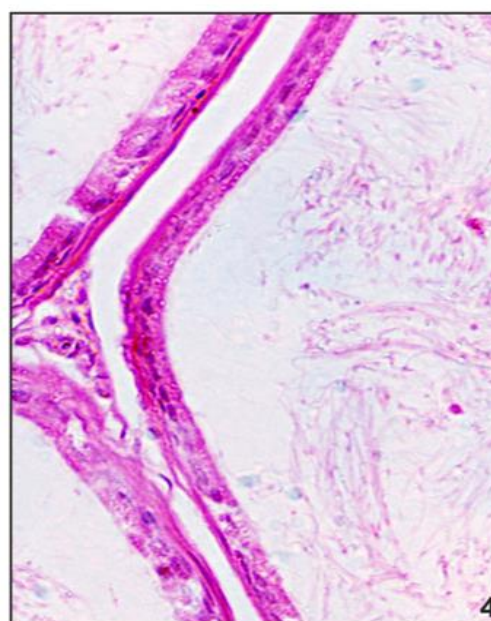


Figure 10: Photomicrograph of the Same at Higher Magnification Showing Increase in Epithelial Cell Height, Presence of Stereocilia and Large Number of Spermatozoa in Lumen. (H.E. X 400)

Research Article

Table 1: Cauda Epididymal Sperm Analysis and Reproductive Performance of Rats Treated with Various Doses of Aluminium Chloride

Treatments	Sperm count (Million / ml)	Sperm motility (%)	Sperm viability (%)
Group-I Control (vehicle)	46.5±1.95	75.08±2.45	82.6±2.99
Group-I Aluminium Chloride (30 mg/kg b.wt./day)	37.66±1.29 a	66.57±3.44 ^a	72.87±3.67 a
Group-II Aluminium Chloride (60 mg/kg b.wt./day)	30.72±1.98 c	41.56±2.52 c	54.5±2.91 c
Group-III Aluminium Chloride (90 mg/kg b.wt./day)	21.85±1.73c	28.26±1.72 c	4..37±2.80 c
Recovery-Group (after 60 days of treatment withdrawal)	35.19±1.86 ^{b **}	61.03±3.11 ^{b ***}	65.87 ±3.90 ^{b **}

Levels of significance: Values represent mean ± SEM (n=8)

ns- Non significant; a- P<0.05; b- P<0.01; c- P<0.001, ammonium molybdate treated groups compared with control group.

+ - non significant; *- P<0.05; **- P<0.01; ***- P<0.001, recovery group compared with group-VII. (One way ANOVA followed by LSD multiple comparison test)

Discussion

Semen is a sensitive indicator of direct toxic effects and hormonal disruption exerted by environmental, occupational and lifestyle exposures of various toxicants (Mendiola, 2009; Morakinyo *et al.*, 2010). Aluminium chloride exposure resulted in a dose dependent significant decline in sperm count, motility and viability. The changes observed in sperm parameters are in agreement with previous reports of aluminium (Yousef *et al.*, 2005b; Khattab *et al.*, 2010) exposure in experimental animals. Khattab, (2007) suggested that aluminium crosses the blood-testis barrier and degenerate spermatogenic cells which disrupted spermatogenesis and resulted in reduced sperm count. The epididymal secretory products also play a vital role in maintenance of sperm structure and function which are also released under the control of androgens. Hence, the reduction in the sperm concentration may be a direct outcome of degeneration/ resorption of sperms due to paucity of such secretory products resulting from reduced testosterone level (Robaire *et al.*, 2006). The deterioration in sperm parameters might be correlated with enhanced lipid peroxidation. Mammalian spermatozoa are rich in poly unsaturated fatty acids which makes them susceptible to oxidative damage. So, decreased level of antioxidants or increased ROS level disrupts the physiological functions of the spermatozoa and impairs motility, viability and structural integrity of spermatozoa (Rivlin *et al.*, 2004). Sperm parameters were significantly improved in aluminium chloride treated recovery group after 60 days of treatment withdrawal possibly via restoration in antioxidant status. The principal cells of epididymal epithelium synthesize a variety of proteins which contributes to the distinctive luminal protein profile within each epididymal region which is thought to be integral for sperm maturation (Caballero *et al.*, 2011). Treatment of aluminium chloride resulted in a significant reduction in the concentration of total protein in epididymis. Androgen regulates the synthesis of epididymal proteins in rats. A significant decline of protein content in cauda epididymides might be due to reduction in secretory activity of the epithelial cells of epididymis because of the androgen deprivation effect (Lasserre *et al.*, 2001). The restoration in the protein content of epididymis towards normal value after 60 days of

Research Article

treatment withdrawal suggests modulation of protein metabolic disturbances. Similar recovery in testicular and epididymal protein content was observed after treatment withdrawal in aluminium treated mice (Chinoy *et al.*, 2005 a, b).

Table 2: Tissue Biochemistry in Epididymis of Rats Treated with Various Doses of Aluminium CHLORIDE

Treatments	Total protein (mg/g)	Glycogen (mg/g)	Sialic acid (mg/g)	Total cholesterol (mg/g)	Acid phosphatase (KA unit)	Alkaline phosphatase (KA unit)	Fructose Seminal vesicle (mg/g)
Group-I Control (vehicle)	221.5 ±6.58	3.50 ±0.13	5.37 ±0.21	6.04 ±0.17	11.57 ±0.42	52.23 ±2.13	5.79 ±0.22
Group-V Aluminium chloride (30 mg/kg b.wt./day)	201.25 ±5.39 ^a	3.88 ±0.11 ^a	4.67 ±0.15 ^a	6.74 ±0.19 ^a	10.39 ±0.28 ^a	44.71 ±1.70 ^b	4.96 ±0.23 ^a
Group-VI Aluminium chloride (60 mg/kg b.wt./day)	191.75 ±5.26 ^b	4.18 ±0.11 ^c	4.30 ±0.20 ^b	7.39 ±0.17 ^b	8.92 ±0.49 ^c	37.01 ±1.38 ^c	4.68 ±0.19 ^b
Group-VII Aluminium chloride (90 mg/kg b.wt./day)	169.12 ±4.62 ^c	4.58 ±0.10 ^c	3.78 ±0.18 ^c	8.39 ±0.19 ^c	6.58 ±0.39 ^c	31.57 ±1.42 ^c	3.90 ±0.18 ^c
Recovery-Group (after 60 days of treatment withdrawal)	194.12 ±6.36 ^{b**}	4.02 ±0.13 ^{b**}	4.52 ±0.22 ^{a**}	6.84 ±0.17 ^{b**}	10.02 ±0.37 ^{b***}	43.53 ±1.26 ^{b***}	4.76 ±0.24 ^{b**}

Levels of Significance: Values represent mean ± SEM (n=8)

ns- Non significant; a- P<0.05; b- P<0.01; c- P<0.001, ammonium molybdate treated groups compared with control group.

+ - non significant; *- P<0.05; **- P<0.01; ***- P<0.001, recovery group compared with group-VII. (One way ANOVA followed by LSD multiple comparison test)

Glycogen has been considered as an energy source in the epididymis and also as a source of the glucose 6- phosphate, required for pentose phosphate pathway (Cooper *et al.*, 1992). An increase in glycogen concentration in epididymis observed in the present study might be due to the reduction of spermatozoa count in epididymal lumen which leads to underutilization of glycogen, resulting in its accumulation in epididymis (Vijayaraghavan *et al.*, 1996). The increased level of glycogen in epididymis showed significant recovery after 60 days of treatment withdrawal by virtue, of increased utilization by spermatozoa.

Reduced epididymal sialic acid content might contribute to alteration in the structural integrity of acrosome membrane of sperms which in turn could influence their metabolism, motility, viability and fertilizing ability (Levinsky *et al.*, 1983). The results are in accordance with previous researchers who

Research Article

also reported similar decline in sialic acid in epididymis due to the antiandrogenic or antispermatogenic impact of the metals (Chinoy *et al.*, 2005 a, b; Jain *et al.*, 2007). The level of sialic acid was significantly improved in aluminium chloride treated rats after 60 days of treatment withdrawal probably due to restoration of androgen level.

Table 3: Lipid Peroxidation and Antioxidant Defense System Markers in Epididymis of Rats Treated with Various Doses of Aluminium Chloride

Treatments	Lipid peroxidation (TBARs) (n mol tissue)	MDA/mg	SOD (unit/mg protein)	Glutathione (n mol/g tissue)	Ascorbic acid (mg/g tissue)
Group-I Control (vehicle)	1.71±0.09		8.19±0.21	2.98±0.10	1.42±0.05
Group-II Aluminium chloride (30 mg/kg b.wt./day)	2.05±0.10 ^a		7.32±0.25 ^a	2.57±0.12 ^a	1.16±0.04 ^b
Group-III Aluminium chloride (60 mg/kg b.wt./day)	2.25±0.11 ^c		6.86±0.23 ^c	2.25±0.10 ^b	0.95±0.06 ^c
Group-IV Aluminium chloride (90 mg/kg b.wt./day)	2.85±0.13 ^c		6.08±0.20 ^c	1.98±0.10 ^c	0.73±0.04 ^c
Recovery-Group (after 60 days of treatment withdrawal)	2.09±0.13 ^{a**}		7.05±0.23 ^{b**}	2.40±0.10 ^{b**}	1.15±0.04 ^{b***}

Levels of significance: Values represent mean ± SEM (n=8)

ns- Non significant; a- P<0.05; b- P<0.01; c- P<0.001, ammonium molybdate treated groups compared with control group.

+- non significant; *- P<0.05; **- P<0.01; ***- P<0.001, recovery group compared with group-VII. (One way ANOVA followed by LSD multiple comparison test)

Cholesterol derivatives such as oxysterols play an integral role in the regulation of epididymal function. It is essential for the maintenance of epididymal epithelium and subsequently sperm maturation (Cornwell, 2009). Adams and Johnson, (1977) reported a decline in the epididymal cholesterol as spermatozoa pass through the rat epididymis. Thus, the utilization of lipids as source of energy during spermatozoa transit through the epididymis has been postulated in a number of mammalian species.

Increased cholesterol level in epididymis might be correlated with disturbed catabolism or transport of cholesterol. Moreover, less uptake of cholesterol by spermatozoa might be another possible reason for the elevation in cholesterol concentration which is consistent with reduced epididymal sperm count observed in present study. The increased level of cholesterol content in epididymis showed significant decline after 60 days of treatment withdrawal probably due to restored sperm count in epididymis.

It has been suggested that ACP activity was markedly reduced in the epithelial cells of epididymis by orchidectomy (Goyal and Vig, 1984). Thus, it might be possible that decline activity of ACP in the epididymis is due to decreased activity of spermatozoa reflecting reduced androgen output. ALP plays a key role in the transport of molecules between the epithelium principal cells and capillaries of the sub-epithelial connective tissue in epididymis and in the maturation of spermatozoa into the luminal compartment of the epididymis (Adams, 1983). Similar decline in the activity of epididymal alkaline

Research Article

phosphatase was observed in animals exposed with aluminium (El- Demerdash, 2004), chromium (Dey and Roy, 2009), mercury (Saxena and Kumar, 2004) and stannous chloride (El-Demerdash *et al.*, 2005)

Decreased activity of epididymal acid phosphatase appeared to be reversible after 60 days of cessation of treatment in highest dose group by virtue of androgen restoration. Similarly, improved activity of ALP in rats after 60 days of treatment withdrawal suggesting partial modulation of the degenerative effects.

The epididymides possess antioxidant defense system to protect spermatozoa from oxidative injury by secreting antioxidant enzymes under steroid regulation. It is known that on the way from caput to cauda epididymis, the sperm membrane become richer in unsaturated fatty acids and therefore, the membrane becomes more prone to peroxidation damage (Marchlewicz *et al.*, 2007). Rats treated with aluminium chloride exhibited an increase in lipid peroxidation in the epididymis which could be due to the concomitant increase in the generation of free radicals or reduced content/ activity of antioxidants in epididymis. Similar elevation in the levels of thiobarbituric acid-reactive substance (TBARs) in epididymis was reported in aluminium (Yousef and Salama, 2009) treated rats. It has also been suggested that the ionic radii of Al^{3+} most closely resemble those of Fe^{3+} , therefore the appearance of Al^{3+} in Fe^{3+} sites is probable. Aluminium is known to be bound by the Fe^{3+} carrying protein transferrin, thus, reducing the binding of Fe^{2+} . The increase in free intracellular Fe^{2+} might cause the peroxidation of membrane lipids and thus, causes membrane damage (Nehru and Anand, 2005).

The reduced activity of SOD and level of GSH may be due to increased utilization in trapping free radicals generated due to toxic effect of aluminium in epididymis. Super oxide dismutase requires copper and zinc for its functional activity and stability. It has been suggested that aluminium can induce abnormal metabolism or displacement of metals like Zn and Cu which might be one of the possible reasons of reduced SOD activity as observed in present study (Guo *et al.*, 2002).

Aluminium might affect the glutathione (GSH) synthesis by inhibiting NADPH-generating enzymes such as glucose 6-phosphate dehydrogenase and NADP-isocitrate dehydrogenase. Since, NADPH is shown to be a main factor for the GSH regeneration, the decreased GSH level could be also ascribed to insufficient supply of NADPH (Yousef and Salama, 2009; Yousef *et al.*, 2004). Nehru and Anand, (2006) suggested that aluminium exposure decrease the ATPase activity which in turn could result in glutathione synthesis alteration.

Significant decline of ascorbic acid in epididymis of aluminium chloride treated rats also indicate oxidative stress which is correlated with decline of sperm count, motility and viability. Since, ascorbic acid is protective antioxidant vitamin in the epididymis (Colagar and Marzony, 2009). The activities of SOD as well as levels of GSH and ascorbic acid were partially but significantly increased in epididymis of aluminium chloride recovery group after 60 days of treatment withdrawal suggesting reduced lipid peroxidation and free radical generation concomitantly with an improvement of antioxidant defense system.

In the present study a dose dependent regressive changes in cauda epididymis were observed in rats treated with aluminium chloride for 60 days duration. The epithelium lining of the lumen showed marked degenerative changes, reduction in epithelial cell height, reduction of the number and length of stereocilia and an increase in the intertubular connective tissue.

The lumen contains sperm debris and only scanty spermatozoa. Alterations in the histopathological picture of the epididymis might be attributed to enhanced oxidative stress as observed in present study. Kalaiselvi *et al.*, (2014) suggested that exposure of aluminium chloride induces depletion of antioxidant defense system in epididymis which may lead to disruption in functional and structural integrity of epididymis of adult rats. The histoarchitecture of the epididymis was become significantly normal after 60 days of treatment withdrawal probably due to decline in epididymal lipid peroxidation and improvement in antioxidant defense system.

REFERENCES

ATSDR (2008). *Toxicological Profile for Aluminum.* Agency for Toxic Substances and Disease Registry. (U.S. Department of Health and Human Services, Public Health Service, Atlanta, GA).

Research Article

- Berthon G (1996).** Chemical speciation studies in relation to Aluminium Metabolism and toxicity. *Coordination Chemistry Reviews* **149** 241–280.
- EFSA (2008).** European Food Safety Authority, Scientific Opinion of the Panel on Food Additives, Flavourings, Processing Aids and Food Contact Materials on a request from European Commission on Safety of aluminium from dietary intake. *The European Food Safety Authority Journal* **754** 1-34.
- Guo C, Huang C, Chen S and Wang HG (2001).** Serum and testicular testosterone and nitric oxide products in aluminum-treated mice. *Environmental Toxicology and Pharmacology* **10** 53-60.
- Ige SF and Akhigbe RE (2012).** The role of *Allium cepa* on aluminum-induced reproductive dysfunction in experimental male rat models. *Journal of Human Reproduction Science* **5**(2) 200-205.
- Kumar V and Gill KD (2009).** Aluminium neurotoxicity: neurobehavioural and oxidative aspects. *Archives of Toxicology* **83**(11) 965-978.
- Llobet JM, Colomina MT, Sirvent JJ, Domingo JL and Corbella J (1995).** Reproductive toxicology of aluminum in male mice. *Fundamental and Applied Toxicology* **25** 45-51.
- Mayyas I, Elbetieha A, Khamas W and Khamas A (2005).** Evaluation of reproductive and fertility toxic potentials of aluminium chloride on adult male mice. *Journal of Animal & Veterinary Advances* **4**(2) 224-233.
- Nehru B and Anand P (2005).** Oxidative damage following chronic aluminium exposure in adult and pup rat brains. *Journal of Trace Element Medical Biology* **19** 203-208.
- Pandey G and Jain GC (2013).** A Review on Toxic Effects of Aluminium Exposure on Male Reproductive System and Probable Mechanisms of Toxicity. *International Journal of Toxicology and Applied Pharmacology* **3**(3) 48-57.
- Prasad MRN, Chinoy NJ and Kadam KM (1972).** Changes in succinic dehydrogenase levels in rat epididymis under normal and altered physiological conditions. *Fertility Sterility* **23** 186-190.
- Reinke CM, Breikreutz J and Leuenberger H (2003).** Aluminium in over the counter drugs. Risks outweigh benefits? *Drug Safety* **26**(14) 1011-1025.
- Spector WS (1956).** *Handbook of Toxicology: Acute Toxicities of Solid, Liquid and Gases to Laboratory Animals*, (Philadelphia, PA: W.B. Saunders Publishers) 418.
- Spencer H and Lender M (1979).** Adverse effects of aluminium- containing antacids on mineral metabolism. *Gastroenterology* **76** 603-606.
- Trif A, Muselin F, Argherie D, Dumitrescu E and Măcinic I (2007).** The consequences of chronic exposure to aluminium on some morphological biomarkers of reproductive function (body, genital organs, sexual accessory glands weight, seminiferous tubules diameter) in male rats. *Lucrări Stiințifice Medicină Veterinară* **40** 652-659.
- Verstraeten SV, Aimo L and Oteiza PI (2008).** Aluminium and lead: molecular mechanisms of brain toxicity. *Archives of Toxicology* **82** 789–802.
- Yousef MI, El-Morsy AMA and Hassan MS (2005b).** Aluminium induced deterioration in reproductive performance and seminal plasma biochemistry of male rabbits: Protective role of ascorbic acid. *Toxicology* **215** 97-107.