CIBTech Journal of Surgery ISSN: 2319-3875 (Online)
An Online International Journal Available at http://www.cibtech.org/cjs.htm
2012 Vol. 1(2) September-December, pp.9-12/Kadian et al.

Case Report

RIGHT INTRATHORACIC STOMACH SECONDARY TO CONGENITAL HIATAL HERNIA AND ORGANOAXIAL TORSION – A REPORT OF TWO CASES

***Y.S. Kadian, KN Rattan, S Agarwal and P. Raikwar**
Department of Paediatric Surger, Radiology and Paediatric Medicine
Pt. B.D. Sharma PGIMS, Rohtak
8/UH, Medical Campus, PGIMS, Rohtak, Haryana, India -124001
**Author for Correspondence*

ABSTRACT
Congenital hiatal hernia with herniation of stomach into thorax is not uncommon in children but this herniation is usually seen in midline or on left side. However, right sided intrathoracic stomach with its organoaxial torsion secondary to congenital hiatal hernia is a rare occurrence. Barium meal examination is essential for its diagnosis but plain x-ray of the abdomen can arouse the suspicion of this condition. Surgical correction is the key in management of this anomaly. We are reporting two cases of congenital hiatal hernia with right sided intrathoracic stomach along with organoaxial torsion in paediatric age group who were managed successfully.

***Key Words**: Congenital Hiatal Hernia, Stomach, Organoaxial Torsion*

INTRODUCTION
Congenital hiatal hernia is a condition of herniation of stomach through a diaphragmatic defect separated from the hiatus by crural muscle fibres. It is classified into two types; para-oesophageal or sliding depending on the location of the gastro-esophageal junction in its normal position or displaced into the thoracic cavity (Naunheim, 2000). In clinical practice it is often difficult to identify by roentgenography, endoscopy or even at operation the precise location of the gastoesophageal junction (GEJ). Hence, the mixed varieties of these two types hernias are not uncommonly seen. The herniation of the stomach into thoracic cavity in hiatal hernia is commonly seen on the left side or midline. However, a congenital hiatal hernia with a complete or partial right intrathoracic stomach associated with nonobstructive organoaxial torsion is rarely seen, only few isolated reports are present in the literature (Haddad, 1996).We have successfully managed two cases of hiatal hernia with right intrathoracic stomach. In this report we describe these two rare cases. Moreover the importance of plain x-ray of chest in reaching the diagnosis of this condition will also be discussed.

CASES
Case 1
11 month old male child was admitted with inability to feed and non bilious vomiting- off and on for last few days. On examination the child was lethargic with signs of dehydration. After resuscitation the patient was investigated and his haematological and biochemical parameters were in the normal range. Among the radiological investigation the infantogram was done which revealed two large air fluid levels, one in the retrocardiac mediastinum and the second beneath the left hemidiaphragm (Figure 1) and another x-ray done after few hours revealed a homogeneous soft tissue mass in the retrocardiac mediastinum (Figure 2). On barium meal examination, the stomach is seen herniated into right thoracic cavity with organoaxial torsion and the greater curvature is abutting the lateral thoracic wall (Figure 3). Patient was operated and operative findings were entire stomach and omentum were lying in right chest cavity above the diaphragm and the esophageal hiatus was wide, the left pillar of hiatus was well formed but right pillar was tenuous, displaced laterally. Stomach and omentum were brought into abdomen and

Case Report

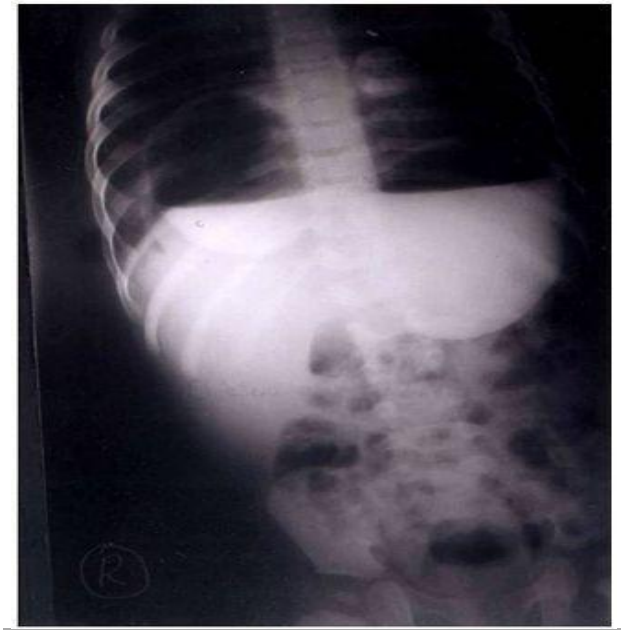

Figure 1: Chest radiograph showing the two air fluid levels –one in the retrocardiac mediastinum and another in the left hemidiaphragm

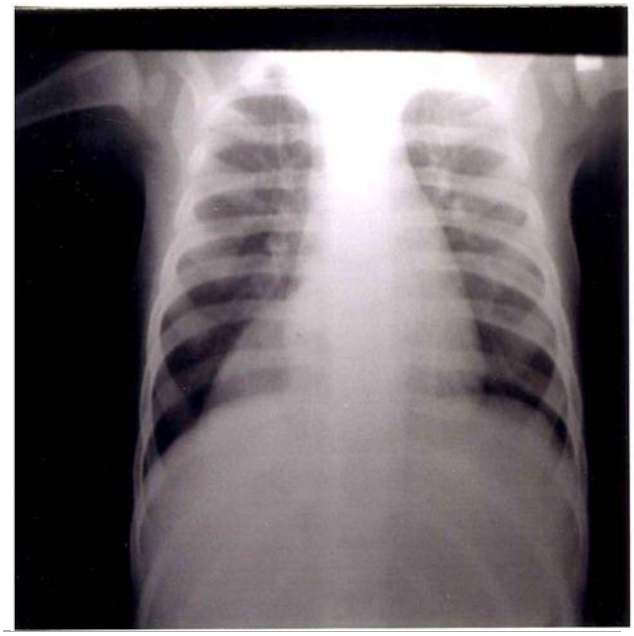

Figure 2: Chest radiograph showing a homogeneous opacity in the retrocardiac mediastinum and abscence of fluid level in left hemidiaphragm

Figure 3: Barium meal examination showing herniation of the stomach in left thoracic cavity with organoaxial torsion and the greater curvature abutting the the lateral thoracic wall

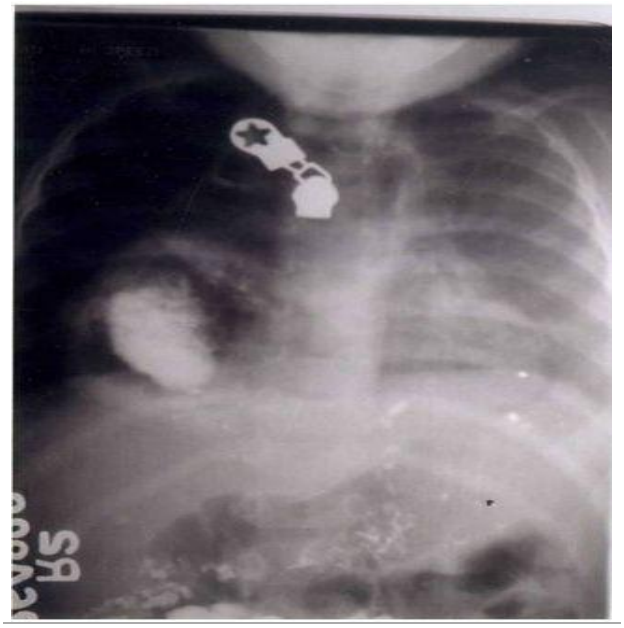

Figure 4: Barium meal examination the second patient showing herniation of the stomach in left thoracic cavity with organoaxial torsion and the greater curvature abutting the the lateral thoracic wall

the hiatus was narrowed by interrupted sutures posterior to esophagus. A Thal type of fundoplication along with anterior gastropexy was done. The postoperative period was uneventful and the child discharged after 7 days.

Case2

5 year male child admitted with nonbilious vomiting after meals and off and on alongwith pain upper abdomen for last one month. Patient was investigated and the barium meal examination revealed herniation of stomach in the right thoracic cavity. Patient was operated and the operative findings included the stomach and a part of colon lying in the right thoracic cavity and there was a hrnial sac. The herniated contents were reduced and the defect was repaired and a Thal type of fundoplication along with anterior gastropexy was done. The postoperative period was uneventful.

DISCUSSION

A right intrathoracic stomach is a rare form of congenital hiatal hernia seen in children and it carries good prognosis unlike other congenital diaphragmatic defects which can be life threatening immediately at or soon after birth (Allen, 1993). The children of this condition are discovered later in childhood because of the absence of a mass effect or mediastinal shift, the absence of pulmonary hypoplasia and the absscence of signs of incarceration or strangulation of the herniated stomach. The commonest symptom of this condition is repeated vomiting which occur as a consequence of either because of gastroesophageal reflux through a functionally incompetent gastroesophageal junction or because of crowding of the hiatal ring when the omentum and transverse colon compressing the distal antrum against the edge of the hernia orifice occluding the gastric outlet (Gerson, 1976). The organoaxial torsion of the herniated stomach is commonly seen in this condition as also in the present case but the torsion is usually limited upto 180^0 hence there is little chance of impairement of the blood supply of the herniated stomach from incarceration or strangulation (Haddad, 1996).The initial diagnosis of the volvulus of the herniated stomach often results from a chest radiograph when two basic patterns may be seen (Scott, 1986). Early on there are two large air fluid levels, the one in the retrocardiac mediastinum representing the dilated, herniated distal stomach with partial obstruction of its outlet and the second beneath the left hemidiaphragm representing an air fluid level in the normally positioned fundus which may be partially obstructed at the inlet to the herniated portion. When rotation increases so that both the inlet and outlet of the rotated, herniated distal stomach become obstructed and the retrocardiac air fluid level is replaced by a homogenous soft tissue mass, the fluid filled antrum (Menuck, 1976). In the present report both the patterns of radiographs were seen in the first case (Figure1 &Figure 2).However it is important to have a barium study to confirm the diagnosis of the volvulus. Once a diagnosis of hiatal hernia with gastric volvulus is confirmed, the patient should be operated as early as possible to avoid the strangulation of the herniated and rotated stomach. The surgical procedure consist of reduction of all herniated contents, narrowing of the diaphragmatic crura, partial or complete excision of the hernia sac and an antireflux procedure. Some authors also recommend an anterior gastropexy to lessen the possibility of reccurence (Scott, 1986).

REFERENCES

Allen MS, Trastek VF, Deschamps C and Pairolero PC (1993). Intrathoracic stomach: presentation and results of operation. *Journal Thoracic & Cardiovascular Surgery* **105**(1) 253 –259.

Gerson DE and Lewicki AM (1976). Intrathoracic stomach: when does it obstruct? *Radiology* **119**(1) 257 –264.

Haddad MC, Youssef BA, Sammak BM and Duff A (1996). Right intrathoracic stomach secondary to congenital hiatal hernia and organoaxial torsion. *American Juornal of Radiology* **167**(1) 66-68.

Menuck L (1976). Plain film findings of gastric volvulus herniating into chest. *American Journal of Radiology* **126**(3)1169-1174.

Naunheim KS and Creswell LL(2000). Paraesophageal hiatal hernia In: *General thoracic surgery* vol13rd edn edited by Shields TW, LoCicero J III, Ponn RB, eds*ry*. Philadelphia: Lippincott Williams & Wilkins 651–659.

Scott RL, Felker R, Winer-Muram H and Pinstein ML (1986). The differential retrocardiac air-fluid level: a sign of intrathoracic gastric volvulus. *Canadian Association Radiology Journal* **37**(1)119 –121.