

Case Report

CONCOMITANT TUBERCULAR ENTEROCUTANEOUS AND ENTEROVESICAL FISTULA: RARE PRESENTATION OF A COMMON DISEASE

***Mudit Agarwal, Surender Kumar, Mudit Melhotra, Saurabh Singh and Ravindra Bind**

Department of General Surgery, KGMU, Lucknow

**Author for Correspondence*

ABSTRACT

Tubercular enterocutaneous fistula is very rare complication of tubercular enteritis. Spontaneous tubercular enterovesical fistula is rare now a day. Keeping in mind the extreme incidence of tuberculosis in the Indian subcontinent, we report a case of concomitant enterocutaneous and enterovesical fistula in a female patient who was a defaulter for antitubercular treatment. Patient was managed in three phases. Intraoperatively, the ileocaecal portion was found to be clumped and the site of fistula was seen to be jejunum. About one foot distal to enterocutaneous fistula, enteovesical fistula was present. Resection and anastomosis of jejunum containing fistulae was done along with right hemicolectomy and ileotransverse anastomosis. Posterior wall of urinary bladder was primarily repaired. ATT was continued postoperatively.

Keywords: *Concomitant, Enterocutaneous Fistula, Enterovesical Fistula, Tubercular*

INTRODUCTION

Intestinal tuberculosis is the sixth most frequent form of extra-pulmonary tuberculosis. Although, primary abdominal TB is considered a common condition, spontaneous enterocutaneous fistula in such cases is rare. Spontaneous tubercular enterovesical fistula is still rarer.

CASES

A 20-year-old asthenic built female presented to us with a history of discharge of faecal matter through an opening in the left part of her abdomen for the past one month. This was associated with pneumourea and faecalourea. Initially, she had developed a swelling in the skin of left lumbar region. The swelling had ruptured after 7-8 days, to discharge pus followed by faecal matter.

This swelling followed by rupture was associated with evening rise of temperature along with episodes of high grade fever with chills. Her appetite was poor. She was passing flatus and faeces but had burning micturation along with episodic faecalourea and pneumourea.

On examination, the patient was poorly nourished and anaemic. There were no features of hypoproteinemia, dehydration, or electrolyte disturbances. Two fistulous opening of size 3.0 cm × 1.5 cm and 1.0 cm × 1.0 cm with faecal soiling was seen in left lumbar region [Figure 1]. No mass could be palpated in the abdomen. Examination of her respiratory and cardiovascular systems was normal. fooley's catheter was placed which showed pyurea. The patient had no history of any surgery or hospitalization. There was a previous history suggestive of kochs abdomen for which antitubercular treatment was started but was stopped after two months.

X-rays of the chest and abdomen were taken, both of which didn't reveal any abnormality. Abdominal sonography revealed bowel-wall thickening and enlarged mesenteric lymph nodes. A percutaneous fistulogram was obtained, which revealed a narrowing involving the ileocaecal junction and the terminal ileum, and a fistulous tract connecting the jejunum to the opening in the skin in the left lumbar region. Colonoscopy was performed and showed a normal colon. cystoscopy showed a small opening in posterior wall of urinary bladder.

Contrast enhanced CT scan showed mesenteric thickening with thickened terminal ileum with mesenteric lymphadenopathy along with enterocutaneous fistula with urinary bladder wall thickening and enterovesical fistula. Hb was 8gm%.

Case Report

Five-drug antitubercular therapy was started. Colostomy bag was applied over the fistulous opening. Two units blood was transfused. Nutritional status of patient was improved. At 6 weeks, the fistula did not show any signs of healing. Although it was a low-output fistula (with an output of about 150 ml/day), in view of the long history and the fact that the edges of fistula had completely epithelized, exploration was planned after complete bowel preparation. Albumin was transfused preoperatively.

Intraoperatively, the ileocaecal portion was found to be clumped and the site of fistula was seen to be jejunum. About one foot distal to enterocutaneous fistula, enteovesical fistula was present. The terminal ileum was dilated and its walls and the mesentery were thickened. Resection and anastomosis of jejunum containing fistulae was done along with right hemicolectomy and ileotransverse anastomosis. Posterior wall of urinary bladder was primarily repaired.

Histopathologically, the fistulous tract showed transmural dense chronic inflammatory cellular infiltration and histiocytic proliferation with Langhans-type giant cell reaction. Histological examination of the resected specimens revealed granulomas consisting of epithelioid cells, Langhan's giant cells, lymphocytes, mononuclear cells and central area of caseous necrosis in the ileocecal portion and mesenteric lymph nodes, which is typical of tuberculous involvement. TB of the lungs or of any other organ was not demonstrated. The patient's postoperative course was uneventful and five- drug antitubercular therapy was continued for a further 11 months. Follow-up was uneventful.

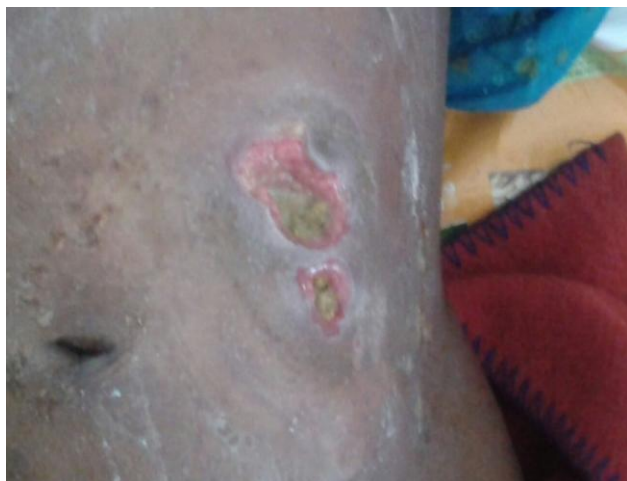

Figure 1: Enterocutaneous fistula

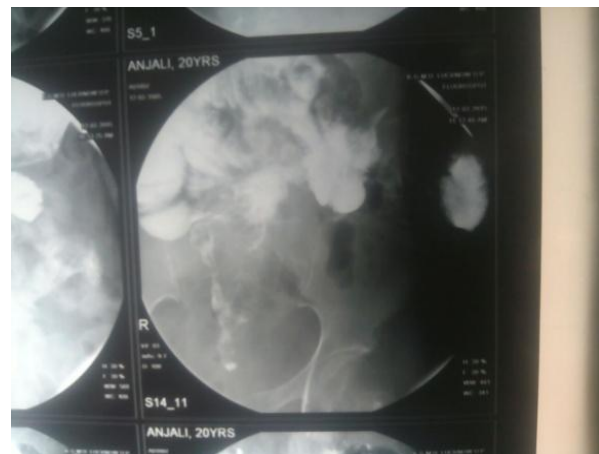


Figure 2: BMFT showing enterocutaneous fistula

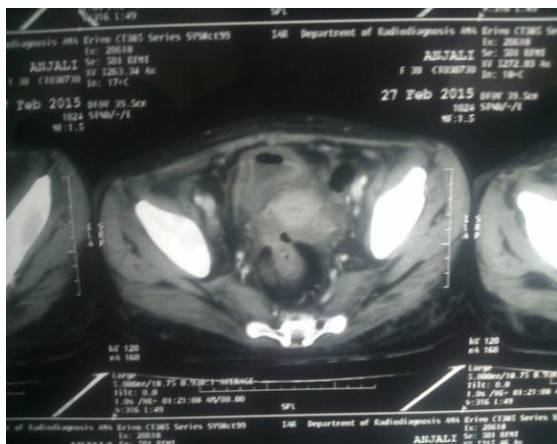

Figure 3: Urinary bladder wall thickening with air; enterovesical fistula

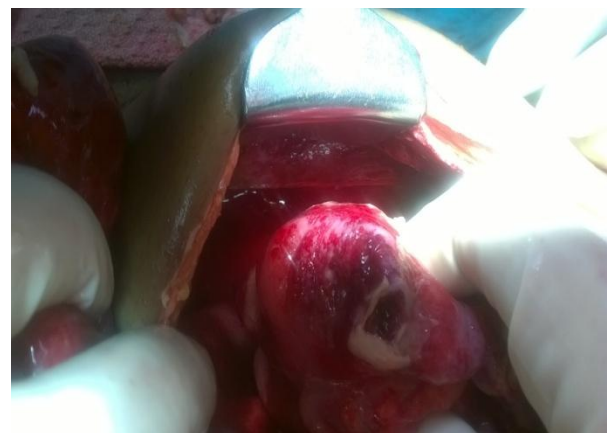

Figure 4: Jejunal fistula resected from urinary bladder

Case Report

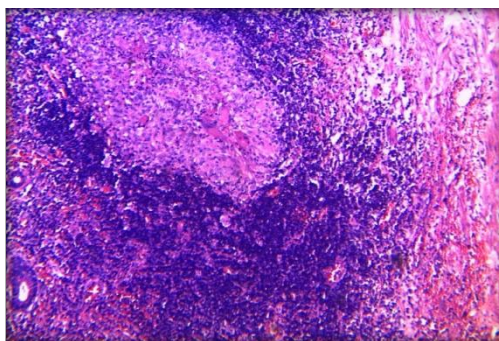


Figure 5: Section showing well formed epithelioid granuloma

DISCUSSION

Tuberculosis is still very common in developing and under developed countries (Alper *et al.*, 1988). Each year, 3 million people die of this disease worldwide. Tuberculosis can affect any tissue and organ in the body. Tuberculosis occurs in extra-pulmonary sites in 10-15% of non-HIV patient and up to 70% of those infected with HIV. Intestinal tuberculosis is the sixth most frequent form of extra-pulmonary tuberculosis. Only 15-20% of patients with intestinal tuberculosis have concomitant active pulmonary tuberculosis. The ileo-caecal region is the most common site of intestinal tuberculosis, possibly because of the increased physiological stasis, increased rate of fluid and electrolyte absorption, minimal digestive activity, and abundance of lymphoid tissue at this site (Paustian *et al.*, 1959). The modes of the secondary form infection are haematogenous, retrograde lymphatic spreading, secondary involvement from neighboring tuberculosis, and by ingestion of infected sputum. The mode of the primary form infection is considered ingestion of contaminated foods.

The various complications of intestinal TB include bowel obstruction (31.7%), intestinal perforation (4.9%), enterocutaneous fistula formation (2.4%), and small bowel volvulus due to mesenteric lymphadenitis (2.4%) (Alper *et al.*, 1988). Obstruction is a well known common complication of tuberculous enteritis. Perforation is an uncommon complication, and tubercular enterocutaneous fistula is very rare (Ceccherini *et al.*, 1989). Spontaneous tubercular enterocutaneous fistulae, in the strict sense, are not spontaneous, as their development is secondary to underlying intestinal diseases.

The common causes of acquired enterovesical fistulae have shifted from diseases of the past (eg, typhoid, amebiasis, syphilis, tuberculosis) to diverticulitis, malignancy, Crohn disease, and iatrogenic causes. Spontaneous tubercular enterovesical fistula is rare now a days.

Fistula formation is believed to evolve from a localized perforation that has an adherent adjacent viscous. The pathologic process is almost always intestinal. Pathologic processes characteristic of particular intestinal segments cause those segments to adhere to the bladder. Therefore, the location of the segment can suggest intestinal pathology. The segments most commonly in proximity to the bladder include the rectum, sigmoid colon, ileum, jejunum, and appendix. Preoperative diagnosis of underlying pathology as abdominal TB is often difficult (Bhansali, 1977) for several reasons. The absence of radiological evidence of pulmonary TB results in a low index of suspicion. Also, the condition may clinically mimic other diseases such as Crohn disease, neoplasm, and appendicular mass (Walker-Smith, 1988). Accurate diagnosis of the fistula can be made by doing a fistulogram, using water-soluble iodinated media. Combination with barium studies can accurately establish the site of the fistula in case of difficulty. CECT can show the actual tract of the fistula and also locate any associated pathology (Chintamani *et al.*, 2003). Enterocutaneous fistulae are classified into four types based on the modified Sitzes-Serra classification (Sitzes-Serra, 1989) proposed by Schein and Decker (1991). Type I fistula are esophageal, gastric, and duodenal fistulae, type II fistula involve small bowel; type III fistula involve large bowel and type IV fistula where all the afore mentioned drains through a large abdominal wall defect.

Based on the output, the fistulas are classified as high and low output fistula. Fistulae producing less than 500 cc output per day are classified as low output fistulae while those with >500 ml/ day are classified as

Case Report

high output fistulae and this has a bearing on the management. High output fistulas usually require surgical intervention while low output fistulae in well-preserved individuals may be managed conservatively (Chamberlain *et al.*, 1998).

Management of fistulas is divided into three phases: *Phase I* involves the correction of fluid and electrolyte imbalances. Meticulous skin care is provided around the fistula using skin protective creams. Ileostomy bag is placed on the opening. The associated intra-abdominal abscesses are drained and appropriate antibiotics started.

Phase II consists of accurate diagnosis of the origin of fistula and begins simultaneously with phase I. *The phase III* consists of surgical correction. Resection of the matted diseased bowel with anastomosis of healthy segments is considered a best option. In critically ill patients, exteriorization of both ends (as ostomy and mucus fistula) is considered worthwhile, in order to have the patient for definitive repair when he is clinically stable. Simple fistulectomy and closure of the intestinal end of fistula may lead to leak or recurrence of fistula (Ara *et al.*, 2005)

REFERENCES

- Alper Akino Glu and Ilter Bilgin (1988).** Tuberculous Enteritis and Peritonitis. *Canadian Journal of Surgery* **31** 55–8 [PubMed].
- Ara C, Sogutlu G, Yildiz R, Kocak O, Isik B and Yilmaz S et al., (2005).** Spontaneous small bowel perforations due to intestinal tuberculosis should not be repaired by simple closure. *Journal of Gastrointestinal Surgery* **9** 514–7 [PubMed].
- Bhansali SU (1977).** Abdominal tuberculosis: Experience with 300 cases. *American Journal of Gastroenterology* **67** 324–7 [PubMed].
- Ceccherini E, Sereni P, Felicioni L, Testi W and Mancini S (1989).** Tubercular enteric fistulas. *Minerva Chirurgica* **44** 1293–5 [PubMed].
- Chamberlain RS, Kaufman HL and Danforth DN (1998).** Enterocutaneous fistula in cancer patients: Etiology, management, outcome, and impact on further treatment. *American Journal of Surgery* **64** 1204–11 [PubMed].
- Chintamani, Badran R, Rk D, Singhal V and Bhatnagar D (2003).** Spontaneous enterocutaneous Fistula 27-years Following Radiotherapy in a Patient of Carcinoma Penis. *World Journal of Surgical Oncology* **1** 23 [PubMed].
- Paustian FF and Bockus HL (1959).** So-called primary ulcerohypertrophic ileocecal tuberculosis. *American Journal of Medicine* **27** 509–18 [PubMed].
- Schein M and Decker GAG (1991).** Postoperative external alimentary tract fistulas. *American Journal of Surgery* **161** 435–438 [PubMed].
- Sitges-Serra A, Jaurrieta E and Sitges-Creus (1989).** A: Management of postoperative enterocutaneous fistulas: The role of parenteral nutrition and surgery. *British Journal of Surgery* **69** 147–150.
- Walker-Smith J (1988).** Disease of the Small Intestine in Childhood. London: Butterworths. *Abdominal Tuberculosis* 354–60.