

**Research Article**

## **PROXIMAL FISTULA- CAN IT BE AN ALTERNATIVE FOR URINARY DIVERSION IN STAGED REPAIR OF HYPOSPADIAS?**

**\*Yogender S. Kadian<sup>1</sup>, Kajal P.<sup>2</sup> and Rattan K. N.<sup>2</sup>**

<sup>1</sup>8-UH, Medical Campus, PGIMS, Rohtak, Haryana, India -124001

<sup>2</sup>Department of Paediatric Surgery, Pt. B.D. Sharma PGIMS, Rohtak, India

*\*Author for Correspondence*

### **ABSTRACT**

The diversion of urinary stream away from the newly created neourethra is fundamental to achieve good results in staged repair of severe hypospadias. However, in literature there is no consensus regarding the method or duration of urinary diversion. In this study the authors want to present the idea of leaving a fistulous opening as a new way of urinary diversion method in select group of hypospadias patients. We have managed 13 patients of chordee with hypospadias by staged repair. In stage-I, chordee correction was done by dividing the urethral plate and covering the penile shaft with dorsal prepuce flaps. In stage-II, a neourethra was created extending from glans upto the level of external meatus and the meatus was left as such for urinary diversion to avoid contact with the neourethra. This fistulous opening was closed after six months making the procedure a three stage affair. Eleven patients (84.6%) had successful functional and cosmetic repair. One patient had urinary leak from the site of fistulous opening but stopped after three months of follow up without any surgical intervention. In one patient, the external urinary meatus could be made upto coronal level. In staged repair of chordee with hypospadias the proximal fistulous opening is a good option of urinary diversion in select group of patients. It allows the neourethra to heal completely and it can be calibrated in the follow up and closed subsequently to make a near normal urinary passage. But this option should be utilized in severe variety of hypospadias because then it becomes a three stage procedure.

**Keywords:** *Hypospadias Repair, Chordee Correction, Fistula & Neourethra*

### **INTRODUCTION**

The staged repair of hypospadias is a well described procedure for selected group of patients of hypospadias (Arshad, 2005; Baskin and Ebberts, 2006). The stage I procedure involves the chordee correction and in second stage the neourethra is created from the ventral shaft skin and is rolled into a tube. This neourethra is susceptible for various complications like fistula formation, complete breakdown, stricture or diverticulum formation. The reasons for poor outcome may be improper selection of case or procedure for the patient, poor vascularity of the tissues, improper urinary diversion method or non-usage of intermediate layer. As a result, patients had to undergo multiple procedures for the repair ranging from 2-23 (mean 4) in an index patient (Amukele *et al.*, 2005). To prevent such a disaster outcome, one need an out of box approach for managing these select group of patients. If urinary flow is diverted from the newly created neourethra and allow it to heal completely and then create normal urinary passage. The various methods of urinary diversion included, suprapubic catheter, perurethral catheter, transurethral drainage or perineal urethrostomy. However, to achieve urinary diversion for six months one has to choose a procedure where patient can pass urine without any appliance. In the present study of 13 patients the author has managed the severe hypospadias cases by staged repair and a proximal fistula was left a method of urinary diversion while creating the neourethra in the second stage. Afterwards this fistula was closed after six months making the complete repair a three stage approach.

### **MATERIALS AND METHODS**

A total of 13 patients of proximal hypospadias (proximal penile & penoscrotal) with severe chordee were managed by staged repair. Age of the patients ranged from 3 to 16 (mean 6.4) years. Associated anomalies were in 3 patients, 2/13 had unilateral undescended testis and 1/13 had renal agenesis on right

## Research Article

side. There was history of previous attempt of repair in 2 patients but chordee was still there. The time interval between first and stage was a minimum of one year and a minimum of six months for closure of fistula created for urinary diversion.

**Surgical Technique:** A circumferential incision was given just proximal to coronal region and urethral plate was divided. The penile shaft was degloved and the urethral plate was excised upto the level of external meatus and a few fiery cuts were applied over the ventral aspect of the corpora. The shaft was straightened and was assessed by the Gittes test. Then the dorsal prepuce was divided into two equal halves (Byars flaps) and rotated ventrally to cover the ventral shaft. An indwelling catheter was kept for 5 days and then patient discharged home.

**In the Second Stage:** The ventral shaft skin was marked and then rolled into a tube (Thiersch –Duplay) to create the neourethra extending distally from glans and proximally just short of external meatus and the meatus was left as such for urinary diversion. The neourethra was stented and a separate catheter was kept via the external meatus to drain the urine (Figure 1). The catheter was removed on 7<sup>th</sup> day and the patient was discharged with stent in situ (Figure 2) and it was removed after 2- 3 weeks and this neourethra was calibrated in the outpatient. Then the fisula which was left for urinary diversion was closed after six months. This closure was augmented by a pedicelled tunica vaginalis flap or scrotal dartos.

## RESULTS AND DISCUSSION

### Results

The follow up of patients range from 6 months to 3 years. In eleven patients there satisfactory outcome and in one there was a minor leak from the site of fistula closure but it closed on its own after 3 months of surgery. In another patient the external urinary meatus could be only upto level of corona.

### Discussion

The management of hypospadias involves wide spectrum of opinion in literature and there are more than 300 described procedures for the repair of this condition. Moreover, the evidence based long term outcomes of hypospadias surgery are lacking and there are mixed results of various series (Retik *et al.*, 1994 & Castagnetti *et al.*, 2010). So, it is difficult to standardize the procedure in an individual patient but the primary goal is to have a adequately straightened penile shaft and external meat us at glanular level. However, it is difficult to achieve good results in all cases and in some severe hypospadias variety one has to lower the standard for satisfactory outcome. In these selected group of patients the outcome of staged procedure is better as compared to single stage. The staged repair is essentially a two stage procedure consisting of straightening of penile shaft in stage I and creation of neourethra in 2<sup>nd</sup> stage. But because of complications all patients cannot be repaired in two stages and it can extend to multiple operations even as high as 23 in an index patient making these patients as hypospadias cripples (Amukele *et al.*, 2005). Failed attempts at hypospadias repair often leave the patient with a penis that is scarred, hypovascular and shortened. The reported complications of repair are fistula (single/multiple), complete breakdown of repair, stricture or diverticulum formation (Greenfield *et al.*, 1993). It is difficult to pinpoint any single reason for disastrous outcome in some patients and there are no guiding principles in management of hypospadias.

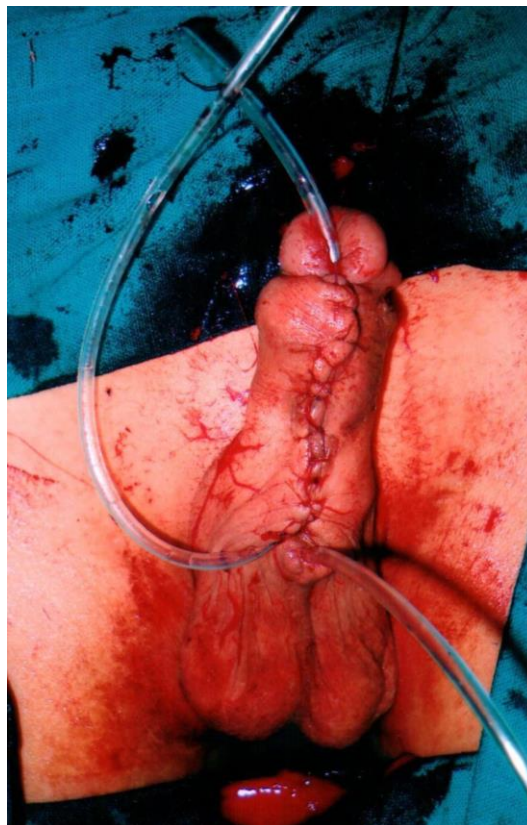Can the diversion of urine away from neourethra till its healing, prevent these complications? As per standard text book of pathology the primary wound healing passes through the stages of inflammation, tissue formation and tissue remodelling. The maximum tensile strength of a wound is achieved in 3-6 months and if urinary diversion is done for a period of six months can this be way for preventing the complications (Mitchell, 2010). Taking this concept into consideration the authors have managed the select group of hypospadias patients in the present study.

The goal of urinary diversion is to prevent urethral oedema from obstructing urine flow and to allow the neourethra to heal completely before contact with urine. The various methods of diversion are intraurethral catheter, perurethral drainage by fenestrated stent, suprapubic device or perineal urethrostomy. In a questionnaire based study regarding urinary diversion methods there were following inferences; diversion not necessary for mild type of hypospadias, intraurethral drainage is preferred for

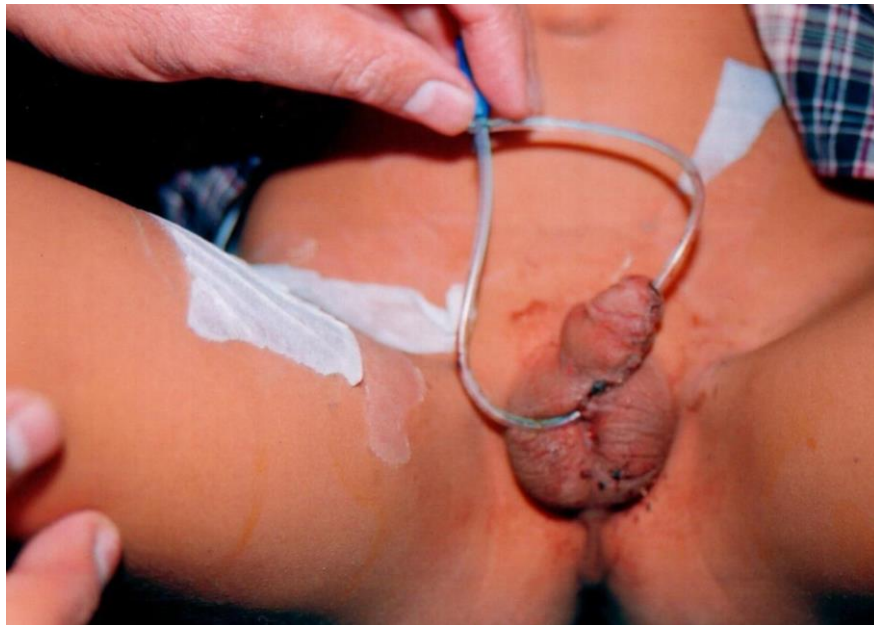### Research Article

moderate variety, suprapubic drainage with an intraurethral stent for severe variety and perineal urethrostomy is used rarely (Osterling *et al.*, 1987). The duration of diversion is usually for a week or two. In the present study the urinary diversion was done by leaving a proximal fistulous opening at the time of creation of the neourethra and patients were passing urine from the same opening as before creating the neourethra and without any appliance. This fistulous opening was closed subsequently after six months thus, making the staged repair into a three stage affair rather than conventional two stage. This diversion prevented urinary contact with the neourethra till its complete healing and achievement of tensile strength of the wound so there is minimal chances of complications. But there is possibility of scarring of the neourethra if it is left dry but it has not happened in the present series. This may be because of regular calibration of the neourethra in the outpatient and it can be done from either the proximal or distal opening of the neourethra (Figure 3). Also in literature in a study Cheng *et al.*, (2003) managed 8 hypospadias cases by staged repair and neourethra created in the 1st stage was left as such without communicating with the urinary stream and in the next stage the neourethra sounded to at least 10 Fr catheter without any evidence of stenosis or scarring despite it being kept dry for six months (Cheng *et al.*, 2003). But there is always a need for stent for the neourethra for the fear of meatal stenosis as being reported in non stented group patients (Radwan *et al.*, 2012). In the present study also the authors have also put stent in the neourethra for 2-3 weeks.

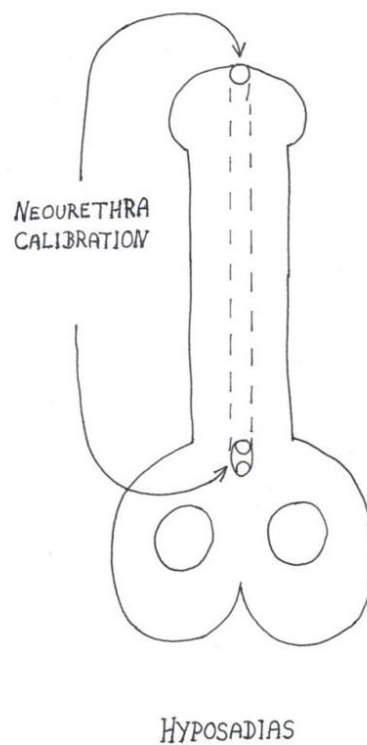
To summarize, the authors are of the opinion that in the management of hypospadias it is difficult to follow the tailor made approach in select group of patients and one have to find an out of box solution to make a satisfactory outcome. The present approach for management of this condition is just like when one need to overcome a disaster, one need a safest way and the creation of fistula is like a safety valve for prevention of poor outcome in a difficult repair.



**Figure 1: The Clinical Photograph Showing the Created Neourethra with a Proximal Opening and Catheter as well as Stent in Place**



**Figure 2: The Clinical Photograph with a Stent in Place**



**Figure 3: Diagrammatic View Showing the Proximal and Distal Openings of Neourethra for Calibration**

## Research Article

### REFERENCES

- Amukele SA, Stock JA and Hanna MK (2005).** Management and outcome of complex hypospadias repairs. *Journal of Urology* **174** 1540-43.
- Arshad AR (2005).** Hypospadias repair: Byar's two stage operation revisited. *British Journal of Plastic Surgery* **58** 481-86.
- Baskin LS and Ebberts MB (2006).** Hypospadias: anatomy, etiology and technique. *Journal of Pediatric Surgery* **41** 463-72.
- Castagnetti M and El-Ghoneimi A (2010).** Surgical management of primary severe hypospadias in children: *Systematic 20 Years Review* **184** 1469-75.
- Cheng EY, Kropp BP, Pope JC IV and Brock JW III (2003).** Proximal division of urethral plate in staged hypospadias repair. *Journal of Urology* **170** 1580-4.
- Greenfield SP, Sadler BT and Wan J (1993).** Two stage repair of for severe hypospadias. *Journal of Urology* **152** 498-501.
- Mitchell RN (2010).** Tissue renewal, repair and regeneration. In: Kumar V, Abbas AK, Fausto N, Aster JC editors, *Robbins and Cotran Pathologic Basis of Disease* 8th edition (Pennsylvania, Philadelphia, Saunders) 79-110.
- Osterling JE, Gearhart JP and Jeffs RD (1987).** Urinary diversion in hypospadias surgery. *Journal of Urology* **29** 513-16.
- Radwan M, Soliman MG, Tanfik A, Abo-Elenen M and El-Benday M (2012).** Does the type of urinary diversion affect the result distal hypospadias repair? A prospective randomized trial. *Therapeutic Advances in Urology* **4** 161-5.
- Retik AB, Baur SB, Mandell J, Peters CA, Colodry A and Atala A (1994).** Management of severe hypospadias with a 2-stage repair. *Journal of Urology* **152** 749-52.