

Case Report

TRAUMATIC CHEMICAL ORAL ULCERATION – ASPIRIN BURN – A CASE REPORT FROM LIBYA

*Karthikeyan Ramalingam¹ and Khaled Awidat Abdalla²

¹Department of Oral and Maxillofacial Pathology,

²Department of Orthodontics, Sebha University, Sebha, Libya

*Author for Correspondence

ABSTRACT

Injuries to oral soft tissues could be caused by chemical, thermal and physical agents. This case report illustrates the destructive effect of medication, if used indiscriminately. A 30-year-old female of Libyan origin complained of severe pain and burning sensation in the lower left region of the jaw. History revealed the topical application of crushed aspirin tablet on the inner cheek to relieve the pain. Intra oral examination revealed a chemical burn in the left buccal vestibule in the molar region. Correlating the history, it was diagnosed as a traumatic chemical oral ulceration – aspirin burn. The patient was advised symptomatic management and educated to prevent these local behaviour.

Keywords: Aspirin Burn, Chemical Burn, Oral Ulcer, Traumatic

INTRODUCTION

Oral ulcers could be caused by accidental, iatrogenic and factitious trauma (Armitage, 1999). Although the prevalence is relatively high of such traumatic lesions in the oral cavity, there are limited reports on the diagnosis of such injuries. Chemical injuries may be caused by a variety of chemical substances like drugs that come into contact with the oral mucosa (Rawal *et al.*, 2004). The severity and extent of such lesions depend on the concentration, type and quantity of the substance and the exposure time or contact time with the oral soft tissues (Mamede and de Mello Filho, 2001).

There are very few reports about chemical burns in the oral cavity listed in PUBMED (Holmes *et al.*, 2004; Dellinger and Livingston, 1998).

The purpose of this case report is to illustrate the destructive nature of topical application of routine drugs used for pain relief can end up as a severe chemical burn.

CASES

A 30-year-old female of Libyan origin reported to the Faculty of Dentistry, Sebha University, Sebha, Libya with a complaint of severe pain and burning sensation in the left side of lower jaw. She had difficulty in eating.

Her medical history was non-contributory without any drug or food allergies. Her past dental history revealed that she had a carious tooth in the lower left jaw which had been troubling her since the past few weeks.

She suddenly developed severe pain the earlier night and unable to bear the pain, she crushed an aspirin tablet and applied it over the offending tooth and adjacent soft tissue. Though there was relief for a short period, she ended up with severe burning sensation in the soft tissues.

Intra oral examination revealed an extensive, whitish ulcer with surrounding erythema involving the left buccal vestibule and retromolar region (Figure 1).

The lesion was slightly redder in some areas, normal in consistence and slightly tender on palpation (Figure 2). The lower left second molar was carious and tender on palpation. There was no extra-oral swelling but left submandibular lymph nodes were palpable.

Correlating with the history and clinical findings, the patient was diagnosed as Traumatic chemical oral ulceration – Aspirin burn. The patient was advised symptomatic treatment with topical anaesthetic spray for pain relief, systemic analgesics (Paracetamol 650mg thrice a day), saline mouth wash twice a day along with a bland diet. The healing was uneventful and the patient is under regular follow-up.

Case Report

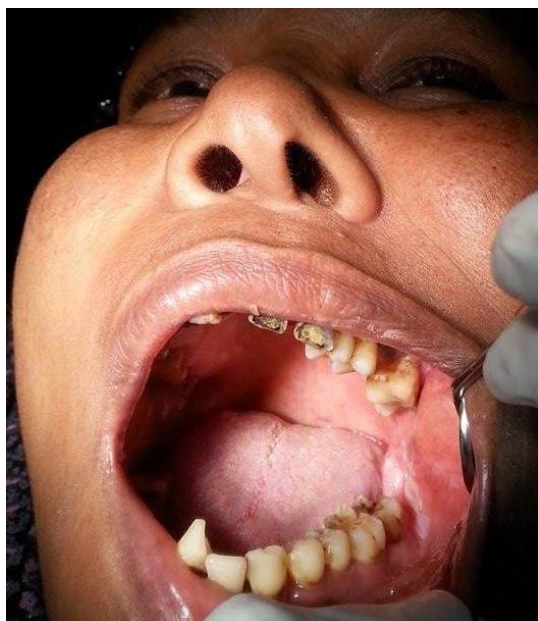


Figure 1

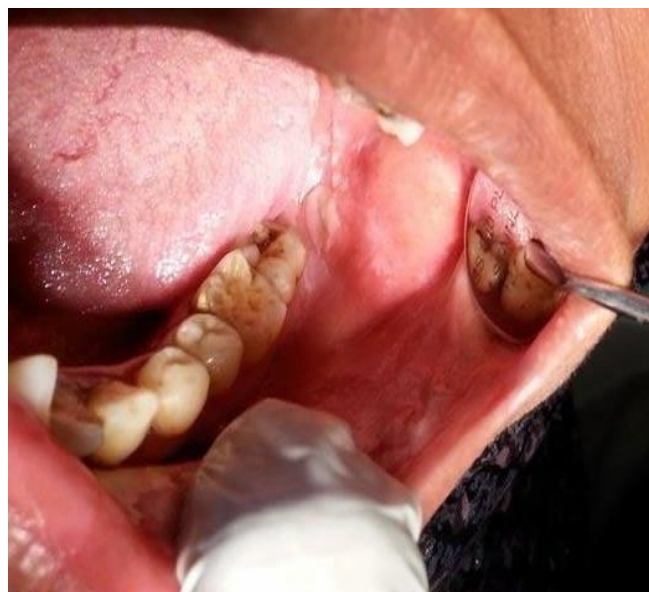

Figure 2

DISCUSSION

Lesions produced vary according to the destructive properties and mode of application of the chemical agent. Most commonly these burns are attributed to careless handling of various dental medications like Hydrogen peroxide, Sodium hypochlorite, Calcium hydroxide and Formocresol solution. The white slough is formed due to necrosis of the epithelium (Rawal *et al.*, 2004).

Excessive usage of other therapeutic agents implicated for oral mucosal injuries include listerine and chlorhexidine based mouthwashes containing alcohols, additives and preservatives, denture cleanser tablets, fresh fruits and their juices, cocaine and other drug abuse (Gilvetti *et al.*, 2010).

Self-inflicted therapeutic error due to patient's improper application of medications like aspirin is quite common when the tablet is placed next to aching tooth as an attempt to alleviate dental pain (Dellinger and Livingston, 1998). The lower pH (3.5 – 5.0) seems to be the origin of the mucosal damage. The organic and inorganic acids bind with the epithelial and tissue proteins causing denaturation and coagulative necrosis (Gilvetti *et al.*, 2010). Our case presentation correlated with reported literature about aspirin burns.

Regardless of the cause, the treatment of chemical trauma primarily involves the identification and removal of the toxic agent that caused the burn. Most chemical burns with mild to moderate tissue damage heals spontaneously within 7 to 15 days without any scarring.

Only palliative and symptomatic treatment with gentle plaque control, topical anaesthetic rinse and systemic analgesics, if needed. Local debridement, systemic antibiotics and topical corticosteroids like triamcinolone in orabase is indicated when there is severe tissue damage (Gilvetti *et al.*, 2010). Our patient was advised symptomatic and palliative treatment and she responded favourably without any complications.

Conclusion

Our case report illustrates the damaging effect of aspirin when placed directly on oral mucosa. Prompt treatment can avoid significant patient morbidity. We advise general guidance and patient education as a prophylactic tool to prevent such deleterious actions.

ACKNOWLEDGEMENT

We would like to thank Dr. Fatma and Dr. Hanadi for their assistance in clinical photography.

Case Report

REFERENCES

Armitage GC (1999). Development of a classification system for periodontal diseases and conditions. *Annals of Periodontology* **4** 1-6.

Dellinger TM and Livingston HM (1998). Aspirin burn of the oral cavity. *Annals of Pharmacotherapy* **32**(10) 1107.

Gilvetti C, Porter SR and Fedele S (2010). Traumatic chemical oral ulceration: a case report and review of the literature. *British Dental Journal* **208**(7) 297-300.

Holmes RG, Chan DC and Singh BB (2004). Chemical burn of the buccal mucosa. *American Journal of Dentistry* **17**(3) 219-20.

Mamede RC and de Mello Filho FV (2001). Ingestion of caustic substances and its complications. *Sao Paulo Medical Journal* **119** 5-10.

Rawal SY, Claman LJ, Kalmar JR and Tatakis DN (2004). Traumatic lesions of the gingiva: a case series. *Journal of Periodontology* **75** 762-9.