

Case Report

A VERTEX APLASIA CUTIS REVEALED BY AN OVARIAN CARCINOMA METASTASIS: A CASE REPORT OF A 52 YEARS OLD LADY

*Assoumane I¹, Kadre A², Madjouj A³ and Bouzekar A⁴

¹Department of Neurosurgery, CHU Bab El Oued Algiers, Algeria

²Maxillo facial Surgery Department, Reference General Hospital Niamey (Niger)

³Private Practitioner Plastic Surgeon Algiers (Algeria)

⁴Etablissement hospitalier spécialisé Oran (Algérie)

*Author for Correspondance: as_ibrah2006@yahoo.fr

ABSTRACT

Aplasia cutis congenita (ACC) is an uncommon skin disorder characterized by the absence of some or all layers of the skin. The etiology is unknown, it can involve many part of the body. The treatment modalities are controversial even if the intervention is mandatory at the birth to avoid the main complications like hemorrhage and infections. The diagnosis is relatively easy at the birth; its revelation by a metastasis of an ovarian carcinoma is exceptional.

Here we report a case of vertex aplasia cutis revealed by a metastasis of an ovarian carcinoma on a 52 years old lady

Keywords: *Aplasia Cutis, Carcinoma, Ovarian, Scalp, Vertex*

INTRODUCTION

The aplasia cutis congenita (ACC) is a rare malformation described for the first time in 1767 by Cordon on the extremities and on the scalp by Campbell in 1826; in 1828 Billard reported the involvement of the bone and dura of the skull underlying the scalp defect (Yang and Yang, 2000). The etiology has not yet been defined; it can involve all part of human body with predominance of the scalp follow by forearms, knees, chest and neck (Yang and Yang, 2000). It can be isolated or in association with multiples lesions, sometimes the treatment is indicated at the birth to avoid hemorrhage or infection. Ovarian cancer represent 4% of all women cancers with about 200000 new cases every year diagnosed in the world, but only 30% of patients are diagnosed at an early stage, I or II of the international federation of gynecologists and obstetricians FIGO (Gajjar *et al.*, 2012). Here we report a case of aplasia cutis of the vertex revealed by a metastasis of an ovarian carcinoma on a 52 years old lady.

CASE

She is a 52 years old patient who consulted for a scalp lesion evolving for a few months. According to the patient she underwent a skin graft on the vertex in the infancy for a burn sequella. At the admission the clinical exam found a patient with good general status, there was an oval and reddish lesion located on the border of a grafted surface of the vertex. The skin graft was in the center of an important alopecia (Figure1)

The brain CT scan objectified a parietal lacunar images surrounded by a skull expansive process (figure 2).

The diagnosis of cutis aplasia is retained in front of alopecia, scalp defect, and lacunar images on the brain CT scan

The first biopsy done objectify a basocellular epithelioma; in one month time the tumor triple the volume and become hemorrhagic. The patient underwent in emergency hemostasis and the tumor reduction followed by a skin graft (Figure 3).

The histologic results concluded a metastasis of an ovarian carcinoma, so the patient was referred to chemotherapy and gynecology for further treatment.

Case Report

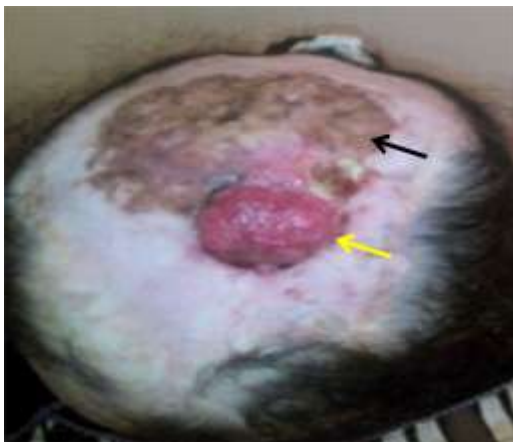

Figure 1: Pre operative image showing an oval lesion (yellow arrow) on the border of a grafted surface (black arrow) surrounded by an alopecia

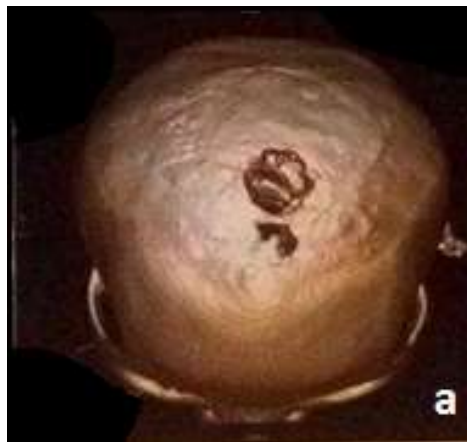

Figure 2: Brain CT scan: a: bone reconstruction showing lacunar images of the vertex

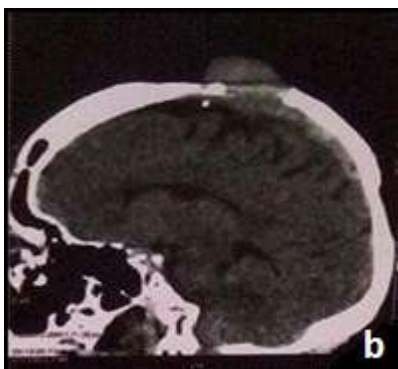


Figure 2: Brain CT scan: b: sagittale reconstruction showing an extra cranial process

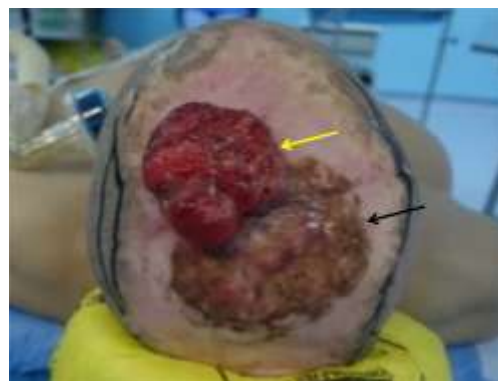

Figure 3: Pre operative image showing the tumor one month after the biopsy

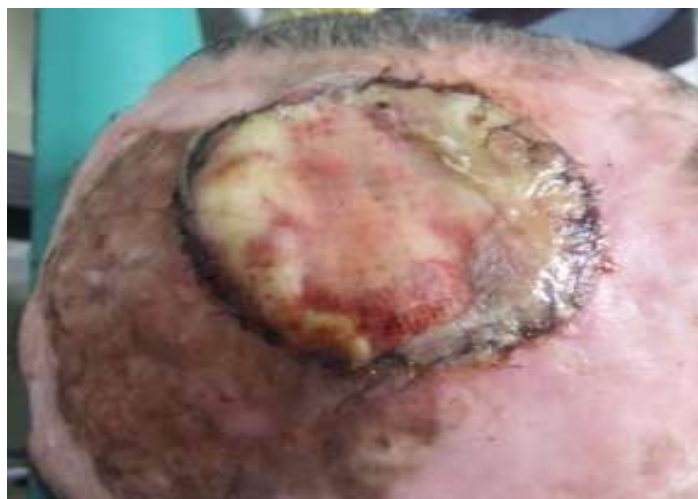

Figure 4: Post operative images after tumor reduction and skin graft

Case Report

DISCUSSION

Aplasia cutis congenita (ACC) is a rare malformation with unknown etiology, many hypothesis are raised but genetic etiology is preferred (Leboucq *et al.*, 1994); it can be associated with epidermolysis bullosa, specific teratogens or intra uterine infections, chromosomal abnormalities, ectodermal dysplasias (Mirjam *et al.*, 1995), or integrated in a syndrome like Adams-Oliver syndrome (Zapata *et al.*, 1995) constituted by ACC and limbs malformations. Eighty percent (80 %) of aplasia cutis occur over or near the vertex, usually in a roughly symmetrical pattern (Leboucq *et al.*, 1994), like the case of our patient. The main complications are hemorrhage and infections. The dura, if not kept constantly moist, will quickly become desiccated. A crack then commonly develops in the dry dura and spreads into the superior sagittal sinus or a major vein in the dura mater resulting in sudden massive bleeding (Dyall-Smith, 1994). The most reported infections are meningitis, sepsis and local infections (Ross *et al.*, 1995). Other reported complications are superior sagittal sinus thrombosis, cerebrospinal fluid (CSF); the dural defect can allow a parenchymal hernia follow by it necrosis (Dyall-Smith, 1994). The treatment modalities of scalp aplasia cutis congenita still controversial, many authors advise conservative treatment to avoid risks of surgery and anesthesia on new borns ;many surgical techniques are advocated like skin graft, rotated skin flap, ribs auto graft to reconstruct the bone defect (Sander *et al.*, 2007). A periosteal flap covered by skin graft is advocated by Moscona *et al.* (Moscona *et al.*, 1991) to create a viable site of bone regeneration. For Ken R Winston Early surgical management using scalp rotation flaps is, when surgically and anesthesiologically thought to be safe, the intervention of choice for most patients with composite type aplasia cutis congenita of the scalp. According to some authors primary bone graft of the cranial defect must be avoided because even large defects can ossify completely or left a small bone defect (Ken *et al.*, 2016). The diagnosis of the ACC is usually easy at the birth; the revelation at adulthood and the revelation by an ovarian carcinoma attest the lack of knowledge on that pathology.

CONCLUSION

The scalp aplasia cutis congenita is a rare malformation, the diagnosis is relatively easy but the treatment is difficult. The management of that exceptional association needs the close collaboration of neurosurgeons, plastic surgeons, gynecologists and oncologist.

Conflict of interest: none

REFERENCES

- Dyall-Smith D, Ramsden A and Laurie S (1994).** Adams-Oliver syndrome: aplasia cutis congenita, terminal transverse limb defects and cutis marmorata telangiectatica congenita. *Australasian Journal of Dermatology* **35** 19–22.
- Ken R Winston and Lawrence L Ketch (2016).** Aplasia Cutis Congenita of the Scalp, Composite Type: The Criticality and Inseparability of Neurosurgical and Plastic Surgical Management. *Pediatric Neurosurgery* **51** 111-120.
- Ketan Gajjar, Gemma Ogden, M. I. Mujahid and Khalil Razvi (2012).** Symptoms and Risk Factors of Ovarian Cancer: A Survey in Primary Care. *International Scholarly Research Network Obstetrics and Gynecology*, Article ID 754197, 6.
- Leboucq N, P Montoya y Martinez, F Montoya-Vigo and P Castan (1994).** Aplasia cutis congenita of the scalp with large underlying skull defect: a case report. *Neuroradiology* **36** 480-482
- Mirjam EJW Evers, Peter M Steijlen and Ben CJ Hamel (1995).** Aplasia cutis congenita and associated disorders: an update. *Clinical Genetics* **47** 295-301.
- Moscona R, Berger R and Govrin J (1991).** Large skull defect in aplasia cutis congenita treated by pericranial flap: longterm follow up. *Annales of Plastic Surgery*, **26** 178–182.
- Ross DA, Laurie SWS, Coombs CJ and Mutimer KL (1995).** Aplasia cutis congenita: failed conservative treatment. *Plastic Reconstructive Surgery* **95** 124–129.

Case Report

Sander JA Beekmans, J Peter W Don Griot and J. Wiebe Mulder (2007). Surgical Strategy Split Rib Cranioplasty for Aplasia Cutis Congenita and Traumatic Skull Defects: More Than 30 Years of Follow-Up. *The Journal of Craniofacial Surgery*, **18**(3).

Yang JY and Yang WG (2000). Large scalp and skull defect in aplasia cutis congenital. *British Journal of Plastic Surgery* 53.

Zapata HH, Sletten LJ and Pierpont MEM (1995). Congenital cardiac malformations in Adams-Oliver syndrome *Clinical Genetic* **47** 80-84.