

Research Article

HISTOPATHOLOGICAL EVALUATION OF THYMUS VULGARIS ON WOUND HEALING

Kazem Ghaem Panah¹, *Saeed Hesaraki¹ and Mohammad Reza Farahpour²

¹Department of Pathobiology, Science and Research branch, Islamic Azad University, Tehran, Iran.

²Department of Clinical Sciences, Urmia Branch, Islamic Azad University, Urmia, Iran

*Author for Correspondence

ABSTRACT

The main purpose of current study was to evaluate effect of *Thymus vulgaris* essential oil ointment in wound healing. Forty eight male Wistar rats were randomly divided into 3 experimental groups. Experimental wound was induced on the anterior-dorsal side of each rat. Group 1 served as control and received basal formulation ointment. Groups 2 and 3 received 1.5 and 3 % of *Thymus vulgaris* essential oil. Wound healing activity as a closure percentage was determined on days 4, 12 and 21 post-operation. The number of fibroblast and macrophages, collagen deposition and neovascularization were assessed on 3, 7, 14 and 21 days after wound incision. Wound area significantly decreased in *Thymus vulgaris* ointment treated groups compared to control group on days 4, 12 and 21 post operation, respectively ($P < 0.05$). Administering of *Thymus vulgaris* ointment, significantly ($P < 0.05$) increased fibroblast and macrophages distribution and up-regulated the new vessels formation and collagen deposition on days 3, 7, 14 and 21 after wound induction ($P < 0.05$). It is suggested that *Thymus vulgaris* ointment is useful for healing.

Keywords: *Thymus Vulgaris*, Wound, Healing, Rat

INTRODUCTION

14 species of *Thymus* L. genus are scattered in Iran (Arzani *et al.*, 2013). *Thymus vulgaris* is native in Mediterranean countries (Kozics *et al.*, 2013). Essential oil of *Thymus vulgaris* exerts antimicrobial properties (Bozin *et al.*, 2006). Monoterpenes, phenolic compounds, thymol, eugenol, p-cymene, γ -terpinene, linalool, geraniol and borneol can be extracted from *Thymus vulgaris* (El Bouzidi *et al.*, 2013). The *Thymus vulgaris* has antibacterial activity and protects cell against oxidants (Braga *et al.*, 2007; Kozics *et al.*, 2013). *Thymus vulgaris* is broadly used to treatment asthma, inflammation, hepatotoxicity and atherosclerosis (Stahl-Biskup and Sáez, 2002; Kozics *et al.*, 2013; Chauhan *et al.*, 2014). Phenolic and flavonoid compounds in plants are essential in inhibiting of inflammation, collagen synthesis, as well as angiogenesis (Ambiga *et al.*, 2007; Lodhi *et al.*, 2013). One of the problems in wound healing is high risk of infection (Young and McNaught, 2011). To date *Thymus vulgaris* is used for mastitis, mouth infections and minor researches done on its effect in external wounds (Mohammed and Al-Bayati, 2009).

Considering lower cost, high availability and lower side effects of plants and plant-based chemicals, interests are arising for herbal therapies. Properties of different plants, many essential oils and their constituents have been tested for their promoting impact on wound healing. In spite of all the information available in literature, effect of *Thymus vulgaris* extract on wound healing is not fully studied. Therefore, the aim of current study was to investigate the provoking effects of *Thymus vulgaris* essential oil ointment on wound healing process. For this purpose the tissue fibroblasts, fibrocytes, macrophages distribution, vessel formation, and collagen and epidermis regeneration in rat model were analyzed.

MATERIAL AND METHODS

Plant Collection and Preparation

Fresh thyme (*Thymus vulgaris* L.) leaves were collected in Hamadan province, Iran. The plant was identified in department of Botany Sciences, Herb Garden Avicenna, Hamadan, Iran. Plant areal parts (flowers and leaves, 450 g) were dried and cleaned naturally on laboratory benches at room temperature (23-24°C) for 10 days until they were crisped and powdered by using an electric blender. Then, hydro

Research Article

distillation via cleverger type apparatus was performed to obtain essential oil from thyme leaves (Pietrella et al., 2011).

Experimental Animals

To assume wound healing property of *Thymus vulgaris* ointment, Forty eight male Wistar rats (9 weeks old, 200-210g weight) were used in this study. To adapt rats in new experiment condition, they were kept 5 days prior the study in a standard laboratory condition.

All animals kept in temperature of $22 \pm 3^{\circ}\text{C}$, $60 \pm 5\%$ humidity and a 12h light/dark cycle start at 9 A.M. During the study rats had ad libitum chew pellets and fresh water. All experiments were carried out based on the guidelines of the Ethics Committee of the International Association for the Study of pain (Zimmermann, 1983) and current Iranian law for laboratory animal care. All experiments approved by ethic research committee of Tehran Azad University.

Experiential Ointment Preparation

In this study 3 topical ointments were prepared. Control ointment was base formulation comprising Eucerin (25%) and Vaseline (75%).

Two various *Thymus vulgaris* topical ointments (TVO) were prepared. Ointment 1 was contained 1.5 g of *Thymus vulgaris* essential oil in base formulation . Ointment 2 was contained 3 g of *Thymus vulgaris* essential oil in base formulation (Sasidharan et al., 2010).

Skin Irritation Test

The ointment was evaluated for primary skin irritation test on shaved back of the rats for any abnormality of ointment (Laila et al., 2011).

Excision Wound Model

In this study, animals were starved for 12 hours prior to wounding. All animals anesthetized by intraperitoneal (i.p.) injection of ketamine 5%, 90mg/kg (Ketaset 5%; Alfasan, Woerden, Netherlands) and xylazine hydrochloride 2%, 5mg/kg (Rompun 2%, Bayer, Leverkusen, Germany).

The fur was aseptically and predetermined area marked on the back of animals. Rats were fixed on the surgery table in ventral posture. Two circular wounds each about 200 mm^2 were made on the back of each rat (Morton and Malone, 1972).

Thymus vulgaris topical ointments applied for evaluating its impact on wound healing (Shanbhag et al., 2006). Rats were kept individually under hygienic and controlled conditions in polypropylene cages with stainless steel top.

The creams were topically applied once a day, starting 24 hours post-operation, on the wound area until wound completely healed. All rats were monitored for any wound fluid or other abnormalities (Sasidharan et al., 2010).

Wound Healing Activity

Wound contraction percentage and wound closure time were used to assess wound-healing property. A graph paper and permanent marker were used to measure size. The wound size was computed on days 4, 12 and 21 post-operation (Farahpour and Habibi, 2012).

Percent wound contraction was calculated from the days of measurement of wound areas. The wound healing percentage was calculated by the Walker formula (Walker and Mason, 1968).

Percentage of wound size = $\frac{\text{Wound area on day X}}{\text{Wound area on day zero}} \times 100$

Percentage of wound healing = $100 - \text{Percentage of wound size}$

Histological Analysis

Specimens from skin were taken on days 3, 7, 14 and 21 after wound infection. Tissue samples were excised and fixed in neutral-buffered formalin 10%. Then the sample tissues were processed routinely.

Research Article

sections were microscopically evaluated to assess the predominant stage of wound healing include fibroblast, neovascularization, immune cells distribution and macrophages (Sasidharan *et al.*, 2010).

Statistical Analysis

Data analyzed by two-way analysis of variance (ANOVA) using SPSS 22 (SPSS, Inc., Chicago, IL, USA). Result presented as mean \pm SEM.

For treatment showing a main effect by ANOVA, means have compared by Dunnett's test. $P < 0.05$ were considered as significant differences between treatments.

RESULTS AND DISCUSSION

Result

Wound Contraction

Effect of the *Thymus vulgaris* essential oil ointment on wound excision area is presented in table 1.

As seen, wound area significantly decreased in TC-treated animals (1.5 and 3% Thym oil) compared to other groups on days 4, 12 and 21 post operation ($P < 0.05$).

The wound closure was completed in TVO-treated groups compared to control animals (7 ± 2.31 mm) on day 20.

Table 1: Effect of the *Thymus vulgaris* essential oil ointment (TVO) on wound excision area (mm²)

DAY	Wound area (mm ²) \pm SEM		
	Control	1.5% TVO-treated animals	3% TVO-treated animals
4	168 \pm 7.34 ^a	144 \pm 7.36 ^b	136 \pm 3.29 ^b
12	95 \pm 2.56 ^a	20 \pm 1.36 ^b	30 \pm 3.90 ^b
21	7 \pm 2.31 ^a	0 \pm 0.00 ^b	0 \pm 0.00 ^b

n = 6 animals in each group. Values are presented in mean \pm SEM. There are significant differences between groups with different codes in a the same rows (superscript letters a and b; $P < 0.05$).

Histologic Analysis

The number of fibroblast and macrophages was increased as well as vessel formation compared to control group on days 3, 7, 14 and 21 after incision ($P < 0.05$).

Also there was significant difference for fibroblasts and macrophages distribution between 1.5-and-3% treated groups ($P < 0.05$).

In treated groups, the collagen bundles were well organized between vessels compared to control group on day 7 ($P < 0.05$).

Mature collagen bonds formation and angiogenesis significantly increased in 3% treated group on day 14 post wound induction ($P < 0.05$) (Figure 1).

Research Article

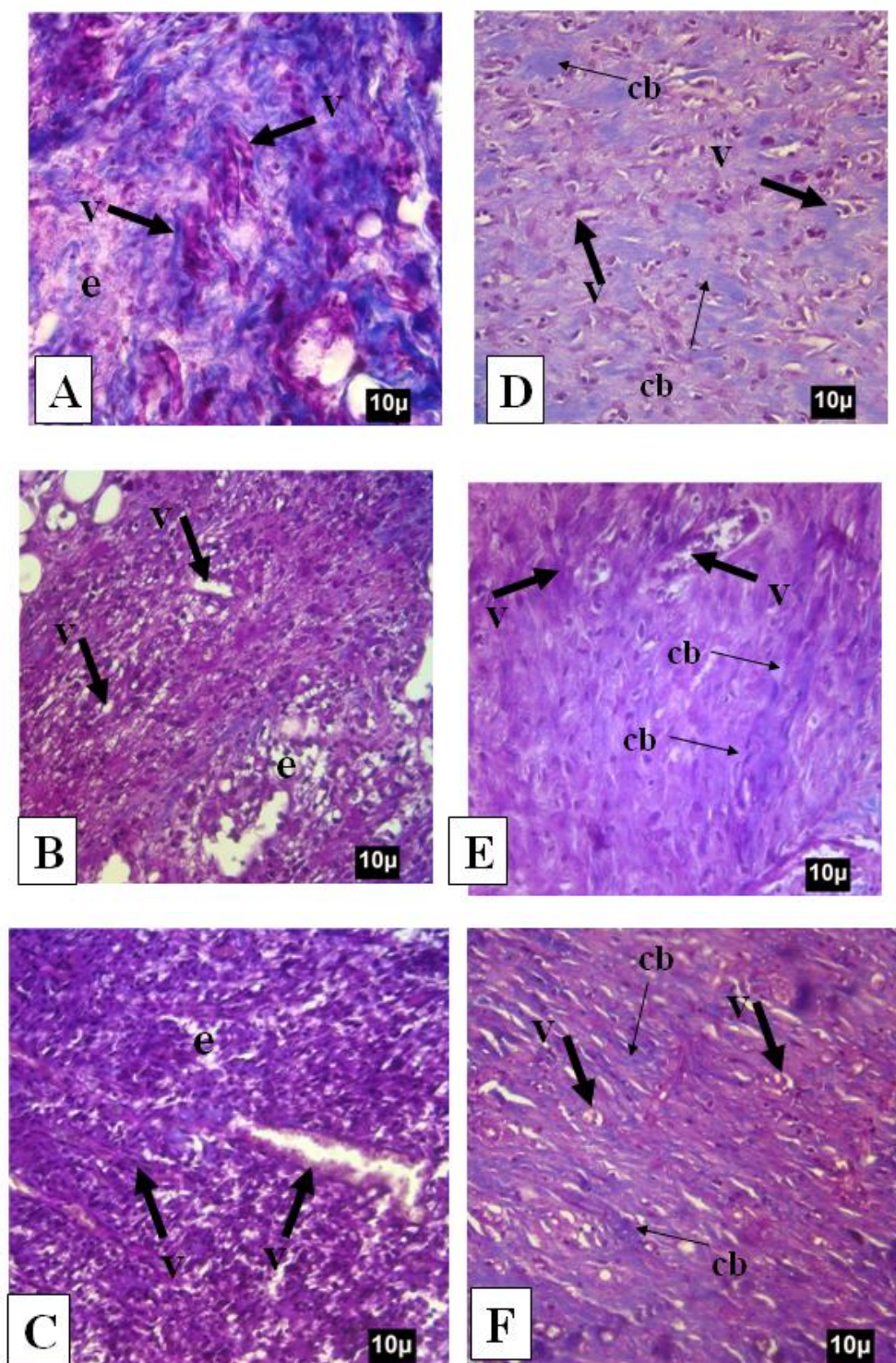


Figure 1: Cross section from wound area on Control, 1.5% and 3% TVO-treated groups for collagen deposition and angiogenesis; A, B, and C represent 7-day-old and D, E and F represent 14-day-old wounds. Eedema and thin walled vasculatures in control group is notable, which is remarkably inhibited in treated groups on day 7 after wound induction. The mature collagen bonds are organized in 1.5% and 3% thyme treated groups on 14 days after wound induction. e: edema, V: vessels, cb: collagen bundles. Masson-trichrome staining, 400×

Research Article

Discussion

The present investigation illustrated the wound healing properties of *Thymus vulgaris* essential oil ointment in rat. To our knowledge few studies done to determine effect of *Thymus vulgaris* essential oil ointment on wound healing. Because of side effects and high cost of synthetic medicine, recently there is growing interest in the search for new nature wound healing drugs. Our data showed that, the TVO improved wound contraction and is useful for wound healing.

In this study, different levels of TVO diminished post-operative wound area. Based on previous reports on physiological mechanism(s) for contraction and regeneration of wound area, the accepted pathway among the forerunners of this field is that contraction initiates by the activation of receptor linked and voltage-dependent Ca^{2+} channels or cyclic AMP phosphodiesterase (CAMP) and therefore promotes Ca^{2+} channels or CAMP activity which leads to contract wound area. (Derakhshanfar *et al.*, 2010). Even though *Thymus vulgaris* widely studied than other Thyme species (Lamiaceae family), but pharmacological and mechanisms action of *Thymus vulgaris* essential oil is not quite elicited (Derakhshanfar *et al.*, 2011; de Lira Mota *et al.*, 2012). To our knowledge presumably TVO impress its effect through this mechanism or may other mechanism(s) include. Competence studies need to determine direct molecular mechanism pathway(s) to how *Thymus vulgaris* essential oil promotes tissue contraction in wound area.

Wound healing is a dynamic cellular and physiological process which is mainly depends on rapid reformation of damaged tissue into normal condition. In this regard, down-regulation of inflammation associated with provoked angiogenesis, even in early stages, promotes proliferative machinery such as fibroblasts, fibrocytes physiologic and/or compensatory functions (Kumar *et al.*, 2006).

Macrophages are the main cells in the inflammatory phase of wound healing (Beldon, 2010; Brancato and Albina, 2011). As seen in figure 1, TVO increased number of macrophages and up regulated fibroblasts accumulation in wound area. In fact, the macrophages attack to the wound area to phagocyte invested pathogens and release growth factors as well as cytokines. This leads to precipitate healing phase by migration of fibroblasts and myofibroblasts as well as promoting collagen synthesis in the wound area (Singer and Clark, 1999).

Histological studies showed that, TVO (1.5 and 3%) significantly increased fibroblast and fibrocytes distribution in wound area. Our data showed that mean distribution of mast cells increased in TVO-treated animals where indicating the *Thymus vulgaris* role in elevating mast cells proliferation. Thus, we can come close to this fact that TVO by stimulating the mast cells proliferation and distribution up-regulated the neovascularization and in turn promoted the proliferation and maturation stages.

Moreover, mast cells are known for secreting vascular growth factor (VGF) that stimulates endothelial cell proliferation where finally up-regulates the neovascularization in wound area (Younan *et al.*, 2011). Neovascularization is known as a defensive and physiologic structural procedure which leads to reducing free radicals as well as releasing the metabolites to the cells involving in the healing process (Stavrou, 2008). Moreover, the neovascularization is an necessary factor for migration of epithelial cells from adjacent regions into the central area of the wound area (Adam *et al.*, 1999). Our results manifested that, there was significant improvement on vessel formation in TVO-treated groups. In correlation, the macrophages increase angiogenesis and endothelial cell proliferation by releasing several growth factors (Beldon, 2010). Proliferation and migration of the epithelial cells and fibroblasts as well as suppressed inflammation, enhances new vessel formation in wound area (Oryan *et al.*, 2010).

With angiogenesis, collagen bundles are organized between vessels in 1.5% TVO-treated group. It is principal to consider that mast cells secrete tryptase and chymase which tryptase also eliminated the ability of mast cells to stimulate fibroblast contraction. It is proposed that tryptase secreted by the mast cells may be one of the active mast cell mediators for fibroblast proliferation and promote collagen synthesis (Kumar *et al.*, 2006). Increased viability of epithelial cells plus their successful proliferation and migration from wound bed leads to well-formed epithelialization (Kokh and DiPietro, 2011). High rate re-epithelialization was considered as an indicator for best healing. Therefore, shortened epithelialization time in 3% TVO-treated animals showed its usefulness on epithelial cells proliferation. Whatever, surveillance

Research Article

of epithelial cells in TVO-treated groups might be because of TVO antioxidant property which prevents cellular damage due to oxidative stress and facilitates the migration process (Panchatcharam *et al.*, 2006). There is a relation between total phenolic and antioxidant activity which high phenolic component ratio of extract is an indicator for better antioxidant activity (Zyad *et al.*, 2007). The antioxidant activities of thymol and carvacrol have been previously reported using different testing systems (Altioik, 2010). Recent researches have shown that phytochemicals such as flavonoids and triterpenoids are able to promote the wound-healing process against methicillin-resistant *S. aureus* (Tsuchiya *et al.*, 1996). In differentiation, *Thymus vulgaris* has anti-oxidant activity which prevents lipid peroxidation followed by atherosclerosis (Kaya *et al.*, 2013). Proliferation and migration of the epithelial cells and fibroblasts as well as restrained inflammation, improve new vessel formation in the wound area (Oryan *et al.*, 2010).

It seems TVO on one hand regulates fibroblast proliferation and on the other hand increases collagen synthesis which terminates to significant wound improvement. Considering these two findings, we conclude that TVO increased fibroblast proliferation and collagen synthesis which finally shortened the wound area.

In conclusion, according to the results of the present study, topical administration of *Thymus vulgaris* essential oil decreased inflammatory cells and afterward increased fibroblast migration and wound contraction. However, a delayed inflammatory phase during the healing process increases abnormal cellularity in the proliferation phase.

Thymol and carvacrol work as antioxidants, antimicrobial and antifungal agents. So, based on findings of the current study we think the wound healing properties of *Thymus vulgaris* were not related only to the antioxidant activity and its effect by all mechanisms. We think further studies are needed to clarify pharmacological properties and physiological mechanisms by those phenolic compounds in *Thymus vulgaris* essential oil ointment. Additionally, suitability studies are needed to distinguish its potential for clinical use in clinical trials.

REFERENCES

- Adam J, Singer MD, Richard AF and Ckark MD (1999). Cutaneous Wound Healing. *The New England Journal of Medicine* **341** 738-746.
- Altioik D, Altioik E and Tihminlioglu F (2010). Physical, antibacterial and antioxidant properties of chitosan films incorporated with thyme oil for potential wound healing applications. *Journal of Materials Science: Materials in Medicine* **21**(7) 2227-2236.
- Ambiga S, Narayanan R, Gowri D, Sukumar D and Madhavan S (2007). Evaluation of wound healing activity of flavonoids from *Ipomoea carnea* Jacq. *Ancient Science of Life* **26**(3) 45.
- Arzani H and Motamedi A (2013). Chemical Compounds of Thyme as a Medicinal Herb in the Mountainous Areas of Iran. *Journal of Nutritional Disorders & Therapy* **12** 2161-0509.
- Beldon P (2010). Basic Science of wound healing. *Surgery* **28** 409-2.
- Bozin B, Mimica-Dukic N, Simin N and Anackov G (2006). Characterization of the volatile composition of essential oils of some Lamiaceae spices and the antimicrobial and antioxidant activities of the entire oils. *Journal of Agricultural and Food Chemistry* **54**(5) 1822-1828.
- Brancato SK and Albina JE (2011). Wound macrophages as key regulators of repair: origin, phenotype, and function. *American Journal of Pathology* **178**(1) 19-25.
- de Lira Mota KS, de Oliveira Pereira F, de Oliveira WA, Lima IO, de Oliveira, Derakhshanfar A, Oloumi MM and Mirzaie M (2010). Study on the effect of *Peganum harmala* extract on experimental skin wound healing in rat: pathological and biomechanical findings. *Comparative Clinical Pathology* **19**(2) 169-172.
- Farahpour MR and Habibi M (2012). Evaluation of the wound healing activity of an ethanolic extract of Ceylon cinnamon in mice. *Veterinary Medicine* **57**(1) 53-57.
- Kaya H, Gokdemir MT, Sogit O, Demir T and Kokcarslan S (2013). Effects of folk medicinal plant extract ankaferd blood stopper on burn wound healing. *Acta Medica Mediterranea* **29** 497-502.
- Kokh TJ and DiPietro LA (2011). Inflammation and wound healing; the role of macrophages. *Expert Reviews in Molecular Medicine* **11** 13-23.

Research Article

- Kozics K, Klusová V, Srančíková A, Mučaji P, Slameňová D, Hunáková E and Horváthová E (2013).** Effects of *Salvia officinalis* and *Thymus vulgaris* on oxidant-induced DNA damage and antioxidant status in HepG2 cells. *Food Chemistry* **141**(3) 2198-2206.
- Kumar R, Katoch SS and Sharma S (2006).** Beta-adrenoceptor agonist treatment reverses denervation atrophy with augmentation of collagen proliferation in denervated mice gastrocnemius muscle. *Indian Journal of Experimental Biology* **44**(5) 371.
- Laila L, Febriyenti F, Salhimi SM and Baie S (2011).** Wound healing effect of Haruan (*Channa striatus*) spray. *International Wound Journal* **8**(5) 484-491.
- Lima AF, Costa LB, Silva JLD, Maia MBS and Ximenes ECPA (2011).** Interventions for wound healing among diabetic patients infected with *Staphylococcus aureus*: a systematic review. *Sao Paulo Medical Journal* **129**(3) 165-170.
- Lodhi S and Singhai AK (2013).** Wound healing effect of flavonoid rich fraction and luteolin isolated from *Martynia annua* Linn. on streptozotocin induced diabetic rats. *Asian Pacific Journal of Tropical Biomedicine* **6**(4) 253-259.
- Mohammed MJ and Al-Bayati FA (2009).** Isolation and identification of antibacterial compounds from *Thymus kotschyanus* aerial parts and *Dianthus caryophyllus* flower buds. *Phytomedicine* **16**(6) 632-637.
- Morton JJ and Malone MH (1972).** Evaluation of Vulneray activity by an open wound procedures in rats. *Archives internationales de pharmacodynamie et de thérapie* 117-126.
- Oryan A, Naeini AT, Nikahval B and Gorjian E (2010).** Effect of aqueous extract of *Aloe vera* on experimental cutaneous wound healing in rat. *Veterinarski Arhiv* **80**(4) 509-522.
- Panchatcharam M, Miriyala S, Gayathri VS and Suguna L (2006).** Curcumin improves wound healing by modulating collagen and decreasing reactive oxygen species. *Molecular and Cellular Biochemistry* **290**(1-2) 87-96.
- Pietrella D, Angiolella L, Vavala E, Rachini A, Mondello F, Ragno R and Vecchiarelli A (2011).** Beneficial effect of *Mentha suaveolens* essential oil in the treatment of vaginal candidiasis assessed by real-time monitoring of infection. *BMC Complementary and Alternative Medicine* **11**(1) 18.
- Sasidharan S, Nilawaty R, Xavier R, Latha LY and Amala R (2010).** Wound healing potential of *Elaeis guineensis* Jacq leaves in an infected albino rat model. *Molecules* **15**(5) 3186-3199.
- Shanbhag TV, Sharma C, Adiga S, Bairy LK, Shenoy S and Shenoy G (2006).** Wound healing activity of alcoholic extract of *Kaempferia galangal* in winster rats. *Indian Journal of Physiology and Pharmacology* **50**(4) 384-390.
- Singer AJ and Clark R (1999).** Cutaneous wound healing. *New England Journal of Medicine* **341** 738-6.
- Stahl-Biskup E and Sáez F (2003).** *Thyme: the Genus Thymus* (CRC Press).
- Stavrou D (2008).** Neovascularization in wound healing. *Journal of Wound Care* **17**(7) 298-300.
- Tsuchiya H, Sato M, Miyazaki T, Fujiwara S, Tanigaki S, Ohyama M and Iinuma M (1996).** Comparative study on the antibacterial activity of phytochemical flavanones against methicillin-resistant *Staphylococcus aureus*. *Journal of Ethnopharmacology* **50**(1) 27-34.
- Walker HL and Mason Jr. AD (1968).** A standard animal burn. *Journal of Trauma* **8**(6) 1049-51.
- Younan GJ, Heit YI, Dastouri P, Kekhia H, Xing W, Gurish MF and Orgill DP (2011).** Mast cells are required in the proliferation and remodeling phases of microdeformational wound therapy. *Plastic and Reconstructive Surgery* **128**(6) 649e-658e.
- Young A and McNaught CE (2011).** The physiology of wound healing. *Surgery* (Oxford). **29**(10) 475-479.
- Zimmermann M (1983).** Ethical guidelines for investigations of experimental pain in conscious animals. *Pain* **16**(2) 109-10.